


ESSO Course on Electrochemotherapy of Cutaneous and Deep Seated Tumours



In partnership with Institute of Oncology Ljubljana and University Medical Center Ljubljana

22-23 October 2018

LJUBLJANA (SI)



Organized by: European Society of Surgical Oncology (Brussels, Belgium) in partnership with Institute of Oncology Ljubljana (Ljubljana, Slovenia) and University Medical Center (Ljubljana, Slovenia)

Chairs of the course: Ibrahim Edhemovic, Institute of Oncology Ljubljana, Ljubljana, Slovenia
Gregor Sersa, Institute of Oncology Ljubljana, Ljubljana, Slovenia

Faculty members: Giulia Bertino, Policlinico San Matteo Pavia Fondazione IRCCS, Pavia, Italy
Nina Boc, Institute of Oncology Ljubljana, Ljubljana, Slovenia
Erik Breclj, Institute of Oncology Ljubljana, Ljubljana, Slovenia
Luca Campana, Veneto Institute of Oncology IRCCS and University of Padova, Padova, Italy
Maja Cemazar, Institute of Oncology Ljubljana, Ljubljana, Slovenia
Mihajlo Djokic, University Clinical Center Ljubljana, Ljubljana, Slovenia
Julie Gehl, University of Copenhagen, Copenhagen, Denmark
Ales Groselj, University Clinical Center Ljubljana, Ljubljana, Slovenia
Bor Kos, Faculty of Electrical Engineering, University of Ljubljana, Ljubljana, Slovenia
Damijan Miklavcic, Faculty of Electrical Engineering, University of Ljubljana, Ljubljana, Slovenia
Marko Snoj, Institute of Oncology Ljubljana, Ljubljana, Slovenia
Blaz Trotovsek, University Clinical Center Ljubljana, Ljubljana, Slovenia

BOOK OF ABSTRACTS

ESSO Course on Electrochemotherapy of Cutaneous and Deep Seated Tumors

Editors: Gregor Sersa, Ibrahim Edhemovic, Simona Kranjc Brezar, Masa Bosnjak, Ursa Lampreht Tratar

Reviewed by: Eldar M. Gadzijev

Technical Editor: Simona Kranjc Brezar

Design: Simona Kranjc Brezar

Printed by: Fota-Cop d.o.o., Ljubljana, Slovenia

Issued by: Institute of Oncology Ljubljana, Ljubljana, Slovenia

Edition: 1st edition, 80 copies, free copy

Web page: <https://www.essoweb.org/>



CIP - Kataložni zapis o publikaciji
Narodna in univerzitetna knjižnica, Ljubljana
616-006-085.84:615.277.3(082)
ESSO Course on Electrochemotherapy of Cutaneous and Deep Seated Tumors (2018 ; Ljubljana)

Book of abstracts / ESSO Course on Electrochemotherapy of Cutaneous and Deep Seated Tumors, 22-23 October 2018 ; organized by European Society of Surgical Oncology (Brussels, Belgium) in partnership with Institute of Oncology Ljubljana (Ljubljana, Slovenia) and University Medical Center (Ljubljana, Slovenia) ; [editors Gregor Sersa ... *et al.*]. - 1st ed. - Ljubljana : Institute of Oncology, 2018

ISBN 978-961-7029-09-3

1. Serša, Gregor 2. European Society of Surgical Oncology 3. Onkološki inštitut (Ljubljana)
4. Univerzitetni klinični center Ljubljana
296993792

Book of Abstracts

ESSO Course on Electrochemotherapy of Cutaneous and Deep Seated Tumors

22-23 October 2018

Ljubljana, Slovenia

Organized by European Society of Surgical Oncology (Brussels, Belgium) in partnership with Institute of Oncology Ljubljana (Ljubljana, Slovenia) and University Medical Center Ljubljana (Ljubljana, Slovenia)

***Chairs of the course:** Ibrahim Edhemovic, Institute of Oncology Ljubljana (Ljubljana, Slovenia) & Gregor Sersa, Institute of Oncology Ljubljana (Ljubljana, Slovenia)*



TABLE OF CONTENTS

Program 4

List of Lectures 7

Lectures 8

Author Index 40

PROGRAM

Monday 22nd October

- 9:00 - 9:10** **Welcome**
- Theoretical Backgrounds***
- 09:10 - 9:30** **Principles of electric field application in electrochemotherapy**
Damijan Miklavcic (Ljubljana, Slovenia)
- 09:30 - 9:50** **Basics and mechanisms of electrochemotherapy**
Maja Cemazar & Gregor Sersa (Ljubljana, Slovenia)
- 09:50 - 10:10** **Overview of clinical applications in cutaneous tumors**
Marko Snoj (Ljubljana, Slovenia)
- 10:10 - 10:30** **Coffee Break**
- 10:30 - 10:50** **How to treat cutaneous tumors, new SOP and side effects**
Julie Gehl (Copenhagen, Denmark)
- 10:50 - 11:10** **Pharmacology of bleomycin, implications in lowering the dose**
Ales Groselj (Ljubljana, Slovenia)
- 11:10 - 11:30** **Electrochemotherapy of melanoma metastases**
Luca Campana (Padova, Italy)
- 11:30 - 11:50** **Electrochemotherapy of head and neck cancer**
Giulia Bertino (Pavia, Italy)
- 11:50 - 13:00** **Lunch**
- Live Sessions***
- 13:00 - 16:00** **Treatment of skin head and neck tumors**
Ales Groselj & Marko Snoj (Ljubljana, Slovenia)
- Case discussion session***
- 16:00 - 18:00** **Skin tumors**
Moderators: Julie Gehl (Copenhagen, Denmark), Luca Campana (Padova, Italy), Giulia Bertino (Pavia, Italy), Ales Groselj (Ljubljana, Slovenia), Marko Snoj (Ljubljana, Slovenia)
- Social Dinner***

PROGRAM

Tuesday 23rd October

Theoretical Backgrounds

- 9:00 - 9:20 **Overview of ECT application in deep seated tumors**
Ibrahim Edhemovic (Ljubljana, Slovenia)
- 09:20 - 9:40 **Treatment planning**
Bor Kos (Ljubljana, Slovenia)
- 09:40 - 10:00 **Treatment verification**
Nina Boc (Ljubljana, Slovenia)
- 10:00 - 10:20 **Experience in treatment of colorectal liver metastases**
Ibrahim Edhemovic & Erik Brecelj (Ljubljana, Slovenia)
- 10:20 - 10:40 **Experience in treatment of hepatocellular carcinoma**
Blaz Trotovsek & Mihajlo Djokic (Ljubljana, Slovenia)
- 10:40 - 11:10 **Coffee break**

Live Sessions

- 11:10 - 14:00 **Treatment of liver tumors**
Ibrahim Edhemovic (Ljubljana, Slovenia), Erik Brecelj (Ljubljana, Slovenia), Blaz Trotovsek (Ljubljana, Slovenia), Mihajlo Djokic (Ljubljana, Slovenia)

Case Discussion Session

- 14:00 - 15:00 **Liver tumors**
Moderators: Ibrahim Edhemovic (Ljubljana, Slovenia), Erik Brecelj (Ljubljana, Slovenia), Blaz Trotovsek (Ljubljana, Slovenia), Mihajlo Djokic (Ljubljana, Slovenia)

- 15:00 - 15:15 **End of the course - Concluding remarks**

Departure

LIST OF LECTURES

1	Principles of electric field application in electrochemotherapy <i>Damijan Miklavcic (Ljubljana, Slovenia)</i>	8
2	Basics and mechanisms of electrochemotherapy <i>Maja Cemazar, Gregor Sersa (Ljubljana, Slovenia)</i>	10
3	Overview of clinical applications in cutaneous tumors <i>Marko Snoj (Ljubljana, Slovenia)</i>	18
4	How to treat cutaneous tumors, new SOP and side effects <i>Julie Gehl (Copenhagen, Denmark)</i>	19
5	Pharmacology of bleomycin, implications in lowering the dose <i>Ales Groselj (Ljubljana, Slovenia)</i>	21
6	Electrochemotherapy of melanoma metastases <i>Luca Campana (Padova, Italy)</i>	22
7	Electrochemotherapy of head and neck cancer <i>Giulia Bertino (Pavia, Italy)</i>	23
8	Overview of ECT application in deep seated tumors <i>Ibrahim Edhemovic (Ljubljana, Slovenia)</i>	28
9	Treatment planning for electroporation-based therapies <i>Bor Kos (Ljubljana, Slovenia)</i>	29
10	Treatment verification <i>Nina Boc (Ljubljana, Slovenia)</i>	30
11	Experience in treatment of colorectal liver metastases <i>Erik Brecelj, Ibrahim Edhemovic (Ljubljana, Slovenia)</i>	32
12	Experience in treatment of hepatocellular carcinoma <i>Blaz Trotovsek, Mihajlo Djokic (Ljubljana, Slovenia)</i>	33

PRINCIPLES OF ELECTRIC FIELD APPLICATION IN ELECTROCHEMOTHERAPY

Damijan Miklavcic

University of Ljubljana, Faculty of Electrical Engineering, Trzaska cesta 25, SI-1000 Ljubljana, Slovenia

E-mail: damijan.miklavcic@fe.uni-lj.si

Electrochemotherapy is a combined treatment using electroporation to enhance transmembrane transport of cytotoxic drugs, which have intracellular target, and for which plasma membrane represents a barrier. It is therefore important that two conditions be met: i) the drug is present in the tumor in sufficient concentration, and ii) the whole tumor mass is exposed to sufficiently high electric field (1, 2). The drug is injected either systemically, e.g. intravenously or intratumorally, while the exposure of cells in the tumor to electric is achieved by delivering electric pulses by selecting adequate electrodes and positioning them correctly with respect to the tumor (2, 3).

The membrane of the cell when exposed to sufficiently high electric field will undergo electroporation that will transiently increase its permeability thus allowing increased inflow of molecules that otherwise lack or have hindered transmembrane transport (4). Electric field distribution depends on the geometry and position of the electrodes relative to the tumor (5, 6). For treating metastasis/tumors in the skin selecting appropriate choice of the electrode and placing it seem not to be difficult (1), however when treating deep seated tumors and/or large tumors pretreatment planning (similar to radiotherapy) and image guidance assistance is necessary (7-8). Validated numerical models are essential in achieving best results with electrochemotherapy and developing new approaches (9).

Acknowledgements

This work was in part supported by Slovenian Research agency and

conducted in the scope of LEA EBAM.

References

1. Miklavčič D, Čorovič S, Pucihar G, Pavšelj N. Importance of tumour coverage by sufficiently high local electric field for effective electrochemotherapy. *Eur J Cancer* 2006;Suppl 4: 45-51.
2. Miklavčič D, Mali B, Kos B, Heller R, Serša G. Electrochemotherapy: from the drawing board into medical practice. *Biomed Eng Online* 2004;13: 29.
3. Miklavčič D, Snoj M, Županič A, Kos B, Čemažar M, Kropivnik M, Bračko M, Pečnik T, Gadžijev E, Serša G. Towards treatment planning and treatment of deep-seated solid tumors by electrochemotherapy. *Biomed Eng Online* 2010;9: 10.
4. Rems L, Miklavčič D. Tutorial: Electroporation of cells in complex materials and tissue. *J Appl Phys* 2016;119: 201101.
5. Kranjc M, Markelc B, Bajd F, Čemažar M, Serša I, Blagus T, Miklavčič D. In situ monitoring of electric field distribution in mouse tumor during electroporation. *Radiology* 2015;274: 115-123.
6. Miklavčič D, Beravs K, Šemrov D, Čemažar M, Demšar F, Serša G. The importance of electric field distribution for effective *in vivo* electroporation of tissues. *Biophys J* 1998;74: 2152-2158.
7. Pavliha D, Kos B, Županič A, Marčan M, Serša G, Miklavčič D. Patient-specific treatment planning of electrochemotherapy: Procedure design and possible pitfalls. *Bioelectrochemistry* 2012;87: 265-273.
8. Marčan M, Pavliha D, Kos B, Forjanič T, Miklavčič D. Web-based tool for visualization of electric field distribution in deep-seated body structures and planning of

electroporation-based treatments. *Biomed Eng Online* 2015;14(Suppl. 3): S4.

9. Cindrič H, Kos B, Tedesco G, Cadossi M, Gasbarrini A, Miklavčič D. Electrochemotherapy of spinal metastases using transpedicular approach – A numerical feasibility study. *Technol Cancer Res Treat* 2018;17: 1-13.

BASIC MECHANISMS OF ELECTROCHEMOTHERAPY

Maja Cemazar and Gregor Sersa

Institute of Oncology Ljubljana, Department of Experimental Oncology, Zaloska cesta 2, SI-1000 Ljubljana, Slovenia

E-mail: mcemazar@onko-i.si; gsertsa@onko-i.si

Abstract: Electrochemotherapy consists of chemotherapy followed by local application of electric pulses to the tumor to increase drug delivery into cells in tumors. Drug uptake can be increased by electroporation only for drugs having impeded transport through the plasma membrane. Among many drugs which have been tested so far, only cisplatin and bleomycin have found their way from preclinical testing to clinical trials. *In vitro* studies demonstrated a several-fold increase of their cytotoxicity by electroporation of cells. *In vivo*, electroporation of tumors after local or systemic administration of either of the drugs i.e. electrochemotherapy, proved to be an effective antitumor treatment. Electrochemotherapy studies using either bleomycin or cisplatin in several tumor models elaborated treatment parameters for effective local tumor control. In veterinary medicine, electrochemotherapy proved to be effective in primary tumors in cats, dogs and horses. In clinical studies, electrochemotherapy was performed on accessible tumor nodules of different malignancies in progressive disease. All clinical studies provided evidence that electrochemotherapy is an effective treatment for local tumor control in patients with different types of cancer.

INTRODUCTION

Treatments for cancer may be divided into different categories based on their goals and mode of action. Very often, the different types of treatment are used in combination, either simultaneously or sequentially. In general, cancer treatment includes three major treatment modalities: surgery and radiation, which are local treatment modalities and chemotherapy, which is a systemic treatment modality.

Chemotherapy, a systemic treatment modality for cancer, is effective for drugs which readily cross the plasma membrane and are cytotoxic once they reach their intracellular targets. However, among the chemotherapeutic drugs which are very cytotoxic, there is some having hampered transport through the plasma membrane. These drugs are good candidates for electrochemotherapy. Electrochemotherapy is a local treatment combining chemotherapy and application of electric pulses to the tumor. In electrochemotherapy, the optimal anti-tumor effectiveness is achieved when

electric pulses are given at the time of the highest extracellular concentration of the hydrophilic chemotherapeutic drug, thereby increasing its transport through the plasma membrane towards the intracellular targets (1-4).

PRECLINICAL DATA

In vitro studies

Electroporation proved to be effective in facilitating transport of different molecules across the plasma membrane for different biochemical and pharmacological studies. However, when using chemotherapeutic drugs, this facilitated transport increases intracellular drug accumulation with the aim to increase their cytotoxicity. Since electroporation can facilitate drug transport through the cell membrane only for molecules which are poorly permeant or non-permeant, suitable candidates for electrochemotherapy are limited to those drugs that are hydrophilic and/or lack a transport system in the membrane. Several chemotherapeutic drugs were tested *in vitro* for potential application

in combination with electroporation of cells. Among the tested drugs, only two were identified as potential candidates for electrochemotherapy of cancer patients. The first is bleomycin, which is hydrophilic and has very restricted transport through the cell membrane, but its cytotoxicity can be potentiated up to several 1000 times by electroporation of cells. A few hundred internalized molecules of bleomycin are sufficient to kill the cell. The second is cisplatin, whose transport through the cell membrane is also hampered. Early studies suggested that cisplatin is transported through the plasma membrane mainly by passive diffusion, while recent studies have demonstrated that transporters controlling intracellular copper homeostasis are significantly involved in influx (Ctr1) and efflux (ATP7A and ATP7B) of the cisplatin (5). Electroporation of the plasma membrane enables greater flux and accumulation of the drug in the cells, which results in an increase of cisplatin cytotoxicity by up to 80-fold (1-4). This promising preclinical data obtained *in*

vitro on a number of different cell lines has paved the way for testing these two drugs in electrochemotherapy *in vivo* on different tumor models.

In vivo studies

Bleomycin and cisplatin were tested in an electrochemotherapy protocol in animal models *in vivo* (Figure 1). Extensive studies in different animal models with different types of tumors, either transplantable or spontaneous, were performed. The antitumor effectiveness of electrochemotherapy was demonstrated on tumors in mice, rats, hamsters, cats, dogs, horses and rabbits. Tumors treated by electrochemotherapy were either subcutaneous or located in muscle, brain or liver, being sarcomas, carcinomas, gliomas or malignant melanoma (1-4,6).

In these studies, different factors controlling antitumor effectiveness were determined:

- The drugs can be given by different *routes of administration*, they can be injected either intravenously or intratumorally. The prerequisite is that, at the time of application of electric pulses to the tumor, a sufficient amount of drug is present in the tumor. Therefore, after intravenous drug administration into small laboratory animals (for example 4 mg/kg of cisplatin or 0.5 mg/kg bleomycin), only a few minutes interval is needed to reach the maximal drug concentration in the tumors. After intratumoral administration, this interval is even shorter and the application of electric pulses has to follow the administration of the drug as soon as possible (within a minute) (1-4).
- Good antitumor effectiveness may be achieved by good tissue electroporation. Electroporation of the plasma membrane is obtained if the cell is exposed to a sufficiently high electric field. This depends on the *electric field distribution* in the tissue which is controlled by the electrode geometry

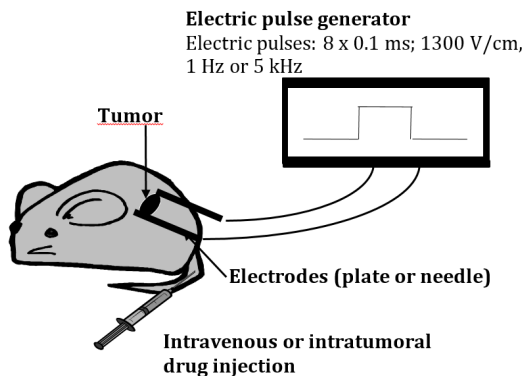


Figure 1. Protocol of electrochemotherapy of experimental tumors presented schematically. The drug is injected either intravenously or intratumorally at doses which do not usually exert an antitumor effect. After an interval which allows sufficient drug accumulation in the tumors, electric pulses are applied to the tumor either by plate or needle electrodes. The electrodes are placed in such a way that the whole tumor is encompassed between the electrodes, providing good electric field distribution in the tumors for optimal electroporation of cells in the tumors.

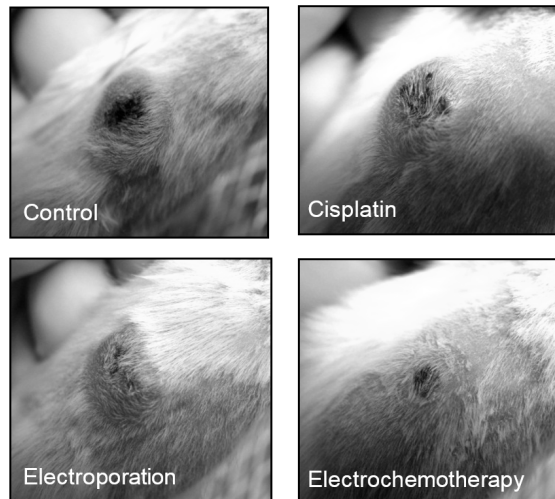


Figure 2. Example of good antitumor effectiveness in SA-1 tumors after electrochemotherapy with cisplatin. Cisplatin was given intravenously (4 mg/kg), 3 min thereafter 8 electric pulses were applied to the tumor with plate electrodes. Electric pulses were applied in two directions; 4 pulses in one and the other 4 in the perpendicular direction. Eight days after the treatment good antitumor effectiveness of electrochemotherapy with cisplatin is evident, compared to the single treatments with cisplatin or electric pulses.

and tissue composition. The electric field distribution in the tissue and cell electroporation can be improved by rotating the electric field. Surface tumours can be effectively treated by plate electrodes, whereas appropriate electric field distribution in the deeper parts of the tumour is assured by using needle electrodes (7-9).

- The antitumor effectiveness depends on the *amplitude, number, frequency and duration of the electric pulses applied*. Several studies in which parallel plate electrodes were used for surface tumors showed that amplitude over distance ratio above 1000 V/cm is needed for tumor electroporation, and that above 1500 V/cm, irreversible changes in the normal tissues adjacent to the tumor occur. So, the window for effective and safe electrochemotherapy is between 1000-1500 V/cm. In most studies, the amplitude over distance ratio of 1300 V/cm induced good antitumor effectiveness without sub-optimal electroporation of the tissue or

damage to the tissue due to irreversible cell permeabilisation (8). For other types of electrodes, the electric field distribution and thus, also the necessary amplitude of electric pulses, need to be determined by numerical calculations. *Repetition frequencies* of the pulses for electrochemotherapy are either 1 Hz or 5 kHz with equal effect if the concentration of drug present in the tumor is high enough. The minimal number of pulses used is 4; most studies use 8 electric pulses of 100 μ s (1,4,8,10-12).

All the experiments conducted *in vivo* in animals provided sufficient data to demonstrate that electrochemotherapy with either bleomycin or cisplatin is effective in the treatment of solid tumors, using drug concentrations which have no or minimal antitumor effect without application of electric pulses. A single treatment by electrochemotherapy already induces partial or complete regression of tumors, whereas treatment with bleomycin or cisplatin alone or application of electric pulses alone has no or minimal antitumor effect (Figure 2).

Mechanisms of action

The principal mechanism of electrochemotherapy is electroporation of cells in the tumors, which increases the drug effectiveness by enabling the drug to reach the intracellular target. This was demonstrated in studies which measured the intratumoral drug accumulation and the amount of drug bound to DNA. Basically, the amounts of bleomycin and cisplatin in the electroporated tumours were up to 2-4 fold higher than in those without application of electric pulses (1-4). Besides membrane electroporation, which facilitates drug transport and its accumulation in the cell, other mechanisms that are involved in the antitumor effectiveness of electrochemotherapy were described. The application of electric pulses to tissues induces a transient, but reversible reduction of blood flow (13,14).

Restoration of the blood flow in normal tissue is much faster than that in tumors (14,15). The vascular lock in the tumor induces drug entrapment in the tissue, providing more time for the drug to act.

The cytotoxic effect of electrochemotherapy is not limited only to tumor cells in the tumors. Electrochemotherapy also acts on stromal cells, including endothelial cells in the lining of tumor blood vessels, which undergo cell death (16). Consequently, by vascular-disrupting action of electrochemotherapy, a cascade of tumor cell death occurs due to long-lasting hypoxia in the affected vessels. This represents yet another mechanism involved in the antitumor effectiveness of electrochemotherapy, i.e. a vascular-disrupting effect (17-19). This vascular-disrupting action of electrochemotherapy is important in clinical situations where haemorrhagic tumor nodules need to be treated (20).

A difference in the antitumor effectiveness of electrochemotherapy was observed between immunocompetent and immunodeficient experimental animals, indicating on involvement of the immune response in antitumor effectiveness (21). Due to massive tumor antigen shedding in organisms after electrochemotherapy, systemic immunity can be induced and also up-regulated by additional treatment with biological response modifiers like IL-2, GM-CSF and TNF- α (22-24).

To sum up, the electrochemotherapy protocol was optimized in preclinical studies *in vitro* and *in vivo*, and basic mechanisms were elucidated. In addition to the electroporation of cells, vascular lock leading to drug entrapment in tumors, a vascular-disrupting effect and involvement of the immune response were also demonstrated. Based on all this data, electrochemotherapy with bleomycin and cisplatin was promptly evaluated in clinical trials and is now in routine use in human and veterinary oncology.

PERSPECTIVES

Knowledge about the mechanisms involved in the antitumor effectiveness of electrochemotherapy opened new possibilities for the application of electric pulses or electrochemotherapy in the treatment of cancer.

The chemotherapeutic drugs which increase effectiveness of radiation therapy are radiosensitizing drugs. These include bleomycin and cisplatin. Recently, some new drugs and chemicals were used in combination with electric pulses in preclinical studies, such as Mitomycin C, Ruthenium compounds and Calcium. The results of the studies in mice shown positive effects (25-27). Since drug delivery induced by electroporation is site-specific, it could be used for tumor-specific delivery of radiosensitizing drugs. By increased radiosensitizing drug delivery into tumors and not in the surrounding normal tissue, the therapeutic index of tumor irradiation is increased. In our studies, we combined electrochemotherapy with bleomycin or cisplatin with radiotherapy and demonstrated a good potentiation of the sarcoma tumor radiation response: 1.9-fold for electrochemotherapy with bleomycin and 1.6-fold for electrochemotherapy with cisplatin (28,29). The radiosensitizing effect of electrochemotherapy with cisplatin was also demonstrated in breast cancer and with bleomycin in a fractionated radiation regime which makes this treatment potentially available also in the clinic (30,31).

The application of electric pulses was shown to modulate tumor blood flow. Both reduced blood flow and lowered partial oxygen pressure (pO₂) in the tumors are consequences of the applied electric pulses (32). The reduced pO₂ can activate bioreductive drugs to exhibit a cytotoxic effect on hypoxic cells (33). In well-oxygenated cells, the drug remains inactive. On the other hand, tumor hypoxia induced by application of electric pulses can improve therapeutic conditions for

the use of hyperthermia since tumor cells are more sensitive to heat in sub-optimal physiological conditions (34).

Electrochemotherapy is an effective cytoreductive treatment; however, its curative effect depends on the permeabilisation of possibly all cells in the tumour. Since permeabilisation of every single cell in the tumour is virtually impossible, electrochemotherapy could be combined with other cytoreductive treatments that should have a systemic component. This can be achieved by a combination of electrochemotherapy with electrotransfer of different therapeutic genes acting either locally or sistemically, such as p53, IL-2; GM-CSF or IL-12. The results of the studies demonstrate positive results, further supporting this concept (35-38).

Finally, electrochemotherapy with cisplatin or bleomycin is also successfully used in veterinary medicine. It was used to treat different tumors, such as mammary adenocarcinoma, fibrosarcoma, cutaneous mast cell tumor, hemangioma, hemangiosarcoma, perianal tumors, neurofibroma and sarcoids in dogs, cats, hamsters, rabbits and horses. Recent reports demonstrated successful treatment of different neoplasms in companion animals and sarcoids in horses either of electrochemotherapy alone or in combination with other treatment, mainly surgery (39-47). Hopefully, electrochemotherapy will be broadly used in veterinary medicine for the treatment of different malignancies, both in primary and metastatic disease.

In conclusion, electroporation in electrochemotherapy has already been very well exploited; however, there are new biomedical applications of electroporation in cancer treatment that still need testing and development.

ACKNOWLEDGEMENT

This research was funded by research grants from Slovenian Research Agency

and was conducted in the scope of the EBAM European Associated Laboratory (LEA) and COST Action TD1104.

REFERENCES

1. Sersa G. Electrochemotherapy: animal work review. In: Jaroszeski MJ, Heller R, Gilbert R, editors. Electrochemotherapy, electrogenetherapy, and transdermal drug delivery. Electrically mediated delivery of molecules to cells. Totowa, New Jersey: Humana Press, 2000. p. 119-36.
2. Mir LM. Therapeutic perspectives of *in vivo* cell electropermeabilization. *Bioelectrochem* 2001; 53: 1-10.
3. Gehl J. Electroporation: theory and methods, perspectives for drug delivery, gene therapy and research. *Acta Physiol Scand* 2003; 177: 437-47.
4. Mir LM. Bases and rationale of the electrochemotherapy. *EJC Suppl* 2006; 4: 38-44.
5. Howell SB, Safaei R, Larson CA, Sailor MJ. Copper transporters and the cellular pharmacology of the Platinum-containing cancer drugs. *Mol Pharmacol* 2010; 77:887-94.
6. Agerholm-larsen B, Iversen HK, Ibsen P, Moller JM, Mahmood F, Jansen KS, Gehl J. Preclinical validation of electrochemotherapy as an effective treatment for brain tumors. *Cancer Res* 2011; 71:3753-62.
7. Miklavcic D, Beravs K, Semrov D, Cemazar M, Demsar F, Sersa G. The importance of electric field distribution for effective *in vivo* electroporation of tissues. *Biophys J* 1998; 74: 2152-8.
8. Miklavcic D, Corovic S, Pucihar G, Pavselj N. Importance of tumor coverage by sufficiently high local electric field for effective electrochemotherapy. *EJC Suppl* 2006; 4: 45-51.
9. Corovic S, Al Hakere B, Haddad V, Miklavcic D, Mir LM. Importance of the contact surface between electrodes and treated tissue in electrochemotherapy. *Tech Cancer Res Treat* 2008; 7: 292-99.
10. Sersa G, Miklavcic D, Cemazar M, Rudolf Z,

- Pucihar G, Snoj M. Electrochemotherapy in treatment of tumours. *Eur J Surg Oncol* 2008; 34: 232-40.
11. Miklavcic D, Pucihar G, Pavlovec M, Ribaric S, Mali M, Macek-Lebar A, Petkovsek M, Nastran J, Kranjc S, Cemazar M, Sersa G. The effect of high frequency electric pulses on muscle contractions and antitumor efficiency *in vivo* for a potential use in clinical electrochemotherapy. *Bioelectrochemistry* 2005; 65: 121-8.
 12. Sersa G, Kranjc S, Cemazar M, Scancar J, Krzan M, Neumann E. Comparison of antitumor effectiveness of electrochemotherapy using different electric pulse repetition frequencies. *J membrane biology* 2010; 236: 155-162.
 13. Sersa G, Cemazar M, Parkins CS, Chaplin DJ. Tumour blood flow changes induced by application of electric pulses. *Eur J Cancer* 1999; 35: 672-7.
 14. Bellard E, Markelc B, Pelofy S, Le Guerroué F, Sersa G, Teissié J, Cemazar M, Golzio M. Intravital microscopy at the single vessel level brings new insights of vascular modification mechanisms induced by electropermeabilization. *J Control Release* 2012; 163: 396-403.
 15. Gehl J, Skovsgaard T and Mir LM. Vascular reactions to *in vivo* electroporation: characterization and consequences for drug and gene delivery. *Biochim Biophys Acta* 2002; 1569: 51-8.
 16. Cemazar M, Parkins CS, Holder AL, Chaplin DJ, Tozer GM and Sersa G. Electroporation of human microvascular endothelial cells: evidence for anti-vascular mechanism of electrochemotherapy. *Br J Cancer* 2001; 84: 556-70
 17. Jarm T, Cemazar M, Miklavcic D, Sersa G. Antivascular effects of electrochemotherapy: implications in treatment of bleeding metastases. *Exp Rev Anticancer Ther* 2010; 10: 729-746.
 18. Sersa G, Jarm T, Kotnik T, Coer A, Podkrajsek M, Sentjurc M, Miklavcic D, Kadivec M, Kranjc S, Secerov A, Cemazar M. Vascular disrupting action of electroporation and electrochemotherapy with bleomycin in murine sarcoma. *Brit J Cancer*, 2008, 98: 388-98
 19. Markelc B, Bellard E, Sersa G, Pelofy S, Teissie J, Coer A, Golzio M, Cemazar. *In vivo* molecular imaging and histological analysis of changes induced by electric pulses used for plasmid DNA electrotransfer to the skin: a study in a dorsal window chamber in mice. *J Membrane Biol* 2012; 245: 545-554.
 20. Gehl J, Geertsen PF. Palliation of haemorrhaging and ulcerated cutaneous tumours using electrochemotherapy. *EJC Suppl* 2006; 4: 35-37.
 21. Sersa G, Miklavcic D, Cemazar M, Belehradec JJr, Jarm T, Mir LM. Electrochemotherapy with CDDP on LPB sarcoma: comparison of the anti-tumor effectiveness in immunocompetent and immunodeficient mice. *Bioelectroch Bioener* 1997; 43: 279-283.
 22. Sersa G, Cemazar M, Menart V, Gaberc-Porekar V, Miklavčič D. Antitumor effectiveness of electrochemotherapy is increased by TNF- α on SA-1 tumors in mice. *Cancer Letters* 1997; 116: 85-92.
 23. Mir LM, Roth C, Orłowski S, Quintin-Colona F, Fradelizi D, Belahradec J, Kourilsky P. Systemic antitumor effects of electrochemotherapy combined with histoincompatible cells secreting interleukin 2. *J Immunother* 1995; 17: 30-8.
 24. Heller L, Pottinger C, Jaroszeski MJ, Gilbert R, Heller R. *In vivo* electroporation of plasmids encoding GM-CSF or interleukin-2 into existing B16 melanoma combined with electrochemotherapy inducing long-term antitumour immunity. *Melanoma Res* 2000; 10: 577-83.
 25. Vásquez JL, Gehl J, Hermann GG. Electroporation enhances mitomycin C cytotoxicity on T24 bladder cancer cell line: a potential improvement of intravesical chemotherapy in bladder cancer. *Bioelectrochemistry* 2012; 88:127-33.
 26. Hudej R, Miklavcic D, Cemazar M, Todorovic V, Sersa G, Bergamo A, Sava G, Martincic A, Scancar J, Keppler BK, Turel I. Modulation of Activity of Known Cytotoxic Ruthenium(III) Compound (KP418) with

- Hampered Transmembrane Transport in Electrochemotherapy *In Vitro* and *In Vivo*. *J Membr Biol* 2014. [Epub ahead of print].
27. Frandsen SK, Gissel H, Hojman P, Tramm T, Eriksen J, Gehl J. Direct therapeutic applications of calcium electroporation to effectively induce tumor necrosis. *Cancer Res* 2012 15; 72:1336-41.
 28. Sersa G, Kranjc S, Cemazar M. Improvement of combined modality therapy with cisplatin and radiation using electroporation of tumors. *Int J Radiat Oncol Biol Phys* 2000; 46: 1037-41.
 29. Kranjc S, Grosel A, Cemazar M, Sentjunc M, Sersa G. Improvement of combined modality therapy with bleomycin and radiation using electroporation of LPB sarcoma cells and tumors in mice. *BMC Cancer* 2005; 5: 115.
 30. Raeisi E, Aghamiri SM, Bandi A, Rahmatpour N, Firoozabadi SM, Kafi-Abad SA, Mir LM. The antitumor efficiency of combined electrochemotherapy and a single dose irradiation on a breast cancer tumor model. *Radiol Oncol* 2012; 46: 226-32.
 31. Kranjc S, Tevz G, Kamensek U, Vidic S, Cemazar M, Sersa G. Radiosensitizing effect of electrochemotherapy in a fractionated radiation regime in radiosensitive murine sarcoma and radioresistant adenocarcinoma tumor model. *Radiat Biol* 2009 172:677-85.
 32. Sersa G, Krzic M, Sentjunc M, Ivanusa T, Beravs K, Kotnik V, Coer A, Swartz HM, Cemazar M. Reduced blood flow and oxygenation in SA-1 tumours after electrochemotherapy with cisplatin. *Br J Cancer* 2002; 87:1047-54.
 33. Cemazar M, Parkins CS, Holder AL, Kranjc S, Chaplin DJ and Sersa G. Cytotoxicity of bioreductive drug tirapazamine is increased by application of electric pulses in SA-1 tumours in mice. *Anticancer Res* 2001; 21: 1151-1156.
 34. Karner KB, Lesnicar H, Cemazar M, Sersa G. Antitumour effectiveness of hyperthermia is potentiated by local application of electric pulses to LPB tumours in mice. *Anticancer Res* 2004; 24: 2343-8.
 35. Heller L, Pottinger C, Jaroszeski MJ, Gilbert R, Heller R. *In vivo* electroporation of plasmid encoding GM-CSF or interleukin-2 into existing B16 melanomas combined with electrochemotherapy induces long-term antitumour immunity. *Melanoma Res* 2000; 10: 577-83.
 36. Matsubara H, Maeda T, Gunji Y, Koide Y, Asano T, Ochiai T, Sakiyama S, Tagawa M. Combinatory anti-tumor effects of electroporation-mediated chemotherapy and wild-type p53 gene transfer to human esophageal cancer cells. *Int J Oncol* 2001; 18: 825-9.
 37. Grosel A, Sersa G, Kranjc S, Cemazar M. Electrogene therapy with p53 of murine sarcomas alone or combined with electrochemotherapy using cisplatin. *DNA Cell Biol* 2006; 25:674-83.
 38. Sedlar A, Dolinsek T, Markelc B, Prosen L, Kranjc S, Bosnjak M, Blagus T, Cemazar M, Sersa G. Potentiation of electrochemotherapy by intramuscular IL-12 gene electrotransfer in murine sarcoma and carcinoma with different immunogenicity. *Radiol Oncol* 2012, 4: 302-11.
 39. Mir LM, Devauchelle P, Quintin_Colonna F, Delisle F, Dolinger S, Fradelizi D, Belehradec JrJ, Orłowski S. First clinical trial of cat soft-tissue carcinomas treatment by electrochemotherapy. *Br J Cancer* 1997; 76: 1617-22.
 40. Tozon N, Sersa G, Cemazar M. Electrochemotherapy: Potentiation of local antitumour effectiveness of cisplatin in dogs and cats. *Anticancer Res* 2001; 21: 2483-6.
 41. Cemazar M, Tamzali Y, Sersa G, Tozon N, Mir LM, Miklavcic D, Lowe R, Teissie T. Electrochemotherapy in veterinary oncology. *J Vet Int Med* 2008; 22: 826-31.
 42. Kodre V, Cemazar M, Pecar J, Sersa G, Cör A, Tozon N. Electrochemotherapy compared to surgery for treatment of canine mast cell tumours. *Anticancer Res* 2009; 23: 55-62.
 43. Pavlin D, Cemazar M, Cör A, Sersa G, Pogacnik A, Tozon N. Electrogene therapy with interleukin-12 in canine mast cell tumors. *Radiol Oncol* 2011; 45: 30-9.
 44. Tamzali Y, Borde L, Rols MP, Golzio M, Lyarzhri F, Teissie J. Successful treatment of equine sarcoids with cisplatin electrochemotherapy:

A retrospective study of 48 cases. *Equine Vet J* 2012; 44: 214-40.

45. Spugnini Ep, Fanciulli M, Citro G, Baldi A. Preclinical models of electrochemotherapy: the role of veterinary patients. *Future Oncol* 2012; 8:829-37.
46. Spugnini EP, Renaud SM, Buglioni S, Carocci F, Dragonetti E, Murace R, Cardelli P, Vincenzi B, Baldi A, Citro G. Electrochemotherapy with cisplatin enhances local control after surgical ablation of fibrosarcoma in cats: an approach to improve the therapeutic index of highly toxic chemotherapy drugs. *J Transl Med* 2011; 9:152.
47. Tozon N, Pavlin D, Sersa G, Dolinsek T, Cemazar M. Electrochemotherapy with intravenous bleomycin injection: an observational study in superficial squamous cell carcinoma in cats. *J Feline Med Surg* 2014; 16: 291-9.

OVERVIEW OF CLINICAL APPLICATIONS IN CUTANEOUS TUMORS

Marko Snoj

Institute of Oncology Ljubljana, Zaloska cesta 2, SI-1000 Ljubljana, Slovenia

E-mail: msnoj@onko-i.si

Cutaneous metastases are fairly frequent manifestation of advanced malignant disease, comprising about 0.7-9% of all cancer patients. The cutaneous metastases may present itself as a isolated disease or may present itself as a part of multiple organ spread. Treatment of cutaneous metastases could reduce or eliminate symptoms and improve quality of life. There are various sorts of local therapies and among them electrochemotherapy is gaining in importance. The first clinical report of electrochemotherapy for cutaneous metastases came in 1991 which reported good clinical results in treatment of head and neck tumors. The cumulative results of all studies till 2006 established that there has been 642 cutaneous melanoma metastases treated with a complete response of 67% and an objective

response of 85%. The results of the first multicentric study were published the same year showing that an objective response in 85% of treated metastases, regardless of tumor histology, drug used or route of drug administration. With this multicenter study the Standard Operating Procedures for electrochemotherapy were established. Today electrochemotherapy is a feasible and desirable treatment option for cutaneous metastases of different malignant histologies. It is more effective in cutaneous metastases smaller than 3 cm. The side effects and adverse events of electrochemotherapy are minimal, with pain being the most frequent. Its advantages over other local treatments are that it can be used in heavily pretreated patients, may be repeated several times and usually does not produce the ulceration of treated lesion.

HOW TO TREAT CUTANEOUS TUMORS, NEW SOP AND SIDE EFFECTS

Julie Gehl

University of Copenhagen, Copenhagen, Denmark

By far the greatest body of evidence available in clinical use of electrochemotherapy stems from the treatment of cutaneous tumors, primarily metastases but also primary tumors. This means that experience is widespread, and data are available. At the same time the experience from treatment of cutaneous tumors may guide the use of electrochemotherapy for tumors in internal organs as well. After initial studies published in the 90'ies using custom-made electrodes, an important pan-European effort led not only to the publication of the ESOPE study (1), but also to manufacturing of equipment for clinical use (generator and electrodes) and to standard operating procedures (2). This was important in allowing electrochemotherapy to become an available treatment in many European countries. Numerous studies have now been published describing treatment results across tumor histologies, or specifically dealing with e.g. breast cancer metastases (3, 4), malignant melanoma metastases (5, 6), basal cell primary carcinomas (7). In 2013 the National Institute for Health and Care Excellence (NICE), UK, described electrochemotherapy as efficient and without major safety concerns (8, 9). At the same time continuous monitoring of side effects and treatment efficacy through databases such as the International Network for Sharing Practices (InspECT) database was encouraged.

Updated standard operating procedures taking into account the first 10 years of experience after the initial publication of Standard Operating Procedures have been published (10). Briefly, cutaneous tumors maybe treated either under local anesthesia (small, few tumors), or under

general anesthesia (many and/or larger tumors), electrochemotherapy may be given as local injection (small, few tumors), or as systemic infusion (many and/or larger tumors). All solid tumor histologies may be treated with electrochemotherapy. Most cases need to be treated only once, and the response rate is high across tumor histologies.

References

1. Marty M, Sersa G, Garbay JR, Gehl J, Collins CG, Snoj M, Billard V, Geertsen PF, Larkin JO, Miklavcic D et al. Electrochemotherapy - An easy, highly effective and safe treatment of cutaneous and subcutaneous metastases: Results of ESOPE (European Standard Operating Procedures of Electrochemotherapy) study. *EJC Suppl* 2006;4(11):3-13.
2. Mir LM, Gehl J, Sersa G, Collins CG, Garbay JR, Billard V, Geertsen PF, Rudolf Z, O'Sullivan GC, Marty M. Standard operating procedures of the electrochemotherapy: Instructions for the use of bleomycin or cisplatin administered either systemically or locally and electric pulses delivered by the CliniporatorTM by means of invasive or non-invasive electrodes. *EJC Suppl* 2006;4(11):14-25.
3. Matthiessen LW, Johannesen HH, Hendel HW, Moss T, Kamby C, Gehl J. Electrochemotherapy for large cutaneous recurrence of breast cancer: A phase II clinical trial. *Acta Oncol* 2012;51(6):713-21.
4. Campana LG, Valpione S, Falci C, Mocellin S, Basso M, Corti L, Balestrieri N, Marchet A, Rossi CR. The activity and safety of electrochemotherapy in persistent chest wall recurrence from breast cancer after mastectomy: a phase-II study. *Breast Cancer Res Treat* 2012;134:1169-78.
5. Kunte C, Letule V, Gehl J, Dahlstroem K,

- Curatolo P, Rotunno R, Muir T, Occhini A, Bertino G, Powell B et al. Electrochemotherapy in the treatment of metastatic malignant melanoma: a prospective cohort study by InspECT. *Br J Dermatol* 2017;176(6):1475-1485.
6. Campana LG, Valpione S, Mocellin S, Sundararajan R, Granziera E, Sartore L, Chiarion-Sileni V, Rossi CR. Electrochemotherapy for disseminated superficial metastases from malignant melanoma. *Br J Surg* 2012;99:821-830.
7. Bertino G, Sersa G, De Terlizzi F, Occhini A, Plaschke CC, Groselj A, Langdon C, Grau JJ, McCaul JA, Heuveling D et al. European Research on Electrochemotherapy in Head and Neck Cancer (EURECA) project: Results of the treatment of skin cancer. *Eur J Cancer* 2016;63:41-52.
8. National Institute for Health and Care Excellence (NICE): Electrochemotherapy for metastases in the skin from tumours of non-skin origin and melanoma. <https://www.nice.org.uk;2013>.
9. National Institute for Health and Care Excellence (NICE): Electrochemotherapy for primary basal cell carcinoma and primary squamous cell carcinoma. www.nice.org.uk;2014.
10. Gehl J, Sersa G, Matthiessen LW, Muir T, Soden D, Occhini A, Quaglino P, Curatolo P, Campana LG, Kunte C et al. Updated standard operating procedures for electrochemotherapy of cutaneous tumours and skin metastases. *Acta Oncol* 2018, 57(7):874-882.

PHARMACOLOGY OF BLEOMYCIN, IMPLICATIONS IN LOWERING THE DOSE

Ales Groselj

University Medical Centre Ljubljana, Department of Otorhinolaryngology and Cervicofacial Surgery, Zaloska cesta 2, SI-1000 Ljubljana, Slovenia

E-mail: ales.groselj@hotmail.com

According to the standard operating procedure for electrochemotherapy (ECT), a bleomycin dose of 15 000 IU/m² body surface area should be injected intravenously and, after an interval of 8 minutes, electric pulses are delivered to the tumor. However, most of the patients treated with electrochemotherapy are older than 65 years, with the age-dependent body changes resulting in a decrease lean body mass and total body water. Consequently, the distribution of water-soluble drugs, such as bleomycin, is reduced and higher plasma or serum levels of the drugs that is more than expected might be achieved.

On the basis of the pharmacokinetics of bleomycin in the elderly patients, which was analyzed by using a newly developed analytical method for determination of bleomycin in serum samples, a lower dose of bleomycin of 10 000 IU/m² was recommended. Recently published clinical studies confirm that ECT performed with reduced dose of bleomycin could be as effective as currently recommended dose. Especially older patients, patients with impaired renal function and candidates for multiple ECT cycles could have the benefit from reduced dose protocol.

Recently, a study on animal models, based on the comparison of the carcinoma and melanoma models, implicate the differences in bleomycin pharmacokinetics in various histological types of malignant tumors as a possible explanation of differences in response rates to ECT. Alterations in bleomycin pharmacokinetics in histologically different tumors could be due to variations in tumor

vascularization, which has an impact on bleomycin accumulation at the time of electroporation. According to these findings, tumor vascularization might be used as a predictive factor for the tumor response to ECT.

ELECTROCHEMOTHERAPY OF MELANOMA METASTASES

Luca Campana

Veneto Institute of Oncology IRCCS and University of Padova, Padova, Italy

Due to its propensity to recur on the skin, melanoma represents a leading indication to electrochemotherapy (ECT). With the advent of targeted and immune therapies, prolonged survival is being achieved and new patterns of disease have emerged. Thus, ECT is increasingly applied not only as a palliative, but also as a complementary therapy, to enhance the care of patients with superficially metastatic melanoma through precise tumor targeting and prolonged locoregional control. Historically, several ECT studies included patients with melanoma, and since 2006 ESOPE guidelines nine case series have been published. Complete response (CR) rate ranged between 20% and 50%. In well-selected cases, ECT allowed to managing metastases in challenging anatomical locations such as the face, oral cavity, and perianal region. Interestingly, ECT can be combined with surgery, with either a neoadjuvant or adjuvant intent, and the 2018 ESOPE guidelines include the option of performing debulking surgery and ECT within the same procedure. Patient-reported outcomes have been previously investigated in 36 patients by means of a dedicated questionnaire. In the short-term, 34 of them reported a positive impact on wound healing, bleeding, aesthetic impairment, activities of daily living, social relations, or pain. These findings have been subsequently confirmed in 211 melanoma patients by the EORTC QLQ-C30 questionnaire. Cutaneous and subcutaneous metastases from melanoma often occur in the setting of metastatic, disseminated disease and are often associated with clinical complications, including bleeding, pain and ulceration, and with resulting quality of life deterioration. Although a locoregional approach for a solitary lesion can be

indicated, the primary aim of treatment in advanced cases is palliative, but can nonetheless include various combination/sequencing of locoregional treatments (surgery, isolated limb perfusion/infusion, radiotherapy, T-VEC oncovirotherapy, ECT), and systemic therapies (immuno-, targeted-therapy).

ELECTROCHEMOTHERAPY OF HEAD AND NECK CANCER

Giulia Bertino

University of Pavia, Department of Otolaryngology Head Neck Cancer, IRCCS Policlinico San Matteo Foundation, P.le Golgi 2, 27100 Pavia - Italy

E-mail: giulia.bertino@tin.it

Abstract: Electrochemotherapy (ECT) of head and neck cancer can be particularly tricky because the Otolaryngologist has to be able to manage many different pathological conditions: small or large cutaneous nodules located on the skin of the upper or lower face; subcutaneous or deep seated tumors in proximity of vital structures and small or large mucosal lesions of the oral cavity or the oropharynx. Each of these situations requires specific treatment modalities ranging from procedures that can be conducted under local anesthesia with the use of the standard fixed-geometry electrodes, to procedures that require general anesthesia, prophylactic tracheotomy and electroporation with the variable geometry.

The success of ECT in the head and neck area is strictly related to the capability of complete electroporation of the tumor nodules. The higher percentages of objective response are obtained in the skin areas, where the possibilities of complete coverage of the tumor mass is easier; while areas that cannot be easily exposed and reached with the electrodes, such as the oropharynx, or deep seated tumors show lower but still encouraging percentages of objective response. The development of new electrodes and the improvement of the procedures will increase the effectiveness of ECT in these peculiar conditions.

CURRENT PERSPECTIVES

Electrochemotherapy (ECT) is currently reserved to the palliative local treatment of cutaneous, subcutaneous or deep seated tumors of any kind of histology nor suitable to for standard treatments, the pain relief of tumor masses or the control of bleeding lesions (1). These pathological conditions can be particularly devastating in the head and neck area, where the standard treatments employed can add disabilities and worsen the residual quality of life in these patients (2).

Previous studies have proven the effectiveness of ECT in melanoma and non-melanoma skin cancers, with percentages of objective response verging 100% in basal cell carcinomas (BCC) and with healing of the treated lesions without damage of the surrounding tissues and minimal or nil impact on the aesthetic and function of the head and neck subsites (3).

The treatment of the oral and oropharyngeal lesions is more complex and depends on the capability to cover with the electric field

all the tumoral bed. Thus, small lesions located in easily attainable areas such as oral cheek, floor of the mouth, internal lip, mobile tongue can be successfully treated with standard or finger electrodes; while larger nodules with complex tridimensional growth or located in the tongue base or oropharynx cannot be totally covered with the fixed geometry electrodes (2).

Despite these technical difficulties the percentages of objective response are encouraging (56% in the EURECA study) (4) and will be further improved with the development of new electrodes capable to completely electroporate tumors located in these particular areas or with the use of the single electrodes and the variable geometry (2).

The application of the variable geometry is particularly indicated for the treatment of head and neck deep seated tumors. These lesions are not simply hidden under the mucosal or skin visible surface, but they can be also located near vital structures (large blood vessels, cranial nerves), bone structures or in limited spaces. The

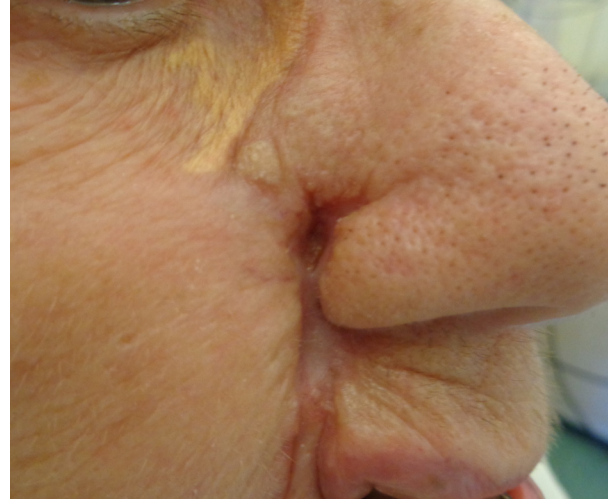
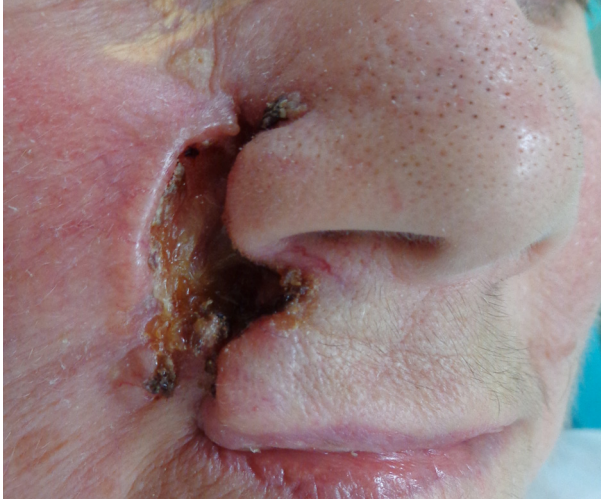
Figure 1 Primary BCC (left) and the response 6 months after 2 cycles of ECT (right)

determination of the adequate position for each single electrode and the sequence of the electric pulses deliverance during the procedure can be planned with specific softwares and Navigation Systems (5).

TREATMENT MODALITIES

Even if ECT in head and neck can be applied to the treatment of any kind of tumor site (cutaneous, subcutaneous, mucosal or deep seated) the choice of drug delivery, type of anesthesia and type of electrodes depend on the number, size, location and patient's general condition (Table 1) (2).

In general, when the tumors are located in the upper face or scalp, and are few (< 3 cm) and less than 2 cm in size, the procedure can be conducted under local anesthesia,

both drugs (bleomycin or cisplatin) can be used according to the Standard Operating Procedures (SOP) (1), and the choice of the electrode depending on the nodules' morphology and thickness or depth of invasion; while in case of more than 3 nodules and larger than 2 cm it is better to proceed under general anesthesia and with bleomycin given intravenously.

In case of tumors located in the lower face or neck, intraoral or deep seated the procedure must be performed under general anesthesia because of the possibility of severe pain and muscle contractions; the choice of drug administration and type of electrodes follow the SOPs (1).

Moreover, in case of intraoral or oropharyngeal lesions, a profilactic

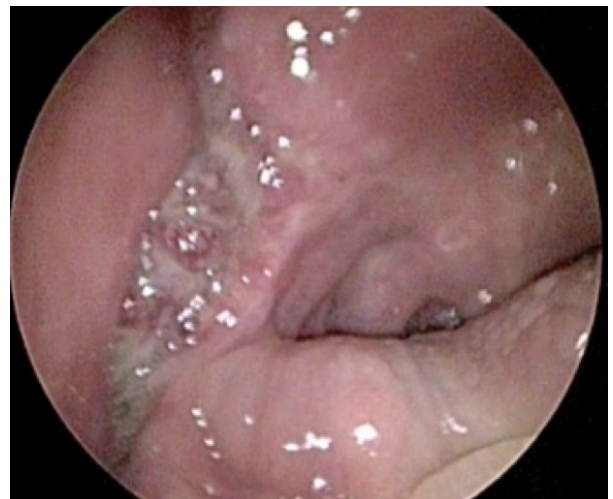
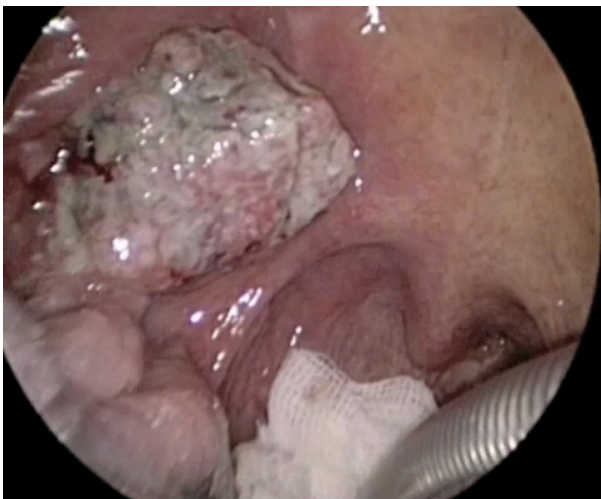
Figure 2 Primary SCC (left) and the response 2 months after ECT (right)

Table 1 Treatment modalities for cancers of the head and neck area

Treatment	Site, Number, Size	Anesthesia	Drug administration	Electrode
Modality A	Head, face < 3 nodules < 2 cm	Local ± Sedation	Bleomycin i.t./i.v. Cisplatin i.t.	Plate (if superficial) Row needle, Hexagonal, Finger (if deep)
Modality B	Head, face > 3 nodules > 2 cm	General	Bleomycin i.v.	Row needle, Hexagonal
Modality C	Cheek, Chin, Neck, Intraoral, Deep seated Any number Any size	General	Bleomycin i.t./i.v. Cisplatin i.t.	Row needle, Hexagonal, Finger Variable geometry

tracheotomy has to be considered due to the risk of swelling of the soft tissues.

CONTRAINDICATIONS

Contraindications to ECT in head and neck are the same of the SOPs (1) with the adjunct of macroscopic infiltration of the internal jugular vein or carotid artery because of the risk of blowout secondary to tumor necrosis induced by ECT (Table

2).

Moreover, attention must be paid in the treatment of full-thickness lesions of the cheek or peristomal recurrences because of the risk of salivary fistulas, or in the treatment of full-thickness lesions of the lip for the risk of labial incompetence (2,6).

FUTURE PERSPECTIVES

Usually, ECT is a safe treatment in head

Table 2 Absolute and relative contraindication for ECT in the head and neck area

Clinical situation	Absolute contraindication	Relative contraindication
Major vessel tumor infiltration	Macroscopic infiltration of the walls of the internal jugular vein or carotid artery	
Difficulties with local/general anesthesia	Yes	
Allergy to bleomycin or cisplatin	Yes	
Cumulative dose of bleomycin	>240,000 IU/m ²	
Full-thickness lesions of the chin, cheek, or lip, Peristomal lesions		High risk of salivary fistula and/or labial incompetence
Cardiac arrhythmias, pacemaker	Thorax application <7 cm	Head neck application (>30 cm from heart)
Pulmonary function (Fibrosis)	Bleomycin i.v.	<30 % O ₂ delivery Bleomycin i.t.
Hematology (PLT <70,000/mm ³ , INR >1,5)		Verify type of electrodes
Renal function (Creatinine <150 µmol/l)		Bleomycin i.t. Adequate hydration

and neck cancer patients because it results in minimal or null aesthetic and functional compromise and leads to healing of treated tumor lesions without damage to the surrounding healthy tissues. Therefore, particular attention must be reserved to elderly patients because the risk of severe side effects and necrosis can be higher due to increased serum levels of bleomycin, induced by the reduction of total body water and a decline in glomerular filtration rate (7). In order to avoid these possible complications, some authors have already proposed a reduced dose of bleomycin (10.000 IU/m²) in elderly patients, instead of the standard dose of 15.000 IU/m², since the serum clearance curve of bleomycin is slower (less than 500 ml/min) in elderly population (7).

The effectiveness of ECT in the treatment of cutaneous and subcutaneous tumor nodules, is high, with reported percentages of objective response approaching 100% (3); for this reason a future role for ECT as a first-line treatment of head and neck cancer, particularly in elderly patients, or as neo-adjuvant treatment for those cases in which surgical procedures and/or radiotherapy would be too devastating in achieving proper oncological results can be considered, even if randomized clinical trials are still necessary to confirm this possibility.

Although ECT is highly efficient on treated nodules, it remains a local treatment having no apparent antitumor effects on non-treated distant nodules, even though it has been demonstrated that electroporation induces inflammation of the treated tissue and then activation of the immune system (8).

The combination of ECT and immunotherapy may have a long-term effect on local and systemic cancer eradication and seems to be a future perspective (9,10).

Similarly, anti-programmed cell death protein 1 (PD1) antibodies are also of great interest as they prevent the inhibitory

effect on T cell functions of the interaction between PD1 (on T cells) and PD1 ligand (on tumor cells). Thus, a combination of ECT with anti-PD1 antibodies could be an elegant way to destroy the initial nodule while raising efficient antitumor responses to ultimately eliminate remaining and circulating cancer cells (8).

Alternatively, immune stimulation through electrogenetherapy (EGT) has also raised great hope for the treatment of cancer. Sersa et al. recently proposed a model of combination of ECT with peritumoral IL-12 electrotransfer; ECT boosted with immunogene electrotransfer could be considered a sort of in situ vaccination to potentiate not only death of the ECT-treated tumor nodule but also to activate the immune system toward the same tumor cells on distant metastases where it can exert its immunological actions (11).

REFERENCES

1. Gehl J, Sersa G, Wichmann Matthiessen L, Muir T, Soden D, Occhini A, et al. Updated standard operating procedures for electrochemotherapy of cutaneous tumours and skin metastases. *Acta Oncologica* 2018;25:1-9.
2. Benazzo M, Bertino G, Groselj A. Electrochemotherapy of Head and Neck Cancer. In Miklavčič D. ed. *Handbook of Electroporation*, Springer; 2017. p.1-14.
3. Bertino G, Sersa G, De Terlizzi F, Occhini A, Plaschke CC, Groselj A, et al. European research on electrochemotherapy in head and neck cancer (EURECA) project: results of the treatment of skin cancer. *Eur J Cancer* 2016;63:41-52.
4. Plaschke CC, Bertino G, McCaul JA, Grau JJ, de Bree R, Sersa G, et al. European Research on Electrochemotherapy in Head and Neck Cancer (EURECA) project: Results from the treatment of mucosal cancers. *Eur J Cancer* 2017;87:172-181.
5. Groselj A, Kos B, Cemazar M, Urbancic J, Kragelj G, Bosnjak M, et al. Coupling treatment planning with navigation system: a new technological approach in treatment of head

and neck tumors by electrochemotherapy. *Biomed Eng Online* 2015;14(Suppl 3):S2.

6. Campana LG, Bertino G, Rossi CR, Occhini A, Rossi M, Valpione S, et al. The value of electrochemotherapy in the treatment of peristomal tumors. *Eur J Surg Oncol*. 2014;40(3):260-262.
7. Groselj A, Krzan M, Kosjek T, Bosnjak M, Sersa G, Cemazar M. Bleomycin pharmacokinetics of bolus bleomycin dose in elderly cancer patients treated with electrochemotherapy. *Cancer Chemother Pharmacol* 2016;77:939–947.
8. Calvet CY, Mir LM The promising alliance of anti-cancer electrochemotherapy with immunotherapy. *Cancer Metastasis Rev* 2016;35:165-177.
9. Brizio M, Fava P, Astrua C, Cavaliere G, Savoia P. Complete regression of melanoma skin metastases after electrochemotherapy plus ipilimumab treatment: an unusual clinical presentation. *Eur J Dermatol* 2015;25:271–272.
10. Mozzillo N, Simeone E, Benedetto L, Curvietto M, Giannarelli D, Gentilcore G, et al. Assessing a novel immuno-oncology-based combination therapy: ipilimumab plus electrochemotherapy. *Oncoimmunology* 2015;4(6):1-8.
11. Sersa G, Teissie J, Cemazar M, Signori E, Kamensek U, Marshall G, et al. Electrochemotherapy of tumors as in situ vaccination boosted by immunogene electrotransfer. *Cancer Immunol Immunother* 2015;64:1315–1327.

ELECTROCHEMOTHERAPY OF DEEP SEATED TUMORS

Ibrahim Edhemovic

Institute of Oncology Ljubljana, Department of Surgical Oncology, Zaloska cesta 2, SI-1000 Ljubljana, Slovenia

E-mail: iedhemovic@onko-i.si

ECT is a local treatment that combines application of electric pulses to increase the uptake of cytotoxic drugs, such as bleomycin and cisplatin, into tumor cells. ECT has already been implemented as palliative treatment of skin melanoma metastases, but is also effective in treatment of other cutaneous and subcutaneous nodules regardless of their histological origin. The objective response rate of the ECT treated nodules is 80% and long lasting complete response rate is 70%. ECT was successfully translated into treatment of bigger (≥ 3 cm in diameter) and deep-seated tumors with the technological adaptation of the procedure and verification of its safety and effectiveness.

Our first study on a case of patient with solitary colorectal cancer metastasis in the liver showed the feasibility of the method. Based on that data, first pilot clinical study for the treatment of colorectal liver metastases in order to evaluate the feasibility, safety and efficacy of electrochemotherapy was conducted. Treatment with electrochemotherapy was effective, a high response rate of complete response was observed. High response rate was observed in all groups regardless of anatomical locations of the liver, also on metastases in the vicinity of major hepatic vessels

Treatment of colorectal liver metastases with electrochemotherapy is feasible, as long as the electrodes are precisely placed into and around the metastases. Treatment plan should be prepared for each patient separately to fulfill this requirement. Furthermore, electrochemotherapy is also appropriate for the treatment of unresectable metastases, such as those

located near major vessels or nerve bundles. Efficacy of radiofrequency ablation, for example, which is also one of the methods for treatment of inoperable metastases, is in the vicinity of big vessels lower due to heat sink effect.

Electrochemotherapy of hepatocellular carcinoma proved to be a feasible, safe and effective treatment in patients who were not amenable to other therapeutic ablative techniques. Electrochemotherapy is predominantly applicable in patients with impaired liver function due to liver cirrhosis and/or with lesions where a high-risk operation is needed to achieve curative treatment, given the intra/perioperative risk for high morbidity and mortality

Finally, benefits of electrochemotherapy are not only due to the treatment alone, but survival time could be prolonged also due to possibility of additional treatments. Our ongoing study will gain new knowledge in a field of electrochemotherapy treatment of colorectal metastases.

Electrochemotherapy is safe and effective intraoperative treatment approach for liver metastases, as well as primary liver tumors, which are found to be in difficult-to-treat locations or are untreatable with other standard ablation techniques. Electrochemotherapy has being translated also into treatment of other deep seated tumors. Based on the principle of treatment of liver tumors some studies performed on pancreatic tumors as well as bone metastases. Endoscopic devices suitable for treatment of colorectal tumors were developed as well and clinical study is ongoing.

TREATMENT PLANNING FOR ELECTROPORATION-BASED THERAPIES

Bor Kos

University of Ljubljana, Faculty of Electrical Engineering, Trzaska cesta 25, SI-1000 Ljubljana, Slovenia

E-mail: bor.kos@fe.uni-lj.si

Electroporation is a phenomenon in which exposure of cells to short pulses of electric fields causes an increase in the permeability of the cellular membrane to ions, small, and large molecules (1). Currently, the two applications, which have the most clinical evidence and have been most intensely studied are electrochemotherapy (ECT) and irreversible electroporation (IRE) (2,3). For ECT the electric field pulses needed to achieve therapeutic effect are 8 pulses of 100 microseconds, while for IRE, 90 pulses of 70 to 100 microseconds are recommended.

The most important predictor of successful electroporation is the local electric field strength *in situ* (4). The electric field in tissue depends on the voltage applied to the electrodes, the number, geometry and position of the electrodes, and the tissue conductivity. The tissue conductivity of different tissues is markedly different, tumour tissue also typically has much higher conductivity than surrounding healthy tissue (5); tissue conductivity also transiently increases due to electroporation during the pulses (6). To realize patient-specific treatment planning the following steps are needed: tomographic image segmentation, electric field calculation and optimization of electrode positions and applied voltages (7). The final results of the optimization need to be presented in an understandable way, so that the patient-specific treatment plan can be successfully followed by the performing physician; this can also be achieved using navigation systems (8).

Acknowledgements: This work was in

part supported by Slovenian Research agency and conducted in the scope of LEA EBAM.

References

1. Yarmush ML, Golberg A, Serša G, Kotnik T, Miklavčič D. Electroporation-Based Technologies for Medicine: Principles, Applications, and Challenges. *Annu Rev Biomed Eng* 2014;16(1):295–320.
2. Mir LM, Orlowski S, Belehradek J, Paoletti C. Electrochemotherapy Potentiation of Antitumor Effect of Bleomycin by Local Electric Pulses. *Eur J Cancer* 1991;27(1):68–72.
3. Davalos R, Mir L, Rubinsky B. Tissue Ablation with Irreversible Electroporation. *Ann Biomed Eng* 2005;33(2):223–31.
4. Miklavcic D, Beravs K, Semrov D, Cemazar M, Demsar F, Sersa G. The importance of electric field distribution for effective *in vivo* electroporation of tissues. *Biophys J* 1998;74(5):2152–8.
5. Peyman A, Kos B, Djokić M, Trotovšek B, Limbaeck-Stokin C, Serša G, et al. Variation in dielectric properties due to pathological changes in human liver. *Bioelectromagnetics* 2015;36(8):603–12.
6. Corovic S, Lackovic I, Sustaric P, Sustar T, Rodic T, Miklavcic D. Modeling of electric field distribution in tissues during electroporation. *Biomed Eng OnLine* 2013;12(1):16.
7. Pavliha D, Kos B, Županič A, Marčan M, Serša G, Miklavčič D. Patient-specific treatment planning of electrochemotherapy: Procedure design and possible pitfalls. *Bioelectrochemistry* 2012;87:265–73.
8. Grosej A, Kos B, Cemazar M, Urbancic J, Kragelj G, Bosnjak M, et al. Coupling treatment planning with navigation system: a new technological approach in treatment of head and neck tumors by electrochemotherapy. *Biomed Eng Online* 2015;14 Suppl 3:S2.

ECT TREATMENT VERIFICATION

Nina Boc

Institute of Oncology Ljubljana, Department of Radiology, Zaloska cesta 2, SI-1000 Ljubljana, Slovenia

E-mail: nboc@onko-i.si

Ablative techniques provide an effective tool for local treatment of liver tumors. Radiofrequency ablation is the most frequently used local method, whereas electroporation-based treatments are being explored as possible alternatives. US imaging is mostly used for the identification of the electrode placement according to the treatment plan and US specific changes are detected for identification of adequate tumor coverage. Treatment monitoring and understanding the imaging findings to predict the tumor response to ECT are important.

The effect after ECT is slow. We observed tumor response in three phases after ECT: Immediate effects, Intermediate effects after a few days and late effects.

We observed immediate effects with US, the changes in the ablation zone were followed to identify whether they appear in the entire treated tumor, therefore indicating an effective electroporation of the tumor.

Intermediate and late effects can be evaluated with US, CT or MRI.

Morphologic methods such as the Response Evaluation Criteria in Solid Tumors (RECIST 1.1) are considered the gold standard for response assessment in the management of cancer. However conventional morphologic methods are confronting limitations in response assessment (1).

All local treatments attempt to induce necrosis of the tumor, which may delay tumor shrinkage during the early post-treatment period. Given these limitations of morphologic response criteria, the American Association for the Study of Liver Disease (AASLD) proposed the

modified RECIST (mRECIST) criteria, which conceptualized viable tumor measurements (2). mRECIST had better overall response rate than conventional morphologic criteria such as RECIST 1.1 (3) and a better correlation with survival.

Diffusion-weighted MRI (DWI) is unique among imaging technique, although many studies have confirmed the usefulness of DWI and its diagnostic role in cancer imaging. A significant and growing volume of data are now gathering to support its use for tumour response assessment (4). Restriction in the diffusion of water molecules is directly proportional to the degree of cellularity of the tissue. In general, an increase in ADC value in response to treatment has been shown to be associated with better outcome (5,6).

References

1. Forner A, Ayuso C, Varela M, Rimola J, Hessheimer AJ, de Lope CR, et al. Evaluation of tumor response after locoregional therapies in hepatocellular carcinoma: Are response evaluation criteria in solid tumors reliable? *Cancer* 2009;115:616–23.
2. Lencioni R, Llovet JM. Modified RECIST (mRECIST) assessment for hepatocellular carcinoma. *Semin Liver Dis* 2010;30:52–60.
3. Prajapati HJ, Spivey JR, Hanish SI, El-Rayes BF, Kauh JS, Chen Z, et al. mRECIST and EASL responses at early time point by contrast-enhanced dynamic MRI predict survival in patients with unresectable hepatocellular carcinoma (HCC) treated by doxorubicin drug-eluting beads transarterial chemoembolization (DEB TACE) *Ann Oncol* 2013;24:965–73.
4. Choi H, Charnsangavej C, Faria SC, Macapinlac HA, Burgess MA, Patel SR, et al. Correlation of computed tomography and positron emission tomography in patients

with metastatic gastrointestinal stromal tumor treated at a single institution with imatinib mesylate: Proposal of new computed tomography response criteria. *J Clin Oncol* 2007;25:1753–9.

5. A. Afaq, A. Andreou and D.M. Koh. Diffusion-weighted magnetic resonance imaging for tumour response assessment: why, when and how? *Cancer Imaging* 2010, S179-S188
6. Pedram Rezai, Mark J. Pisaneschi, Chun Fenf+g, Vahid Yaghmai. A radiologist's guide to treatment response criteria in oncologic imaging: functional, molecular and disease-specific imaging biomarkers. *AJR* 2013, Vol. 201, No. 2

EXPERIENCE IN TREATMENT OF COLORECTAL LIVER METASTASES

Erik Brecelj, Ibrahim Edhemovic

Institute of Oncology Ljubljana, Department of Surgical Oncology, Zaloska cesta 2, SI-1000 Ljubljana, Slovenia; E-mail: ebrecelj@onko-i.si

More than 30 % of patients with colorectal cancer developed liver metastases. Radical surgical resection of liver metastases remains the only chance of cure with more than 50% 5-year survival. Unfortunately, most of the patients are presented with unresectable metastases because of their size, number, location or inadequate liver remnant after resection.

In unresectable disease, many ablative approaches can be used. The most frequent is radiofrequency ablation(RFA). However, RFA is less effective in the treatment of metastases in the vicinity of major hepatic vessels due to heat sink effect.

From 2009 to 2018 35 patients with colorectal liver metastases were treated with electrochemotherapy at our department. In our first published analyses, 29 metastases in 16 patients were treated with electrochemotherapy during open surgery by US-guided insertion of long needle electrodes (with variable or fixed geometry) into and around the tumor. Up to three metastases not exceeding 3 cm in the diameter were treated with electrochemotherapy. Patients were divided into three groups. In the first two groups were patients with two-stage liver surgery. In the first operation, some of the metastases were treated by electrochemotherapy and removed during the second operations. In the third group patients with unresectable metachronous metastases were treated with electrochemotherapy as the only treatment option.

There was no perioperative mortality. Three patients required reoperation after electrochemotherapy; two because of

colon perforation and one because of obstruction of small bowel because of adhesions. None of these complications were related to electrochemotherapy. During or after electrochemotherapy no major heart rhythm changes or myocardial ischemia were found.

Radiological complete response was observed in 85% of treated metastases and partial in 15% after the first radiological evaluation. At the second evaluation, at a median of 147 days after electrochemotherapy, 71% of metastases were still in complete response. Response to electrochemotherapy was the same in metastases located close to major hepatic vessels and metastases away from the vessels. On pathological analysis, non treated metastases had a significantly higher percentage of residual viable tumor compared to electrochemotherapy treated.

We found regressive changes in the whole electrochemotherapy-treated area of the liver with disruption of vessels less than 5 mm in diameter and preservation of the larger vessels and biliary ducts.

Electrochemotherapy of liver metastases is feasible, efficient and safe treatment modality, especially for the metastases in the vicinity of major hepatic vessels.

EXPERIENCE IN TREATMENT OF HEPATOCELLULAR CARCINOMA

Blaz Trotovsek, Mihajlo Djokic

University Medical Centre Ljubljana, Department of Abdominal Surgery, Zaloska cesta 7, SI-1000 Ljubljana, Slovenia

Abstract: *Electrochemotherapy provides non-thermal ablation of cutaneous as well as deep seated tumors. Based on positive results of the treatment of colorectal liver metastases, we conducted a prospective pilot study on hepatocellular carcinomas with the aim of testing the feasibility, safety and effectiveness of electrochemotherapy. Electrochemotherapy with bleomycin was performed on 17 hepatocellular carcinomas in 10 patients using a previously established protocol. The procedure was performed during open surgery and the patients were followed for median 30 months. Electrochemotherapy was feasible for all 17 lesions, and no treatment-related adverse events or major post-operative complications were observed. The median size of the treated lesions was 24 mm (range 8-41 mm), located either centrally, i.e., near the major hepatic vessels, or peripherally. At last radiological follow-up the complete response rate was 90% per patient (9/10) and 94% per treated lesion (16/17). Electrochemotherapy of hepatocellular carcinoma proved to be a feasible and safe treatment in all 10 patients included in this study. To evaluate the effectiveness of this method, longer observation period is needed; however, the results at medium observation time of 30 months after treatment are encouraging, in 16 out of 17 lesions complete response was obtained. Electrochemotherapy is predominantly applicable in patients with impaired liver function due to liver cirrhosis and/or with lesions where a high-risk operation is needed to achieve curative intent, given the intra/perioperative risk for high morbidity and mortality.*

INTRODUCTION

Hepatocellular carcinoma (HCC), together with intrahepatic cholangiocarcinoma, represents more than 98.5% of all primary liver tumors, and its incidence is rising worldwide. HCC is the third most common cause of cancer-related deaths in the world and is responsible for between 650,000 and one million deaths globally per year (1-3).

The optimal treatment options for patients with HCC are curative surgical resection, liver transplantation and, in rare cases, radio-frequency ablation (RFA). Other methods, such as local ablative techniques (percutaneous ethanol (PEI) or acetic acid injection (PAI) in tumor, RFA, microwave ablation (MWA), transarterial chemoembolization (TACE), targeted therapy, chemo- and radiotherapy and others are used only as palliative

treatment and in some cases as bridging therapy (TACE, RFA) for possible curative liver transplantation. Most patients with HCC are complex, with only 20% having straight forward treatment scenarios. Therefore, the majority of patients (more than 60%) receive some combination of therapies, depending on the stage of the disease (4-10).

Despite intensive surveillance programs, considerable recent therapeutic advances, and the use of potentially radical treatments, prognosis and life expectancy remain low in patients with HCC (11). Electroporation-based treatments, including irreversible electroporation (IRE) and electrochemotherapy, are new local treatment approaches that are gaining importance. Electrochemotherapy already has an established place among other local treatments for the treatment of cutaneous tumors (12), but the translation of electrochemotherapy into deep-seeded

tumors is lagging behind (13).

However, the first encouraging results for the treatment of colorectal liver metastases have already been published (14,15). Based on the encouraging clinical results, we conducted a prospective pilot clinical study to establish the feasibility, safety, and effectiveness of electrochemotherapy in the treatment of HCC. In the study, patients not amenable to other therapeutic ablative techniques were included. Furthermore, electrochemotherapy was also employed to treat tumors located in the vicinity of the major blood vessels where other ablative techniques, such as RFA or MWA, would not have been efficient due to the heat sink effect.

PATIENTS AND METHODS

Study design

The study was designed as a prospective, pilot study. Patients were presented at the multidisciplinary team meetings consisting of a surgeon, radiologist and gastro-oncologist. Before inclusion into the trial, all patients signed written informed consent. The primary endpoint of the study was to assess the feasibility and safety of electrochemotherapy in the treatment of HCC. The secondary aim was to determine the efficacy of ECT, based on a radiological evaluation of treated lesions, as measured by modified Choi criteria (17). Electrochemotherapy was performed according to the Standard Operating Procedures for treatment of cutaneous tumors and the associated modifications for the treatment of liver tumors and reporting of data according the published recommendations (15,18,19).

Patients

In this trial, 10 patients with 17 lesions were enrolled from February 2014 to November 2016, based on the inclusion and exclusion criteria (Table 1). The diagnosis was confirmed either histologically (in 4 patients) (20), or by typical radiological appearance according to the EASL-

EORTC Clinical Practice Guidelines for Management of hepatocellular carcinoma (5). Patients were divided into three groups according to the indications and previous treatments.

The first group represented patients in whom the local ablative technique was unsuccessful (TACE/RFA) and electrochemotherapy was offered as an additional treatment. In this group, 3 patients with 6 lesions were treated. Two of these patients underwent TACE, which was unsuccessful (progress of the treated lesion at the follow up), and further treatment with TACE was not indicated. According to the Barcelona Clinic Liver Cancer (BCLC) algorithm (21), treatment for advanced or terminal stage disease should be offered. The third patient in this group had previously been treated with RFA, which was unsuccessful, and other ablative techniques were not indicated.

The second group included patients for whom transplantation, radical surgery or other local ablative techniques were not indicated due to patients' performance status, the location of the lesions, or contraindications to the ablative techniques. However, electrochemotherapy was performed with curative intent. In this group, 6 patients with 9 lesions were treated.

The third group included a patient for whom electrochemotherapy was offered as "bridging" to transplantation option. In this patient, 2 lesions were treated. During the first procedure in 2009, right hemihepatectomy with resection of middle and right hepatic veins in un-cirrhotic liver was performed due to HCC. In 2015, the patient developed 2 new HCC lesions located in proximity to the left hepatic vein, so electrochemotherapy was offered to the patient as a "bridging" to liver transplantation.

Lesions were defined as "central" or "peripheral" based on their relation to the major blood vessels. The term "central" was used for the lesions in the close vicinity

of the major blood vessels including the main hepatic or portal veins and the main hepatic arterial branches. The term “peripheral” was used for lesions not adjacent to the major blood vessels where RFA or other ablative techniques were not indicated by interventional radiologist blinded to the study (22,23).

Treatment procedure

All 10 patients enrolled in the study were treated during open surgery. Median laparotomy, extended to the right subcostal incision, was performed in 8/10 patients. In 2 patients, only upper median laparotomy was used. The electrodes used for electric pulse delivery were either single long (20 cm) needle electrodes (variable geometry) with 3 or 4 cm active part or 7-needle electrodes fixed on the holder in hexagonal geometry and 3 cm active part (24,25). The choice of electrode use was dependent on the location of the lesion. Electrodes with variable geometry i.e., long needle electrodes were used for deep seated tumors located more than 3 cm below the surface of the liver. The hexagonal electrodes were used for more superficial tumors that had their deepest margins less than 3 cm from the liver surface (24,25). Specifically, the treatment of lesions in segment 8 included the use of both types of the electrodes, where for the use of hexagonal electrodes mobilization of the liver was required. The intraoperative ultrasound was used to identify lesions and aid the positioning of the electrodes into and around the tumor. The long needle electrodes were positioned according to the pretreatment plan prepared for each patient and specific tumor individually using previously developed procedures (26,27). Plans were developed based on computed tomography and/or magnetic resonance scans taken less than 30 days prior to treatment. Target lesions (up to 41 mm in the largest diameter) were segmented. A gradient-based optimization algorithm was used to optimize voltage between each electrode

pair to maximize tumor coverage above the reversible electroporation threshold (400 V/cm) and minimize the volume of healthy liver parenchyma above the irreversible electroporation threshold (700 V/cm). The intravenous bolus of bleomycin was given to the patient after the intra-operative ultrasound confirmed the correct electrode placement. Trains of eight electric pulses (electrodes with variable geometry) or 24 (fixed geometry) electric pulses (each pulse 100 ms long) were delivered to each pair of electrodes consecutively. Electric pulses were delivered by electric pulse generator during an interval of 8-28 min after the intravenous injection of bleomycin 15,000 IU/m² in bolus, as being determined to be the optimal pharmacological peak for the bleomycin in the tumors (16).

Efficacy assessment based on radiology

Lesions treated in the study were assessed before electrochemotherapy by contrast-enhanced computed tomography (CECT) or with magnetic resonance imaging (CEMRI) using a distinct hepatocyte contrast (gadoliniummethoxybenzyl-diethylenetriaminepentaacetic acid-Gd-EOB-DTPA). The follow-up was performed by CECT in all the patients but one in whom the CEMRI was performed at the 3- months follow-up. Images were evaluated by two radiologists, one of whom was blinded to the trial. Modified Choi criteria were used to assess the treatment response (17). Evaluations of both radiologists were in complete consensus.

RESULTS

Feasibility, safety, and response to treatment evaluation were evaluated for all 10 patients and 17 lesions.

Feasibility

Electrochemotherapy was feasible in all 10 patients enrolled in the study, according to the inclusion and exclusion criteria (Table 1). Three females and 7 males were included, with a median age 69.5 years

Table 1 Inclusion and exclusion criteria for electrochemotherapy in HCC.

Inclusion criteria
1. HCC confirmed by radiological imaging and/or histology.
2. Age more than 18 years.
3. Life expectancy more than 3 months.
4. Performance status Karnofsky 70 or WHO (World Health Organization) < 2.
5. Signed informed consent.
6. Unanimous decision of the multidisciplinary liver tumor team before entering the trial (surgeon, gastro-oncologist and radiologist).
Exclusion criteria
1. Multiple primary tumors.
2. Extrahepatic disease.
3. Poor performance status.
4. Clinically significant ascites.
5. Exposure to cumulative bleomycin doses in excess of 400 mg.
6. Allergic reaction to bleomycin.
7. Impaired kidney function (Creatinine > 150 mmol/l).
8. Pregnancy, epilepsy, heart arrhythmias or patient having cardiac pace maker.

(range: 57-78 years). Three patients had undergone previous treatment with TACE and/or RFA, and one had undergone liver resection. Six patients had received electrochemotherapy as a primary treatment. The previously operated patient had electrochemotherapy as a bridging procedure for liver transplantation.

Patients were treated according to the Standard Operating Procedures for cutaneous tumors, modified for the liver tumors during open surgery (16,24). The median size of the treated lesions was 24 mm with a range of 8-41 mm. Electrochemotherapy was also feasible in patients with centrally located lesions in the vicinity of major hepatic vessels (8/17 lesions).

Safety

Adverse reactions related to electrochemotherapy did not occur, despite the American Society of Anesthesiologists (ASA) score of 3 (8/10 patients) and ASA score of 2 (2/10 patients). No intraoperative or postoperative complications during the first 24 h occurred. The exceptions

were the two patients with the ascites production after the procedure due to transient liver failure. Ascites was resolved by conservative measures. Nevertheless, patients were classified as Clavien-Dindo 3a and 3b because in both additional diagnostic/intervention was necessary: in one patient the ERCP was performed due to choledocholithiasis; the second patient had elevation of cholestatic enzymes and the endoscopic ultrasound was performed to clarify the origin of elevated enzymes. The impaired liver function was a result of liver cirrhosis before the operation and was not related to the electrochemotherapy.

All 10 patients were discharged from the hospital after a median hospitalization of 5.5 days (range: 2-20 days) and were followed on an outpatient basis. ECG signals were recorded during and 24 h after the electrochemotherapy. No onset of new or worsening of existing pathological morphological changes was recorded. There were no signs of myocardial ischemia, new-onset of atrial and/or ventricular extrasystoles, or increased frequency of abnormal heartbeats in

relation to the electrochemotherapy procedure. Centrally located tumor lesions (8/17) near major hepatic vessels were successfully treated without adverse events.

Effectiveness

The first radiologic follow-up was 1 month after treatment (median 31 days; range from 23 to 45 days). All 17 lesions were evaluated and a complete response was found in 15/17 lesions (88%). Two lesions had a partial response according to the modified Choi criteria, due to the small field of enhancement, without changes in lesion size.

The second radiological follow-up was 3-6 months after the treatment (median 194 days; range from 100 to 218 days). All 17 lesions were evaluated, and according to the modified Choi criteria, all of the lesions that had been initially evaluated after 1 month, i.e., the 15/17 lesions, remained in complete response. Two lesions identified in the previous follow-up as partial responses (2/17, 12%) remained in the stage of partial response and the patients were considered being in stable disease.

The last radiological follow-up was 12-37 months after the treatment (median 30 months). One of the lesion that was previously evaluated as stable disease, was described as complete response after last radiological follow-up. The rest of the lesions remained unchanged, therefore a complete response was observed in 16/17 lesions (94%).

DISCUSSION

Electrochemotherapy has, after successful translation into treatment of cutaneous tumors, progressed into translation of deep seated tumors. This study confirmed the feasibility, safety and effectiveness of electrochemotherapy in the treatment of HCC. No treatment or postoperative adverse events were recorded, including in patients with lesions located near the major hepatic vessels. The overall response was high, 94% (16/17) of the

treated lesions and 90% (9/10) of patients had complete responses.

The feasibility and safety of electrochemotherapy was already demonstrated in a previous study on the treatment of colorectal liver metastases. The response rate of that study was 85% complete responses on 29 metastases in 16 patients which is comparable to the 94% complete response rate in this prospective pilot study on HCC (15). The technology that has proven to be feasible and safe in the previous study was also confirmed in this study and another recently published study (14), in cases where other ablative techniques are not indicated.

In this study, not only patients with previously unsuccessfully treated tumors, but also patients for whom standard treatment with curative intent could not be offered were included. In one patient, this method was used as a bridging to liver transplantation. Two patients had post-operative complications in the form of transient liver function failure with consequent ascites production. Based on poor performance status of the recruited patients in whom other treatments were not feasible, electrochemotherapy provides effective treatment of lesions in such patients. Therefore, it could be considered as a technique with curative intent, which, however, needs to be confirmed in a phase II study in a larger cohort of patients.

One of the limitations of this approach is that larger tumors tend to have lower response rates. As indicated by several other studies, tumors larger than 3 cm in diameter seldom have complete responses (28,29). The method in our case was upgraded by the treatment plan that intended to predict the optimal electrode placement for effective electroporation of the tumors. This certainly aided better execution of the electroporation of lesions larger than 3 cm in diameter, but the step for effective verification of

the tumor coverage after electroporation is still missing. This can be executed either by US verification, as noted in IRE and also by electrochemotherapy, or by development of measuring tools for the current distribution in the tumors by MRI, which is still in progress (29-31).

This study, however, has some limitations. Based on the fact that it is a pilot study and on small cohort of patients, only ten, the conclusion about the effectiveness of electrochemotherapy is premature. Nevertheless, the preliminary data foster the continuation of this study in phase II one.

In conclusion, our experience demonstrate feasibility, safety and provides preliminary data on the high effectiveness of electrochemotherapy in HCC. Electrochemotherapy could be predominantly applicable in patients with impaired liver function due to liver cirrhosis and/or with lesions where a high-risk operation is needed to achieve curative intent.

REFERENCES

1. Forner A, Llovet JM, Bruix J. Hepatocellular carcinoma. *Lancet* 2012;379(9822):1245e55.
2. Shariff MI, Cox IJ, Gomaa AI, Khan SA, Gedroyc W, Taylor-Robinson SD. Hepatocellular carcinoma: current trends in worldwide epidemiology, risk factors, diagnosis, and therapeutics. *Expert Rev Gastroenterol Hepatol* 2009;3(4): 353e67.
3. Bosch FX, Ribes J, Cleries R, Díaz M. Epidemiology of hepatocellular carcinoma. *Clin Liver Dis* 2005;9:191e211.
4. Llovet JM, Bustamante J, Castells A, Vilana R, Ayuso MC, Sala M, et al. Natural history of untreated nonsurgical hepatocellular carcinoma: rationale for the design and evaluation of therapeutic trials. *Hepatology* 1999;29(1):62e7.
5. European Association For The Study Of The Liver. EASLeEORTC clinical practice guidelines: management of hepatocellular carcinoma. *J Hepatol* 2012;56(4):908e43.
6. Figueras J, Jaurrieta E, Valls C, Ramos R, Serrano T, Rafecas A, et al. Resection or transplantation for hepatocellular carcinoma in cirrhotic patients: outcomes based on indicated treatment strategy. *J Am Coll Surg* 2000;190(5):580e7.
7. Yao FY, Bass NM, Nikolai B, Davern TJ, Kerlan R, Wu V, et al. Liver transplantation for hepatocellular carcinoma: analysis of survival according to the intention-to-treat principle and dropout from the waiting list. *Liver Transpl* 2002;8(10):873e83.
8. Bruix J, Sherman M. Management of hepatocellular carcinoma. *Hepatology* 2005;42(5):1208e36.
9. Cho YK, Kim JK, Kim MY, Rhim H, Han JK. Systematic review of randomized trials for hepatocellular carcinoma treated with percutaneous ablation therapies. *Hepatology* 2009;49(2):453e9.
10. Teratani T, Yoshida H, Shiina S, Obi S, Sato S, Tateishi R, et al. Radiofrequency ablation for hepatocellular carcinoma in so-called high-risk locations. *Hepatology* 2006;43(5):1101e8.
11. Cabibbo G, Craxi A. Hepatocellular cancer: optimal strategies for screening and surveillance. *Dig Dis* 2009;27(2):142e7.
12. Bertino G, Sersa G, De Terlizzi F, Occhini A, Plaschke CC, Groselj A, et al. European research on electrochemotherapy in head and neck cancer (EURECA) project: results of the treatment of skin cancer. *Eur J Cancer* 2016;63:41e52.
13. Scheffer HJ, Nielsen K, De Jong MC, Tilborg AJM, Vieveen JM, Bouwman RA, et al. Irreversible electroporation for nonthermal tumor ablation in the clinical setting: a systematic review of safety and efficacy. *J Vasc Interv Radiol* 2014: 997e1011.
14. Coletti L, Battaglia V, De Simone P, Turturici L, Bartolozzi C, Filipponi F. Safety and feasibility of electrochemotherapy in patients with unresectable colorectal liver metastases: a pilot study. *Int J Surg* 2017;44:26e32.
15. Edhemovic I, Breclj E, Gasljevic G, Music MMarolt, Gorjup V, Mali B, et al. Intraoperative electrochemotherapy of colorectal liver metastases. *J Surg Oncol* 2014;110(3):320e7.

16. Mir LM, Gehl J, Sersa G, Collins CG, Garbay JR, Billard V, et al. Standard operating procedures of the electrochemotherapy: instructions for the use of bleomycin or cisplatin administered either systemically or locally and electric pulses delivered by the CliniporatorTM by means of invasive or non-invasive electrodes. *Eur J Cancer Suppl* 2006;14e25.
17. Weng Z, Ertle J, Zheng S, Lauenstein T, Mueller S, Bockisch A, et al. Choi criteria are superior in evaluating tumor response in patients treated with transarterial radioembolization for hepatocellular carcinoma. *Oncol Lett* 2013;6: 1707e12.
18. Marty M, Sersa G, Garbay JR, Gehl J, Collins CG, Snoj M, et al. Electrochemotherapy: an easy, highly effective and safe treatment of cutaneous and subcutaneous metastases: results of ESOPE (European Standard Operating Procedures of Electrochemotherapy) study. *Eur J Cancer Suppl* 2006;4(11): 3e13.
19. Campana LG, Clover AJP, Valpione S, Quaglino P, Gehl J, Kunte C, et al. Recommendations for improving the quality of reporting clinical electrochemotherapy studies based on qualitative systematic review. *Radiol Oncol* 2016;1e13.
20. McGahan JP, Bishop J, Webb J, Howell L, Torok N, Lamba R, et al. Role of FNA and core biopsy of primary and metastatic liver disease. *Int J Hepatol* 2013;2013:174103.
21. Saraswat VA, Pandey G, Shetty S. Treatment algorithms for managing hepatocellular carcinoma. *J Clin Exp Hepatol* 2014;4(3):80e9.
22. Komorizono Y, Oketani M, Sako K, Yamasaki N, Shibata T, Maeda M, et al. Risk factors for local recurrence of small hepatocellular carcinoma tumors after a single session, single application of percutaneous radiofrequency ablation. *Cancer* 2003;97(5):1253e62.
23. Llovet J, Vilana R, Brú C, Bianchi L, Salmeron JM, Boix L, et al. Increased risk of tumor seeding after percutaneous radiofrequency ablation for single hepatocellular carcinoma. *Hepatology* 2001;33(5):1124e9.
24. Miklavcic D, Sersa G, Brecelj E, Gehl J, Soden D, Bianchi G, et al. Electrochemotherapy: technological advancements for efficient electroporation-based treatment of internal tumors. *Med Biol Eng Comput* 2012;50(12): 1213e25.
25. Sersa G, Miklavcic D, Cemazar M, Rudolf Z, Pucihar G, Snoj M. Electrochemotherapy in treatment of tumours. *Eur J Surg Oncol* 2008;34(2):232e40.
26. Marcan M, Pavliha D, Kos B, Forjanic T, Miklavcic D. Web-based tool for visualization of electric field distribution in deep-seated body structures and planning of electroporation-based treatments. *Biomed Eng Online* 2015;14(Suppl 3):S4.
27. Zupanic A, Kos B, Miklavcic D. Treatment planning of electroporation-based medical interventions: electrochemotherapy, gene electrotransfer and irreversible electroporation. *Phys Med Biol* 2012;57(17):5425e40.
28. Zeng J, Liu G, Li Z, Yang Y, Fang G, Li R, et al. The safety and efficacy of irreversible electroporation for large hepatocellular carcinoma. *Technol Cancer Res Treat* 2017;16(1):120e4.
29. Bhutiani N, Doughtie CA, Martin RCG. Ultrasound validation of mathematically modeled irreversible electroporation ablation areas. *Surgery* 2016; 159(4):1032e40.
30. Sersa I, Kranjc M, Miklavcic D. Current density imaging sequence for monitoring current distribution during delivery of electric pulses in irreversible electroporation. *Biomed Eng Online* 2015;14(Suppl 3):1e12.
31. Kranjc M, Kranjc S, Bajd F, Sersa G, Sersa I, Miklavcic D. Predicting irreversible electroporation-induced tissue damage by means of magnetic resonance electrical impedance tomography. *Sci Rep* 2017;7(1):10323.

AUTHOR INDEX

B

Bertino G. 23

Boc N. 30

Brecelj E. 32

C

Campana L. 21

Cemazar M. 10

D

Djokic M. 33

E

Edhemovic I. 28, 32

G

Gehl J. 19

Groselj A. 21

K

Bor Kos 29

M

Miklavcic D. 8

S

Sersa G. 10

Snoj M. 18

T

Trotovsek B. 33

ESSO is grateful for the continuous support of its corporate sponsors



Medtronic
Further, Together

The course is supported by:



European Society of Surgical Oncology (ESSO)
Avenue E. Mounier 83
B 1200 Brussels
Tel: +32 (0)2 5373106
Fax : +32 (0) 5390374
Email : info@essoweb.org
Website : www.essoweb.org