

Primarni leiomiosarkom spodnje votle vene: prikaz primera z radikalno resekcijo in rekonstrukcijo vene

Primary leiomyosarcoma of the inferior vena cava necessitating radical resection and reconstruction: case report

Avtor / Author

Ustanova / Institute

Jan Hansel¹, Božidar Mrdža², Vojko Flis^{1,2}

¹Univerza v Mariboru, Medicinska fakulteta, Maribor, Slovenija; ²Univerzitetni klinični center Maribor, Oddelek za žilno kirurgijo, Maribor, Slovenija

¹University of Maribor, Faculty of Medicine, Maribor, Slovenia; ²University Medical Centre Maribor, Department of Vascular Surgery, Maribor, Slovenia

Ključne besede:

leiomiosarkom, spodnja votla vena, radikalna resekcija, pooperativna tromboza žilne proteze

Key words:

Leiomyosarcoma, Inferior vena cava, Radical surgery, Postoperative vascular graft thrombosis

Članek prispel / Received

14.01.2013

Članek sprejet / Accepted

12.11.2013

Naslov za dopisovanje /

Correspondence

Vojko Flis, Univerzitetni klinični center Maribor, Oddelek za žilno kirurgijo, Ljubljanska 5, SI-2000 Maribor, Slovenija
E-pošta: vojko.flis@ukc-mb.si

Izvleček

Primarni tumorji spodnje votle vene (v. cava inferior) so izjemno redki; doslej je bilo po svetu poročano le o okoli 300 primerih. Predstavljen je primer 68-letne pacientke, pri kateri je bil tumor najprej odkrit z ultrazvočno preiskavo, ki je bila napravljena zaradi stalne tope bolečine v desnem zgornjem kvadrantu trebušne votline. Računalniška tomografija (CT) in jedrska magnetna resonanca (MRI) sta pokazali, da gre za maligno raščo znotraj spodnje votle vene. Pacientka je bila zdravljena s kirurško resekcijo in rekonstrukcijo spodnje votle vene z žilno protezo iz PTFE. Po posegu je proteza delno trombozirala, pacientka pa je utrpela tudi delno pljučno embolijo. Zaradi preprečevanja ponavljajočih se pljučnih trombembolij je bil v spodnjo veno kavo vstavljen filter. Pacientka je dvanajst mesecev po posegu brez lokal-

Abstract

Primary leiomyosarcoma of the vena cava is a rare tumor. We describe a 63-year-old female in whom a mass was found upon ultrasonographic examination of the abdomen after persistent pain in the right upper quadrant. CT and MRI revealed a malignant intraluminal growth in the inferior vena cava. Radical resection was undertaken to remove the tumor. The inferior vena cava was reconstructed using a PTFE graft. Resection margins were free of tumor. Postoperative complications included extended thrombosis below the surgical site and smaller pulmonary emboli. A vena-cava filter was inserted to prevent further complications. Twelve months after the first procedure local subcutaneous metastases were observed. Metastases were subsequently removed. We discuss

nega recidiva, pojavljati pa so se pričele lokalne, podkožne metastaze, ki so bile sproti odpravljene. Avtorji ob primeru razpravljajo o možnostih zdravljenje te redke bolezni.

our case to deepen our understanding of this extremely rare disease.

INTRODUCTION

Leiomyosarcoma of the inferior vena cava (IVC) is a very rare neoplasm. Only ≈ 300 cases have been reported (1,2), which makes it a poorly established entity in clinical practice. Hence, an exchange of experiences of successful treatment is important for any surgeon presented with such a case.

Leiomyosarcoma arising in the IVC, although rare, is the most common primary malignancy of the IVC. Clinical findings are non-specific and may precede the diagnosis by several years. Initial symptoms are often absent or are relatively minor. The prognosis of IVC leiomyosarcomas after resection is comparable with that of leiomyosarcomas of other primary origins, such as the stomach, uterus and small bowel (3). Radical resection remains the treatment of choice for primary leiomyosarcomas of the IVC. There is no consensus about the necessity for reconstruction of the vena cava or the efficacy or timing of chemotherapy or radiotherapy (3).

Leiomyosarcomas of the IVC are, in general, classified according to their position in the vena cava (4–6). That is, segment: I (infrarenal); II (inter- and suprarenal): (iii) suprahepatic with potential expansion into the right atrium. They are found most commonly in segment II (40%) (4).

Malignant involvement of large vessels has traditionally been considered a limiting factor for resection of retroperitoneal tumors (7). However advances in surgical methods and postoperative care have made major vascular surgery safe for these patients. In a recent study on 20 patients with leiomyosarcoma of the IVC, a 5-year cumulative survival of 62% was reported with radical surgery and adjuvant multi-

modal therapy (8). However, the role of later options is uncertain because randomized trials focusing on adjuvant and neoadjuvant treatments are lacking due to patient heterogeneity and the rarity of the disease (9).

We describe an unusual case of a leiomyosarcoma of the IVC with emphasis on the surgical procedure and IVC reconstruction.

CASE REPORT

A 63-year-old female presented to her general practitioner with increasing pain in the right upper quadrant. Ten years previously she had her gallbladder removed. An ultrasound study of the abdomen showed a soft tissue mass measuring $\approx 3 \text{ cm} \times 3 \text{ cm}$ at the level of the head of the pancreas reaching up to the common bile duct. Doppler ultrasound showed no blood flow through the mass, making the diagnosis of an abdominal aortic aneurysm unlikely. Differential diagnoses at this point were a pancreatic pseudocyst, duodenal diverticulum and an enlarged lymph node.

The first computed tomography (CT) scan demonstrated the mass to be located at the IVC. The latter was dilated and thrombosed. It could not be determined if the tumor, located coronally at the level of the renal veins, arose from the IVC or retroperitoneum. A computed tomography angiography (CTA) scan showed marked expansion of the tumor inside the vessel (Fig 1). There was no macroscopic infiltration into surrounding tissue. The patient was admitted to the Department of Vascular Surgery at the University Clinical Center in Maribor (Maribor, Slovenia).

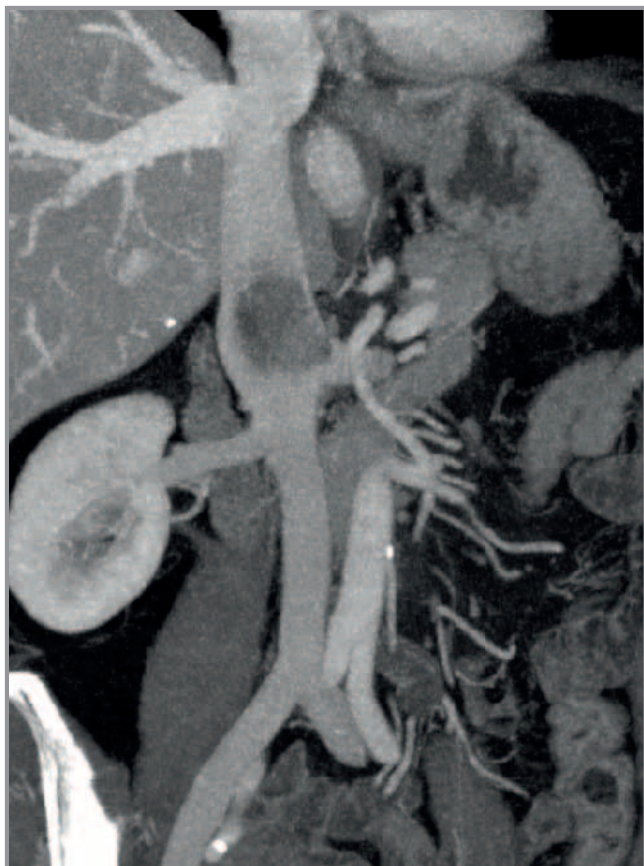

Figure 1. CT image of the growth - height measured in coronal section was 42 mm, volume 15 cm³. The influx of the left and right renal vein is also visible.

The preoperative CT scan, coupled with a magnetic resonance imaging (MRI) scan, confirmed that the tumor, presumably a leiomyosarcoma, was located within the IVC. Due to the location of the tumor in segment II of the IVC and involvement of the left renal vein, a radical resection with vascular prosthetic reconstruction was chosen.

A laparotomy was carried out. After mobilization of the right hepatic lobe and right colic flexure, the tumor was located between the IVC and left renal vein, compressing and infiltrating those vessels. To obtain cranial and caudal control, the IVC was totally exposed and secured with vessel loops. Before clamping of the affected venous segment, the patient received 5000 units of unfractionated heparin. Resection of the IVC, including ≈ 2 cm of the terminal left renal vein, was done and the tumor resected en

bloc with a tumor-free margin of 1 cm. At the time of surgery the mass almost completely filled the lumen of the IVC. The removed segment of the vena cava was replaced and reconstructed with a polytetrafluoroethylene (PTFE graft), into which the left renal vein was anastomosed (Fig 2).

Microscopically, histopathology showed numerous mitotic cells per field upon hematoxylin and eosin (H&E) staining, transmural growth, and infiltration of the adventitia. Additional immunohistochemical examinations (actin, CD34, desmin) confirmed the diagnosis of primary leiomyosarcoma. The tumor was within the resection margins which were negative. Para-aortal lymph nodes were free of tumor cells (Fig 3).

During post-operative recovery, the patient was on anticoagulation therapy with low-molecular-weight heparin (Fraxiparine). After recovery and rehabilitation (10 days), the patient was released into home care. During follow-up, she received low-molecular-weight heparin in therapeutic doses (19,000 anti-Xa IU/mL, 0.6 mL once daily).

Three weeks after surgery, she presented with acute pain in the right lower quadrant that was aggravated by hip flexion. Ultrasonography revealed an extensive phlebothrombosis reaching from the influx of the right renal vein into the IVC down to the right common iliac vein. The right kidney became edematous and subsequently failed due to the thrombosis of the venous outflow system. CT confirmed the extensive thrombosis. The PTFE graft was also partially compressed due to the thrombosis but remained patent, eliminating the need for reparative surgery.

The first line of treatment was intravenous unfractionated heparin followed by low-molecular-weight heparin in therapeutic doses (9,500 anti-Xa IU/mL, 0.6 mL twice daily) and oral anticoagulation therapy (Fraxiparine and Warfarin, respectively) with bed rest and ultrasonographic follow-ups. A target international normalized ratio (INR) of 2–3 was maintained.

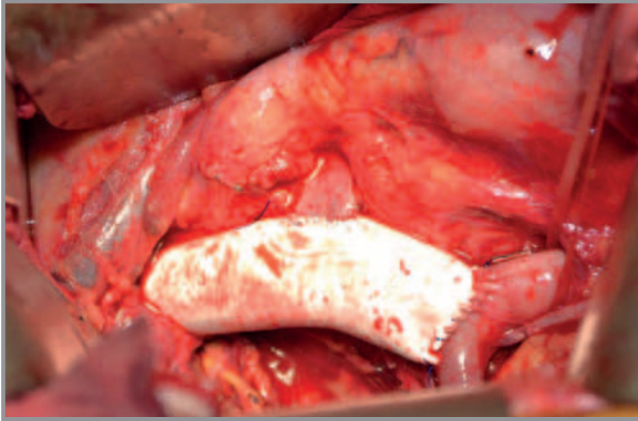


Figure 2. PTFE graft after reconstruction of the IVC; visible anastomosis of the left renal vein.

When the patient first got out of bed after treatment for thrombosis she suffered an amenable pulmonary embolism. Anticoagulation therapy was continued (oral anticoagulation therapy with warfarin and target a INR of 2–3). A temporary vena-cava filter was inserted to prevent further complications.

The patient was referred to an oncologist to plan long-term treatment. After interdisciplinary discussion of the case, the patient received postoperative adjuvant radiotherapy. She received a course targeting the resection bed of the origin of her tumor in the IVC. She was treated with photons of 18 megavolts (MV) at the isocenter at 2 Gray (Gy) per fraction for 25 fractions to a total dose of 50 Gy. The patient tolerated the course of radiotherapy well and reported no side effects.

After 12 months of follow-up, cutaneous masses appeared below the right scapula. Masses were removed surgically and histologic examination showed metastases of the primary tumor. At the time of writing, no additional metastases appeared.

DISCUSSION

Leiomyosarcoma of the IVC is an extremely rare disease. It has been reported primarily as single case reports or small series. Because of limited experience with this disease, the optimal management of

leiomyosarcoma of the IVC is not known. There are also limited reports regarding surgical management of primary IVC tumors and the long-term survival of these patients. One exception is a register established by Mingoli et al. in 1996 in which 218 cases of leiomyosarcoma of the IVC were documented (2). Five-year and 10-year survival with subjects with leiomyosarcoma of the IVC is 38–49% and 14–29%, respectively (6–14). Late diagnosis with metastases complicates surgery and, in general, bears a grave prognosis (13). Despite relatively high survival at 5 years postoperatively, the prevalence of recurrence is $\leq 50\%$, thereby making even radical surgery merely palliative treatment.

Leiomyosarcoma of the IVC most commonly affects women between the ages of 50 years and 60 years (75–90 % of cases) (4). The tumor is frequently asymptomatic for long periods of time, and presents merely as pain in the right upper quadrant in the flank. Common findings include loss of body weight, fever, anorexia, vomiting, night sweats, dyspnea and Budd–Chiari syndrome (4). Edema of the lower extremities can also be present but it is not a standard finding (6).

Leiomyosarcoma of the IVC is most frequently an incidental finding upon abdominal ultrasonography, CT or MRI conducted for other indications (5). Non-specific abdominal pain in the right upper quadrant commonly leads to ultrasound examination (6).

After discovery, further imaging is usually employed to determine the origin and type of the tumor. This helps to evaluate local invasion and exclude metastases while determining the best possible treatment. Metastases are found in fewer than half of patients, and usually occur in the lungs, liver, kidneys, pleura, thoracic wall and bones (10–14). Preoperative percutaneous biopsy is not possible due to the location of the tumor (11). After removal, tissue samples are sent for histopathologic analyses where byresection margins are evaluated and the type of tumor confirmed. Hines et al. stated that positive margins are predic-

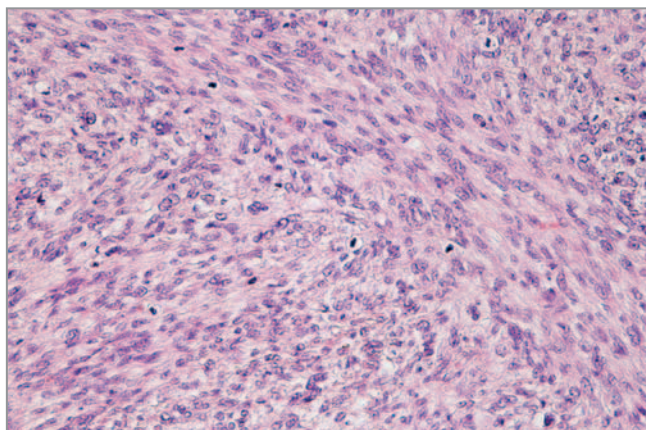


Figure 3. Microscopically visible multiple mitotic cells per field in the center of the tumor. (HE - 200x)

tive of worse survival (13). Aggressive surgical treatment is recommended in light of the slow growth pattern of the tumor and relatively low metastatic potential. Complete surgical resection with a tumor-free margin (1 cm) is the treatment of choice (2).

The International Registry of Inferior Vena Cava Leiomyosarcomas analyzed cohort patients for the predictive factors of clinical outcome. Radical resection was undertaken in 134 (61.5%) patients; 26 (11.9%) had palliative resection, and 58 (26.6%) were inoperable (2). An increased risk of death was associated with involvement of the upper IVC segment ($p < 0.001$), lower-limb edema ($p < 0.001$), Budd-Chiari syndrome ($p < 0.001$), intraluminal tumor growth ($p < 0.001$) and IVC occlusion ($p < 0.001$) (2). Radical resection was associated with better 5- and 10-year survival (49.4% and 29.5%, respectively) compared with patients undergoing palliative resection or those who were inoperable (2). Hollenbeck et al. reported in 2003 that patients undergoing complete resection had 3- and 5-year survival of 76% and 33%, respectively (15).

However, the surgery required for radical resection is challenging (9). The surgical strategy is influenced by the level of the involved caval segment, extent of the retroperitoneal collateral circulation, and by topographic involvement of the neighboring structures. A major issue is the question of IVC recon-

struction. Basically, ligation of the IVC, cavoplasty, and graft replacement represent the major surgical options (9). The IVC can be merely ligated if there is no need for reconstruction due to the extensive collateral circulation, which is a consequence of the slow growth of the tumor and chronic obstruction to venous return (14,15). If infrarenal level 3 of the IVC is affected, simple ligation has been found to yield good functional results (3). However, if extensive curative resection with disruption of the collaterals is done, ligation of the IVC may cause lower-limb edema with significant functional impairment (16,17). If a pararenal leiomyosarcoma of the IVC is present, reconstruction of the IVC and renal veins is necessary to prevent transient or permanent renal dysfunction. In cases of a leiomyosarcoma in segment II, vascular prosthetic reconstruction of the IVC is commonly undertaken to ensure adequate flow through the renal veins (14). Resection of the IVC with prosthetic reconstruction allows for complete resection (with a tumor-free margin of ≥ 1 cm) and provides durable relief from the symptoms of possible venous obstruction. Our patient had a suprarenal leiomyosarcoma with a large intramural and intraluminal mass. Due to the high-grade caval obliteration and suprarenal location of the tumor, complete resection with subsequent graft replacement was carried out. This strategy sustained the physiologic caval blood flow and facilitated reinsertion of the left renal vein. In our patient, unfortunately, the left renal vein became completely thrombosed. Otherwise, the left renal vein can be divided completely and not reconstructed if it is transected proximal to the lumbar vein draining into the posterior aspect of the left renal vein. In these cases, drainage into the azygos-hemiazygos system is undertaken (18).

Some authors suggest that postoperative anticoagulation in patients with a reconstructed IVC should be based on clinical indications and not on the nature of the IVC reconstruction. They recommend anticoagulation therapy in patients with a history of deep vein thrombosis, caval thrombosis, hypercoagulable states, or cardiac indications. Otherwise, all patients having IVC reconstruction should receive antiplate-

let therapy with aspirin. However, long-term results documenting the patency of IVC reconstruction have not been presented (19). Our subject was assessed preoperatively as a high-risk patient for developing deep-vein thrombosis and received low-molecular-heparin in therapeutic doses postoperatively. However, the prescribed anticoagulant therapy could not prevent postoperative thrombosis in the prosthetic graft.

The role of chemotherapy and radiotherapy is not clear, which is true of all retroperitoneal sarcomas in general and leiomyosarcomas of the IVC in particular (20). The use of neoadjuvant therapies is individualized, with few (if any) protocols for this particular subgroup of retroperitoneal sarcomas. Many chemotherapeutic regimens have been tried (particularly anthracycline-based therapies) with no clear improvement in outcome. For example, Hines et al. stated that they routinely administered anthracycline-based adjuvant chemotherapy earlier. They later stopped routine use of chemotherapy, probably because a significant benefit was not apparent (13).

Our patient received adjuvant radiotherapy, which may have improved local outcome but had no influence on metastases.

Current evidence suggests that adjuvant and neoadjuvant treatment does not markedly increase survival, and treatment should be tailored to the specific patient and type of surgery undertaken (13). However, a multidisciplinary study by Kim et al. showed an increase in survival when combining radical resection with adjuvant treatment (21).

CONCLUSION

With primary leiomyosarcomas of the IVC it is crucial to obtain an early diagnosis and undertake appropriate treatment. Aggressive surgical treatment is recommended in light of the slow growth of the tumor and relatively low metastatic potential. Complete resection with a tumor-free margin (1 cm) is the treatment of choice.

REFERENCES

1. Mu D, Wang D, Kefeng Z, Bin Z. Radiographic features of intraluminal leiomyosarcoma of the inferior vena cava: an atypical case report. *Abdom Imaging*, 2011; 36(5): 586–9.
2. Mingoli A, Cavallaro A, Sapienza P, Di Marzo L, Feldhaus RJ, Cavallari N. International registry of inferior vena cava leiomyosarcoma: analysis of a world series on 218 patients. *Anticancer Res*, 1996; 16(5B): 3201–05.
3. Daylami R, Amiri A, Goldsmith B, Troppman C, Schneider PD, Khatri VP. Inferior cava leiomyosarcoma: is reconstruction necessary after reconstruction? *J Am Coll Surg* 2010; 185–90.
4. Bower TC, Stanson A. *Vascular Surgery*, chapter Diagnosis and management of tumours of the inferior vena cava, pages 2077-2092. WB Saunders Company, 2000.
5. Mingoli A, Feldhaus RJ, Cavallaro A, Stipa S. Leiomyosarcoma of the inferior vena cava: analysis and search of world literature on 141 patients and report of three new cases. *J Vasc Surg*, 1991; 14(5): 688–99.
6. Kiefer E, Alaoui M, Piette JC, Cacoub P, Chiche L. Leiomyosarcoma of the inferior vena cava: experience in 22 cases. *Ann Surg*, 2006; 244(2): 289–95.
7. Hardwigsen J, Baque P, Crespy B, Moutardier V, Delpero JR, Le Treut YP. Resection of the inferior vena cava for neoplasms with or without prosthetic replacement: a 14-patients series. *Ann Surg* 2001; 233: 242–9.

8. Ito H, Hornick JL, Bertagnolli MM, George S, Morgan JA, Baldini EH, et al. Leiomyosarcoma of the inferior vena cava. Survival after aggressive management. *Ann Surg Oncol* 2007; 14: 3534–41.
9. Alexander A, Rehders A, Andreas R, Poremba C, Knoefel TW, Eisenberger CF. Leiomyosarcoma of the inferior vena cava: radical surgery and vascular reconstruction. *World J Surg Oncol*, 2009; 7: 56–60.
10. Marinček B. Nontraumatic abdominal emergencies: acute abdominal pain: diagnostic strategies. *Eur Radiol*, 2002; 12(9): 2136–50.
11. Bergauer A, Flis V. Zlohotne novotvorbe velikih žil. *Medicinski mesečnik*, 2007; 2(3): 6–13.
12. Abisi S, Gareth J MS, Scott-Coombes D, Williams IM, Douglas-Jones AG, Malcom CP. Leiomyosarcoma of the inferior vena cava: clinical experience with four cases. *World J Surg Oncol*, 2006; 4: 1–6.
13. Hines OJ, Nelson S, Quinones-Baldrich WJ, Eilber FR. Leiomyosarcoma of the inferior vena cava: prognosis and comparison with leiomyosarcoma of other anatomic sites. *Cancer*, 1999; 85(5): 1077–83.
14. Hardwigsen J, Balandraud P, Ananian P, Sausse J, Le Treut PY. Leiomyosarcoma of the retrohepatic portion of the inferior vena cava: clinical presentation and surgical management in five patients. *J Am Coll Surg*, 2005; 200(1): 57–63.
15. Hollenbeck TS, Grobmeyer SR, Kent KC, Brennan FM. Surgical treatment and outcomes of patients with primary inferior vena cava leiomyosarcoma. *J Am Coll Surg*, 2003; 197(4): 575–9.
16. Yoshidome H, Takeuchi D, Ito H, Kimura F, Shimizu H, Ambiru S, et al. Should the inferior vena cava be reconstructed after resection for malignant tumors? *Am J Surg* 2005; 189: 419–24.
17. du Toit DF, Warren BL. Juxta-renal inferior vena cava leiomyosarcoma. *Eur J Vasc Endovasc Surg*, 2002; 23(1): 84–6.
18. Gonzalez J, Gorin MA, Garcia-Roig M, Ciancio G. Inferior vena cava resection and reconstruction: Technical considerations in the surgical management of renal cell carcinoma with tumor thrombus. *Urologyc oncology: Seminars and original investigations* 2013. <http://dx.doi.org/10.1016/j.urolonc.2013.01.004>.
19. Quinones-Baldrich WJ, Alktaifi A, Eilber E, Eilber F. Inferior vena cava resection and reconstruction for retroperitoneal tumor excision. *J Vasc Surg* 2012; 55: 1386–93.
20. Mann GN, Mann LV, Levine EA, Shen P. Primary leiomyosarcoma of the inferior vena cava: A 2-institution analysis of outcomes. *Surgery* 2012; 151: 261–7.
21. Kim JT, Kwon T, Cho Y, Shin S, Lee S, Moon D. Multidisciplinary treatment and long-term outcomes in six patients with leiomyosarcoma of the inferior vena cava. *J Korean Surg Soc*, 2012; 82(2): 101–9.