

FIRST REPORT OF *Paenibacillus cineris* FROM A BURMESE PYTHON (*Python molurus bivittatus*) WITH ORAL ABSCESS

Hamid Staji^{1*}, Iradj Ashrafi Tamai², Zahra Zeifati Kafi²

¹Department of Pathobiology, Faculty of Veterinary Medicine, Semnan University, Semnan, ²Department of Microbiology, Faculty of Veterinary Medicine, University of Tehran, Tehran, Iran

*Corresponding author, E-mail: hstaji@semnan.ac.ir

Abstract: We report a case of oral abscess caused by *Paenibacillus cineris* in a pet Burmese python. Microbiological and nucleic acid sequencing showed high similarity to the reference strain *P. cineris* (113XG30) isolated in China. Although *Paenibacillus* spp. are environmental bacteria, we highlight the importance of careful consideration of such unusual organisms in exotic reptiles.

Key words: *Paenibacillus cineris*; python; pharyngeal abscess

Introduction

Various published investigations are demonstrating the normal microbiota of the oral cavity in snakes (1-3). For instance, it has been stated that gram positive genera such as *Staphylococcus* and *Corynebacterium* are predominant in the oral cavities of healthy snakes while gram negative genera such as *Pseudomonas* and *Providencia* are mainly predominant in snakes with stomatitis (3). Although snake oral health can be affected by such bacteria, there is not enough documented

data showing rare bacterial agents isolated from snakes with stomatitis. In the present study for the first time, we identified *Paenibacillus cineris* isolated from the abscess contents of a python received from a vet hospital using phenotypic, biochemical and genotypic taxonomic approaches.

Recent advances in molecular typing methods for bacterial taxonomy have enabled microbiologists to a growing appreciation that a variety of rare organisms may also be recovered from the infectious conditions of exotic species. The present study aimed to describe the recovery of *Paenibacillus cineris* from an abscess in a python with head swelling.

Case description

A previously healthy python (male, weighting 27.5 kg) presented with respiratory problems and dysphagia for about a week, progressive restlessness and swelling around the oral cavity, was referred to the pet hospital of the faculty of veterinary medicine (University of Tehran, Iran). At the physical examination, an abscess about 2 cm in diameter located in the tissues in the back of the throat behind the posterior pharyngeal wall was observed. To remove the infection and prevent complications it was decided to drain and extract the abscess. For this purpose, the snake was anesthetized by intramuscular (IM) injection with ketamine medicine (KETAMINA MOLTENI, Italy; 20 mg/kg). Then, the surgical site was disinfected with 1.0% chlorhexidine and sterile 0.9% saline (4) and interior fluid and caseous pus contents were extracted for microbiological assessments. Analgesics should be used each time when the animals are subjected to painful sensations. Unfortunately, the knowledge of pain perception in snakes is quite limited. Mitchell et al. (2009) recommended using of pain relieving agents such as butorphanol (0.5 1 mg/kg IM), carprofen (2-4 mg/kg IM, PO) and meloxicam (0.5 mg/kg PO). Thus, for analgesic purposes and less stress induction to the animal, meloxicam (ABURAIHAN, Iran; 0.5 mg/kg PO, once after operation) was administered. After operation, the python was fed every 4 days by mice pinkies soaked in warm chicken broth by using feeding forceps.

Microbiological identification of pathogenic agent

The isolation and identification of the pathogen agent was carried out according to the protocols described by Leão et al. (5) and Sáez-Nieto et al. (6) respectively. Briefly, the aspirated pus sample was plated on Columbia agar with 5% defibrinated sheep's blood and Mac Conkey agar for 24 to 48 hours in the aerobic atmosphere at 37°C. After overnight incubation, yellow colonies with irregular edges and mucoid appearance were observed on enriched Columbia agar and there was no growth on Mac Conkey selective agar. Microscopic examination of colonies showed Gram-negative sporulated bacilli, and some endospores were demonstrated. The isolate was assessed by further biochemical and phenotypic tests as described in Table. 1.

Molecular identification of Paenibacillus spp. based on partial sequencing of 16S rRNA

Genomic DNA extraction was carried out on colonies microbiologically suspected to *Paenibacillus* spp. by using an alkaline lysis method (7). Then, extracted genomes were subjected to PCR for amplification of a 900-1000 bp fragment of 16S rRNA belonging to the genus *Paenibacillus*. Identification and amplification of 16S rRNA were carried out using universal primer pairs (8).

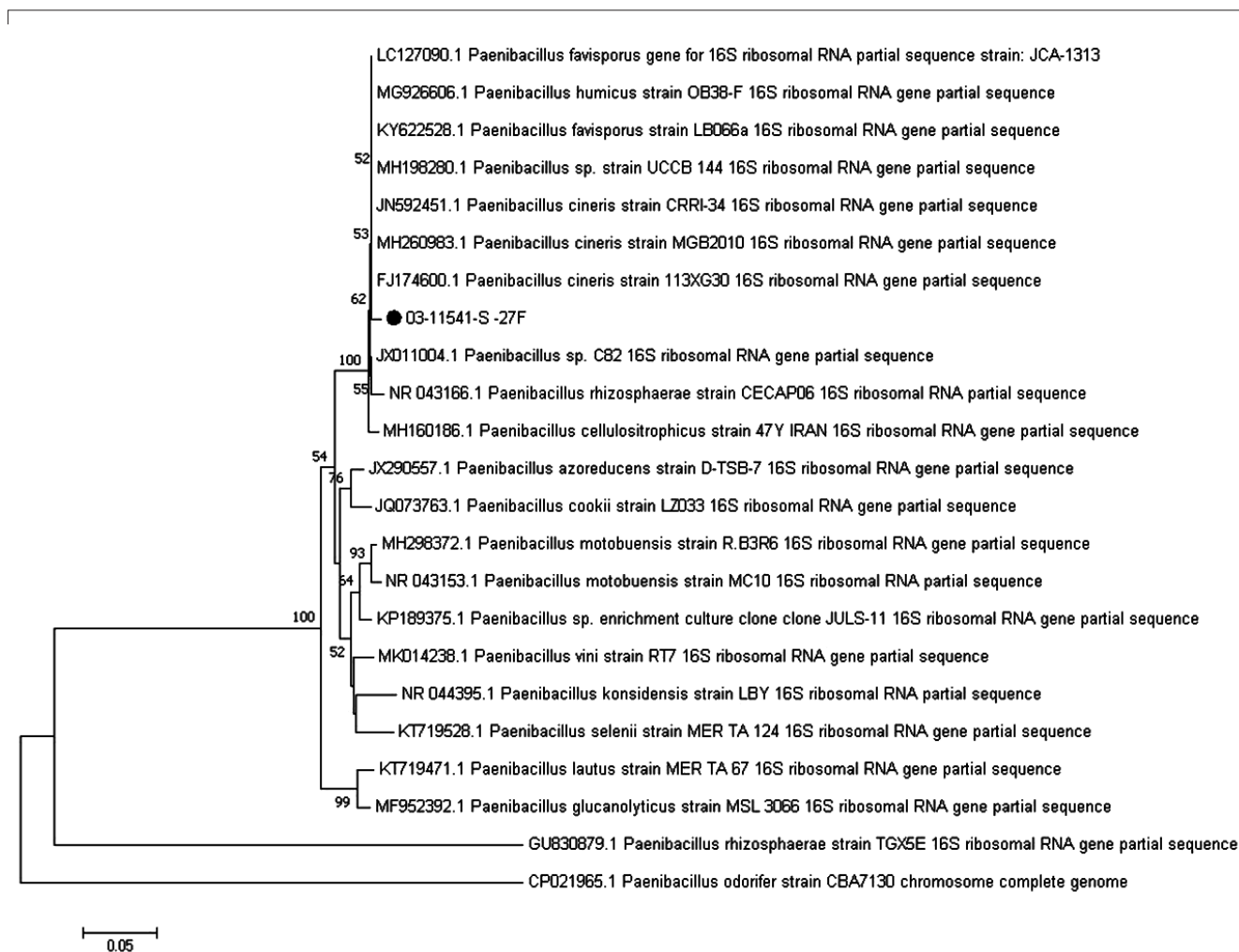
The nucleotide sequence of the amplified fragment was analyzed with an ABI 3730XL DNA Analyzer according to an automated Sanger dideoxy fluorescent nucleotide method and the obtained sequence was deposited in GenBank with accession number: MT158489. Then, the BLAST software was applied to determine the homology of the amplified fragment to DNA sequences existing in GenBank and the phylogenetic tree was constructed by the neighbor-joining model in MEGA-6.

Antimicrobial susceptibility

According to the previous antimicrobial susceptibility profiles of *Paenibacillus* spp. (5-6), eleven antimicrobials (PADTAN TEB Company, Iran) including imipenem (10 µg), ampicillin (10 µg), penicillin (10 µg), polymixin B (300 µg), trimethoprim sulfamethoxazole (75 µg), cefotaxime (30 µg), enrofloxacin (5 µg), erythromycin (15 µg), gentamicin (10 µg), rifampicin (5 µg), and vancomycin (30 µg) were examined for susceptibility assessments on Mueller-Hinton agar enriched with sheep's defibrinated blood. Disc diffusion (Kirby-Bauer) test was performed on the isolate for antimicrobial susceptibility evaluations. Briefly, a suspension of the isolate (of approximately $1-2 \times 10^8$ CFU/mL) was prepared to a 0.5 McFarland standard, then spread evenly onto Mueller-Hinton agar in the Petri dish and the mentioned discs were placed onto the surface of the agar. Then, after overnight incubation zones of growth inhibition around each of the antibiotic discs were measured to the nearest millimeter. The interpretation of results were based on the clinical and laboratory standards institute (CLSI) guidelines.

Table 1: Phenotypic and biochemical characteristics of *Paenibacillus* isolate from a pet python. Adapted from Leão et al. [5] and Logan et al. [9]. ONPG = O-nitrophenyl- β -D-galactopyranoside; PYR = pyrrolidiny- β -naphthylamide

Tests	Results	Tests	Results
Gram stain	Gram-negative sporulated bacilli	Esculin	+
Oxidase	+	Urea	-
Motility	+	ONPG	+
Oxidation of Glucose	-	PYR	+
Xylose	-	Growth on Mac Conkey	-
Maltose	-	42 °C	+
Sucrose	-	Citrate agar	-
Lactose 10%	-	NaCl (6.5%)	-
Lysine decarboxylase	-	NaCl (0%)	+
Ornithine decarboxylase	-	Production of H ₂ S	-
Arginine dihydrolase	-	Indole	-
Hydrolysis of Gelatin	-	Nitrate reduction	+
DNase activity	-	Gas from nitrate	+

**Figure 1:** Neighbor-Joining phylogenetic tree based on the 16S rRNA gene sequence of *Paenibacillus* spp. *Note:* the marked Latin name (03-11541-S-27F) represents the isolate in this study. The codes before the Latin names are GenBank accession numbers for each type strain. Numbers at nodes are percentages of bootstrap values and scale bar indicates 0.05 nucleotide sequence divergence

Results

According to the phenotypic and microbiological criteria, the bacterial isolate from snake's abscess secretions was found to be a *Paenibacillus* spp. All the microbiological results of the isolate are presented in the Table. Our findings concerning the microbiological characteristics of the isolate are consistent with the type strains *P. cineris* from previous publications (5, 9).

Sequence analysis of a partial fragment of the 16S rRNA gene amplified from the isolate (MT158489) demonstrated a high similarity level with the *P. cineris* strain 113XG30 deposited in Gene Bank with accession no. FJ174600.1. The neighbor-joining phylogenetic tree of our study

indicates the position of our isolate and its identity with the type strains of *P. cineris* and other closely related species (Figure).

Antimicrobial sensitivity testing results belonging to the *Paenibacillus* isolate in the present study are shown in Table 2. In summary the isolate showed resistance to ampicillin, penicillin, erythromycin, and gentamicin while sensitivity was observed to the rest of tested antimicrobials. Trimethoprim-sulfadimethoxine was administered 20 mg/kg (IM, q24h) for 10 days with the use of a pole syringe (4). Two weeks after the end of the antibiotic therapy, abscess lesions and head swelling signs showed complete treatment and the python recovered completely.

Table 2: Zone diameter observed related to the *P. cineris* isolate and interpretative standards for used antimicrobial disks

	Zone Diameter Interpretive Criteria		Observed zone of inhibition (mm) concerning the <i>P. cineris</i> isolate
	Resistant (R)	Susceptible (S)	
imipenem	≤ 20	28 ≤	31
ampicillin	≤ 12	16 ≤	8 (R)
penicillin	≤ 27	28 ≤	14 (R)
polymixin B	≤ 14	18 ≤	20
Trimethoprim-sulfamethoxazole	≤ 10	16 ≤	22
cefotaxime	≤ 25	31 ≤	31
enrofloxacin	≤ 22	30 ≤	33
erythromycin	≤ 13	23 ≤	9 (R)
gentamicin	≤ 12	15 ≤	11 (R)
rifampicin	≤ 16	20 ≤	28
vancomycin	≤ 17	21 ≤	24

Discussion

More than twenty strains belonging to *Paenibacillus* genus are recognized as responsible for true infections or transient infections colonizing blood and other human sources, or as a possible contamination occurring during the process of obtaining the sample (6). Since 1989, the number of reports regarding clinical infections in human cases including brain abscesses after contusion, neonatal meningitis, lung diseases, bacteremias, urinary tract infection and endophthalmitis caused by the *Paenibacillus* spp. have increased (5, 10-16). In veterinary medicine, *Paenibacillus*

larvae is known as the causal agent of American Foulbrood (AFB) disease in honey bees (17).

Although, *Paenibacillus* spp. can be truly pathogen, but reports concerning the prevalence of these bacteria in clinical samples in medicine and veterinary medicine are limited and this may be related to the fact that such bacteria are considered to be contaminants of clinical specimens (5, 6).

Paenibacillus cineris is a part of the inhabitant microflora of a variety of sources such as soil, water, food, plants and sediments (6). To the best of our knowledge, this is the first report of *P. cineris* recovered from a reptile and there is no

other report regarding the infection caused by this species in animals. *Paenibacillus* spp. may cause infections via indigenous route or can enter the host body after trauma (18). The infection by *P. cineris* observed in this study in the oral cavity of a python kept as a pet animal could have been triggered by mechanical injuries that occurred during feeding or as a result of aggressive behaviors. Although, the role of *Paenibacillus* spp. in reptiles diseases is unknown this study highlights the potential pathogenic ability of *P. cineris* in snakes. So, further consideration should be given to the epizootiology of rare microorganisms in reptiles and the implication of *P. cineris* in the evaluation of the snake's infectious conditions.

Acknowledgments

The authors thank University of Tehran clinical staffs for their help in sampling and recovering the python and microbiology department technicians for their help in bacteriological identification of *P. cineris* isolate.

This research did not receive any specific grant from funding agencies in the public, commercial, or not-for-profit sectors.

References

1. Dehghani R, Sharif MR, Moniri R, Sharif A, Kashani HH. The identification of bacterial flora in oral cavity of snakes. *Comp Clin Pathol* 2016; 25(2): 279–83. doi:10.1007/s00580-015-2178-9
2. Fonseca MG, Moreira WM, Cunha KC, Ribeiro AC, Almeida MT. Oral microbiota of Brazilian captive snakes. *J Venom Anim Toxins Incl Trop Dis* 2009; 15(1): 54–60. doi:10.1590/S1678-91992009000100006
3. Jho YS, Park DH, Lee JH, Cha SY, Han JS. Identification of bacteria from the oral cavity and cloaca of snakes imported from Vietnam. *Lab Anim Res* 2011; 27(3): 213–7. doi:10.5625/lar.2011.27.3.213
4. Mitchell MA. Snake care and husbandry. *Vet Clin North Am Exot Anim Pract* 2004; 7: 421–6.
5. Leão RS, Pereira RH, Ferreira AG, et al. First report of *Paenibacillus cineris* from a patient with cystic fibrosis. *Diagn Microbiol Infect Dis* 2010; 66(1): 101–3. doi:10.1016/j.diagmicro.2009.06.011
6. Sáez-Nieto JA, Medina-Pascual MJ, Carrasco G, et al. *Paenibacillus* spp. isolated from human and environmental samples in Spain: detection of 11 new species. *New Microbes New Infect* 2017; 19: 19–27. doi: 10.1016/j.nmni.2017.05.006
7. Staji H, Rassouli M, Jourablou S. Comparative virulotyping and phylogenomics of *Escherichia coli* isolates from urine samples of men and women suffering urinary tract infections. *Iran J Basic Med Sci* 2019; 22(2): 211–4. doi:10.22038/ijbms.2018.28360.6880
8. Shida O, Takagi H, Kadowaki K, Nakamura LK, Komagata K. Transfer of *Bacillus alginolyticus*, *Bacillus chondroitinus*, *Bacillus curdlanolyticus*, *Bacillus glucanolyticus*, *Bacillus kobensis*, and *Bacillus thiaminolyticus* to the genus *Paenibacillus* and emended description of the genus *Paenibacillus*. *Int J Syst Bacteriol* 1997; 47(2): 289–98. doi:10.1099/00207713-47-2-289
9. Logan NA, De Clerck E, Lebbe L, et al. *Paenibacillus cineris* sp. nov. and *Paenibacillus cookii* sp. nov., from Antarctic volcanic soils and a gelatin-processing plant. *Int J Syst Evol Microbiol* 2004; 54(4): 1071–6. doi: 10.1099/ijms.0.02967-0
10. Bert F, Ouahes O, Lambert-Zechovsky N. Brain abscess due to *Bacillus macerans* following a penetrating periorbital injury. *J Clin Microbiol* 1995; 33(7): 1950–3.
11. Lo CI, Sankar SA, Fall B, et al. High-quality genome sequence and description of *Paenibacillus dakarensis* sp. nov. *New Microbes New Infect* 2016; 10: 132–41. doi: 10.1016/j.nmni.2016.01.011
12. Marchese A, Barbieri R, Pesce M, Franchelli S, De Maria A. Breast implant infection due to *Paenibacillus residui* in a cancer patient. *Clin Microbiol Infect* 2016; 22(8): 743–4. doi: 10.1016/j.cmi.2016.05.012
13. Ouyang J, Pei Z, Lutwick L, et al. *Paenibacillus thiaminolyticus*: a new cause of human infection, inducing bacteremia in a patient on hemodialysis. *Ann Clin Lab Sci* 2008; 38(4): 393–400. PMC2955490
14. Rieg S, Bauer TM, Peyerl-Hoffmann G, et al. *Paenibacillus larvae* bacteremia in injection drug users. *Emerg Infect Dis* 2010; 16(3): 487–90. doi: 10.3201/eid1603.091457
15. Sharma S, Gupta A, Rao D. *Paenibacillus lautus*: a rare cause of bacteremia and review of the literature. *Indian J Med Case Rep* 2015; 4(2): 56–9.
16. Yoon HJ, Yim HW, Ko KS. A case of *Paenibacillus pasadenensis* bacteremia in a patient with acute respiratory distress syndrome after mi-

crossurgical clipping. *J Infect Chemother* 2015; 47(1): 64–7. doi: 10.3947/ic.2015.47.1.64

17. Antúnez K, Anido M, Arredondo D, Evans JD, Zunino P. *Paenibacillus larvae* enolase as a virulence factor in honeybee larvae infection. *Vet Microbiol* 2011; 147(1/2): 83–9. doi: 10.1016/j.vetmic.2010.06.004

18. Park SN, Lim YK, Shin JH, et al. *Paenibacillus oralis* sp. nov., isolated from human subgingival dental plaque of gingivitis lesion. *Curr Microbiol* 2019; 12: 1–7. doi: 10.1007/s00284-019-01843-0

PRVO POROČILO O OSAMITVI *Paenibacillus cineris* IZ BURMANSKEGA PITONA (*Python molurus bivittatus*) Z ORALNIM ABSCESOM

H. Staji, I. A. Tamai, Z. Z. Kafi

Izvešček: V članku je opisan primer oralnega abscesa, ki ga je povzročila bakterija *Paenibacillus cineris* pri hišnem burmanskem pitonu. Mikrobiološko in nukleinsko kislinsko zaporedje je pokazalo visoko podobnost z referenčnim sevom *P. cineris* (113XG30), izoliranim na Kitajskem. Čeprav spada *Paenibacillus spp.* med okoljske bakterije, lahko takšni neobičajni mikroorganizmi pri eksoičnih plazilcih povzročajo tudi zdravstvene težave in jim moramo posvečati pozornost.

Ključne besede: *Paenibacillus cineris*; piton; žrelni absces