

## Treating a patient with lower limb injury from shark attack – a case report

Zdravljenje poškodovanca s poškodbo spodnje okončine v napadu morskega psa – klinični primer

Uroš Ahčan,<sup>1</sup> Vedran Radonić,<sup>2</sup> Anže Militarov,<sup>3</sup> Manja Leban<sup>1</sup>

<sup>1</sup> Department of Plastic, Reconstructive and Aesthetic Surgery and Burns Unit, University Clinical Centre Ljubljana, Zaloška cesta 2, 1525 Ljubljana, Slovenia

<sup>2</sup> Department of Surgery, Clinical Hospital Split, Ulica Vjekoslava Spinčića 1, 21000 Split, Croatia

<sup>3</sup> Department of Surgery, General Hospital Jesenice, Cesta maršala Tita 112, 4270 Jesenice, Slovenia

### Korespondenca/ Correspondence:

Uroš Ahčan, MD, PhD, professor, Head of Department of Plastic, Reconstructive and Aesthetic Surgery and Burns Unit, University Clinical Centre Ljubljana, Zaloška cesta 2, 1525 Ljubljana, Slovenia, uros.ahcan@gkclj.si

Anže Militarov, MD, Department of Surgery, General Hospital Jesenice, Cesta maršala Tita 112, 4270 Jesenice, Slovenia, anze.militarov@gmail.com

### Izvleček

**Izhodišča:** Vsako leto po vsem svetu zabeležijo več napadov morskih psov na ljudi, vendar so smrtni izidi redki. Povprečno število napadov morskih psov po vsem svetu je bilo v zadnjih letih 67 na leto, od tega je bilo v povprečju 5 smrtnih. V Jadranskem morju so napadi morskih psov zelo redki.

**Prikaz primera:** V prispevku predstavljamo napad belega morskega psa iz leta 2008 v Jadranskem morju, pri katerem je žrtev utrpela hudo poškodbo spodnjega uda z obsežno krvavitvijo, ki je vodila v hemoragični šok.

**Zaključek:** Hiter odziv zdravniške ekipe na mestu dogodka in vzorno sodelovanje ekip v dveh bolnišnicah iz sosednjih držav, Slovenije in Hrvaške, je rešilo življenje nenavadno poškodovanega bolnika in omogočilo dober končni funkcionalni rezultat.

### Abstract

**Background:** Every year a number of people are attacked by sharks worldwide; however, death as a consequence is quite unusual. In recent years, the number of reported shark attacks worldwide has been around 67 per year with fatalities averaging 5 persons annually. Shark attacks in the Adriatic Sea are very rare.

**Case report:** In 2008, a great white shark attack happened in the Adriatic Sea, in which a man suffered a severe injury to his lower extremity and profuse bleeding that led to haemorrhagic shock.

**Conclusion:** The expeditious intervention at the site of attack and the exemplary cooperation of medical teams in two centres in the neighbouring countries of Croatia and Slovenia has saved the life of the unusually injured patient and resulted in a satisfactory functional outcome.

## Introduction

Out of more than 360 shark species (8 orders and 31 families) only 3 species have been reportedly involved in a significant number of attacks on humans: the great white shark, tiger shark and bull shark.<sup>1</sup>

Since year 2000, the mean number of shark attacks worldwide has been 67.25 per year, the highest being 89 in 2000 and the lowest 52 in 2008. The mean number of fatal

attacks in the same period was 5.5 per year (6.1%). Statistics show that the number of shark attacks worldwide has been growing at a steady pace and that each decade has more attacks than the previous one, which correlates with the increasing amount of time humans spend in the sea due to the growing popularity of water sports.<sup>2</sup>

**Ključne besede:**

ugrizna rana;  
nekrektomija; kožni  
presadek; terapija z  
negativnim tlakom;  
hiperbarična kisikova  
terapija

**Key words:**

bite wound; debridement;  
skin grafting; vacuum-  
assisted closure;  
hyperbaric oxygen  
therapy

**Citirajte kot/Cite as:**

Zdrav Vestn 2014;  
83: 85–90

Prispelo: 27. dec 2012,  
Sprejeto: 29. apr. 2013

In 2011, the majority of attacks occurred in the waters of the USA (26), less in Australia (11), South Africa (5), Reunion (4), Indonesia (3), Mexico (3), Russia (3), the Seychelles (2), Brazil (2) and open sea (2), with single incident reports from a number of other countries, totalling to 75 cases, of which 12 (16 %) were fatal. Groups most often involved in shark attacks were surfers (60 % of cases), followed by swimmers/waders (35 % of cases) and divers (5 % of cases).<sup>2</sup>

In the Adriatic Sea, 28 shark species have been recorded, classified into 5 orders, 14 families and 25 genera.<sup>3</sup> According to data provided by the Marine Biology Station in Piran, Slovenia, there have been 20 shark attacks on humans in the Adriatic Sea reported since 1868 and out of them 12 were fatal. Prior to the incident reported in this paper, the last report of a shark attack in the Adriatic Sea was from 1974.

**Case report**

In October 2008, a great white shark attacked a 43-year-old male in the waters of Vis Island, Croatia. The victim, an experienced spear fisherman, suffered a severe injury to his left calf.

After the attack, the victim's fellow divers pulled him out of the water and onto the boat, provided first aid by using a spearfishing belt for improvised bandage and called the emergency medical team. The team arrived shortly after and applied Esmarch bandage to the victim's left thigh, which stopped

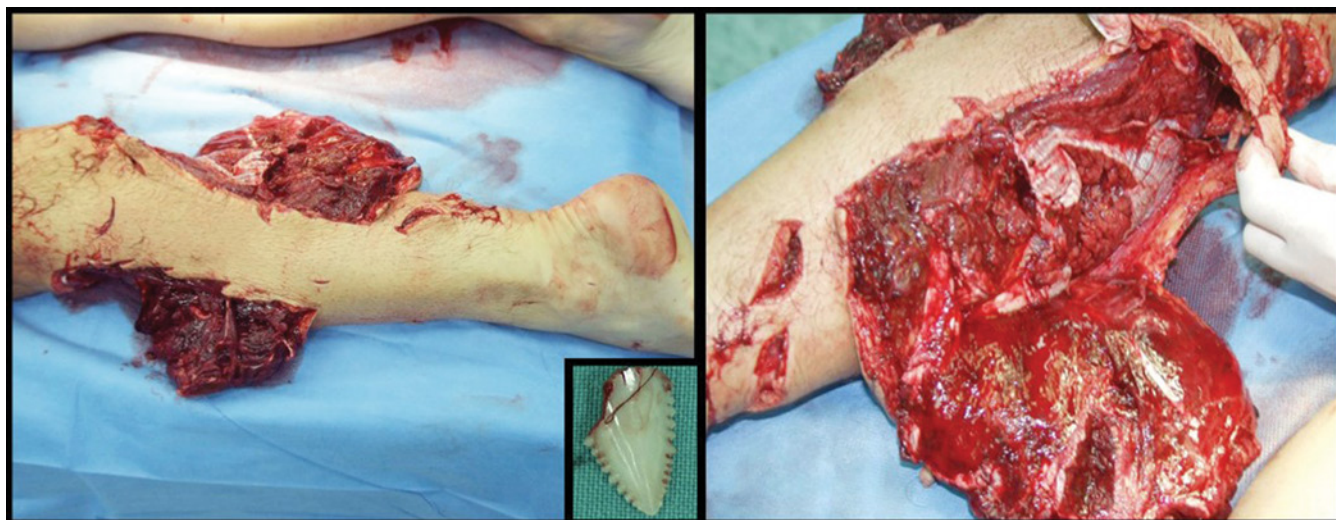
bleeding from the injured calf of the left leg. The wounds were bandaged, an infusion of saline was started and analgesics were administered. The patient was transported by helicopter to the Clinical Centre Split, located 75 km away.

On arrival to the emergency department about 3 hours after the incident, the patient was in haemorrhagic shock. Physical examination revealed an extensive bite wound in the posterior part of the left calf involving muscle, subcutaneous tissue and skin. Large parts of the gastrocnemius and soleus muscles were vigorously destroyed (Fig. 1). Dorsiflexion of the left foot was absent but there were no sensory deficits on the calf and foot. Pulses of a. tibialis posterior and a. dorsalis pedis were present.

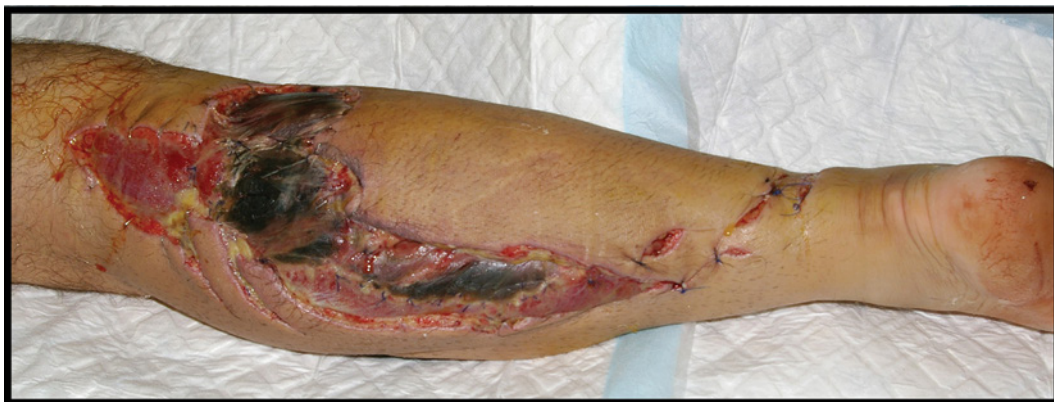The patient was stabilised with plasma expanders and blood transfusions. Angiography of the left lower extremity showed that all three arteries of the calf were opacified by contrast medium but were markedly thinned in the distal part. Profuse venous bleeding from the posterior, muscular part of the calf was visible and a haematoma developed. No bone injuries were found. Many hyperdense foreign bodies were visualized in the wound, measuring from a few millimetres to about 4 centimetres.

Surgical procedure under general anaesthesia followed. Revision in bloodless field was performed with subsequent debridement of nonviable tissues. Foreign bodies that were later identified as shark teeth and particles of the victim's neoprene clothing

**Figure 1:** Extent of injuries on the victim's left calf, caused by a shark bite. Shark teeth were removed from the wound.



**Figure 2:** The wound four days after the injury.



were removed from the wound. Judging from the size of the removed teeth (Fig. 1), the shark's size was estimated to be approximately 3 meters. Fasciotomy in the posterior and anterolateral region of the calf was performed. The fibular artery was found to be lacerated at many sites and was ligated, lesions of the fibular vein were also repaired. Deep peroneal nerve was found severe damaged and was reconstructed by epineural sutures. The medial and lateral gastrocnemius and soleus muscles were also reconstructed. A passive drainage tube was placed in the deep posterior compartment of the injured calf. The wounds were left widely open to prevent development of infection and to allow for outer drainage. After the operation, a plaster cast with posterior opening was placed below the knee.

Perioperatively the patient was treated with parenteral crystalloid penicillin (4.000.000 units), metronidazole 500 mg and gentamicin 240 mg. The patient also received antitetanic vaccination, low molecular weight heparin (LMWH) in protective doses, proton pump inhibitor (PPI) pantoprazole and analgesics.

After surgical intervention, hyperbaric oxygen therapy was started with the aim of maximizing tissue oxygenation and preventing infection in order to save the deprived tissues. All sessions were held at 100 % oxygen with a pressure of 2.8 bar for two rounds of 30 minutes with a 5 minute pause in between.<sup>4</sup> They were held daily for five days.

During the first 4 days the patient was hospitalised in the Department of Vascular Surgery of the Clinical Centre Split and was treated daily with metronidazole 3x500 mg and gentamicin 240 mg administered intra-

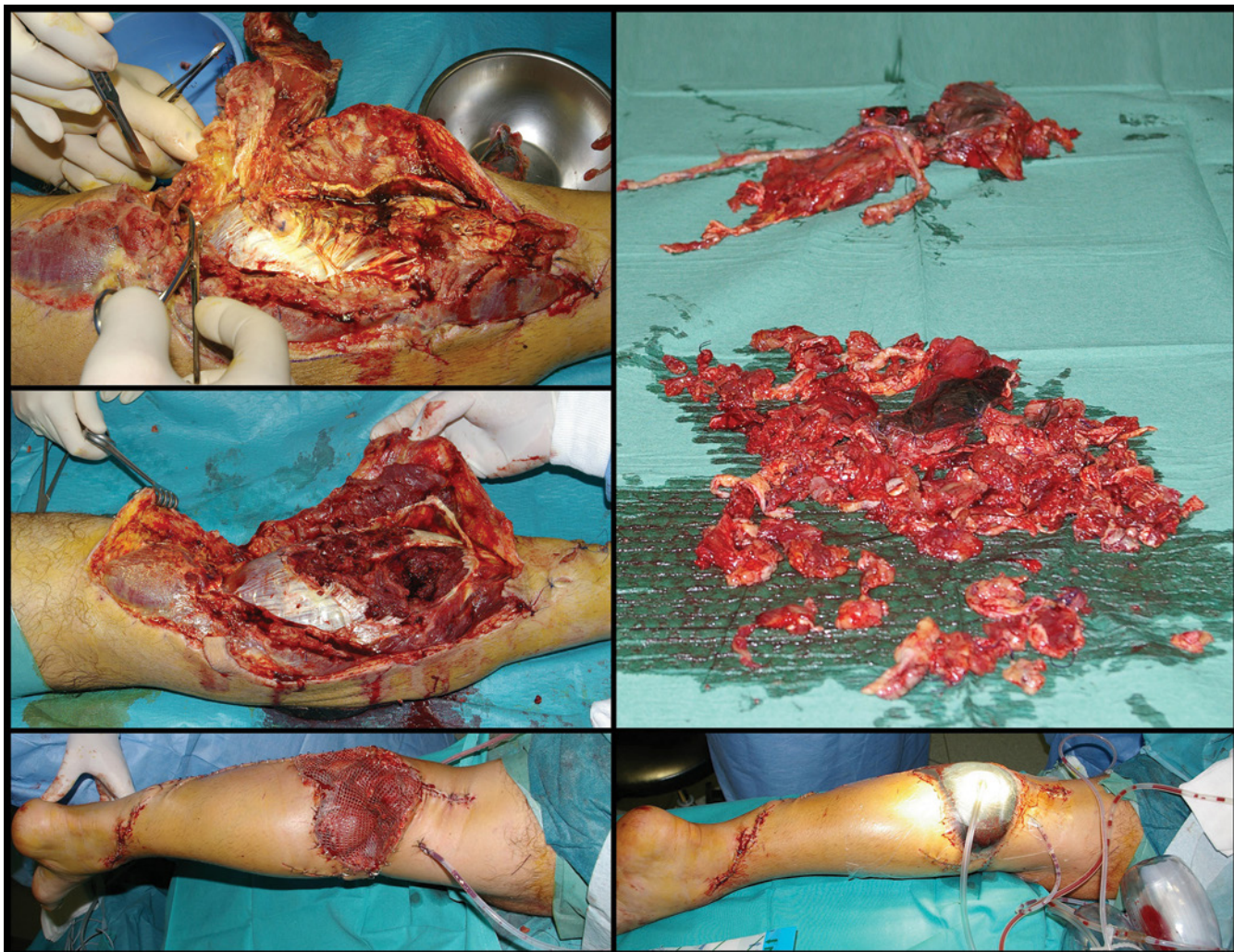
venously. Transfusions of blood and plasma, as well as infusions of albumins were needed to correct the loss of blood volume. Applications of LMWH in protective doses were continued, as well as analgesics and PPI. Regular daily dressings were performed.

The patient's wish was to continue treatment in his home country, so on the fifth day after the injury he was transferred to the Department of Plastic and Reconstructive Surgery of the University Medical Centre Ljubljana, Slovenia.

On arrival to the hospital in Ljubljana the patient was haemodynamically stable and was complaining about moderate pain in the injured leg. He had no fever, but there were local signs of infection with swelling, redness and unpleasant smell from necrotic fascia and muscles in the widely open wounds of the injured calf. Signs of deep peroneal palsy were clearly present. Laboratory findings showed elevated CRP levels (188 mg/L), anaemia (Hb 102 g/L, Ht 0.28 %) and elevated myoglobin level (462 µg/L). No leukocytosis was found and all other routine laboratory measurements were normal.

Blood samples were taken for haemoculture and the results came back negative. *E. coli* was isolated from the wound and proved sensitive to the prescribed antibiotics. After consultation with an infectious disease specialist, cefatrizine 2g/8h intravenously was started. Dressings were performed regularly. Despite the aggressive antibiotic therapy, the wound showed signs of progressive infection with more swelling, pain and necrosis of deep tissues (Fig. 2). Laboratory findings, however, showed a decline in inflammatory parameters with CRP level dropping to 93 mg/L and no leukocytosis.





**Figure 3:** Wound revision was conducted eight days after the injury (top left). The operation consisted of radical necrectomy (middle left and top right) with subsequent covering of skin defects with split-thickness skin grafts (bottom left) and application of Vacuum Assisted Closure device (bottom right).

Eight days after the injury, the decision to perform an additional surgery was made (Fig. 3). Radical necrectomy (mainly of fascial and muscular tissue) was carried out and drainage tubes were placed under the remaining gastrocnemius muscle. A split-thickness skin graft (Tiersch graft) was taken from the left thigh to cover skin defects. During the operation, a swab of the wound was taken and later microbiological examination showed contamination with *A. Baumannii* and *E. coli*, both of which were sensitive to the prescribed antibiotics. At the end of the operation, a Vacuum Assisted Closure (VAC) system was applied to cover the meshed skin graft and set to a pressure of 100 mmHg.<sup>5</sup>

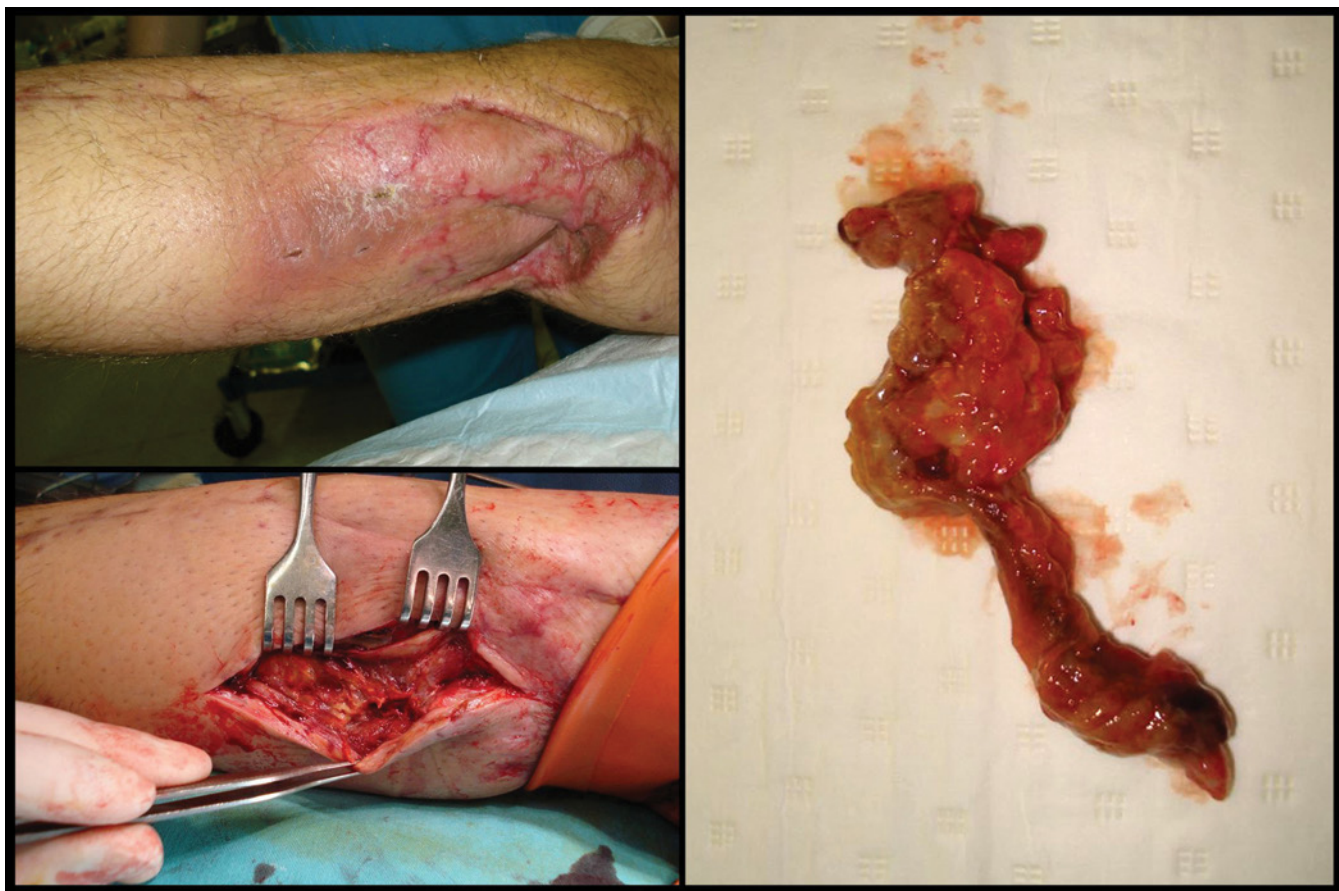The prescribed antibiotic, antithrombotic and analgesic therapy was continued. Dressings were performed daily and the infection showed clear signs of regression.

Postoperative laboratory findings, including inflammatory parameters, gradually decreased to normal values.

Physiotherapy was started the day after the second operation: the patient was allowed to sit and passive exercises for dorsiflexors of the foot were performed daily to prevent contracture of the ankle.<sup>6</sup>

Eight days after the second surgery, an infectious disease specialist was consulted again and according to his recommendations the antibiotic therapy was discontinued since there were no systemic or local signs of infection. Drainage tubes and VAC system were removed. Wound healing was proceeding well; there was no evidence of swelling, pain or redness. The patient started to walk with crutches. There were signs of deep peroneal nerve palsy with characteristic foot drop. A custom-built foot splint was placed





**Figure 4:** 108 days after the injury – surgical revision with additional necrectomy of subcutaneous tissue.

and regular passive exercises were prescribed.

Nineteen days after the injury the patient was discharged from hospital in good general condition, able to walk independently with crutches and with no signs of local infection. He visited our outpatient clinic for regular check-ups and was referred to physiotherapy. He was given a shorter peroneal brace with corrected angle. Lymphatic drainage was performed and stretching exercises for ankle were continued.

A month later, slight secretion from the wound was noted. Wound swabs were taken and MRSA was isolated. An infectious disease specialist prescribed oral sulfamethoxazole/trimethoprim 800/160 mg every 6 hours.

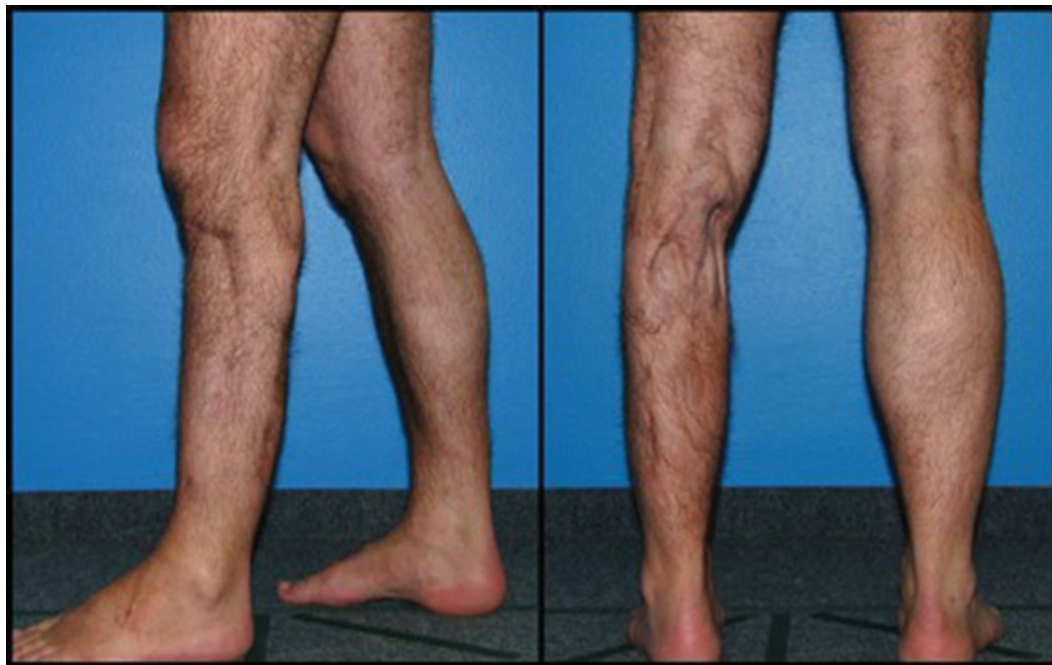Subcutaneous fluid collection was also noted. The patient was re-hospitalized and on the following day a surgical revision of the wound was performed, including nec-

rectomy of the subcutaneous tissue and drainage tube placement (Fig. 4). Wound swabs and a tissue sample that were taken during the operation were sent for microbiological examination and the results came back negative for both aerobic and anaerobic bacteria.

After this operation, the wound healed uneventfully with no signs of local infection or secretion as we continued to follow the patient regularly in our outpatient clinic (Fig. 5). He was referred to continue physiotherapy because of peroneal palsy and he learned to walk with the assistance of a drop foot splint. Some degree of the typical signs of peroneal palsy persisted.

The patient made a lot of effort to adapt well to his disability, both psychologically and physically. He returned back to normal life and is again able to engage in sporting activities and spear fishing.

**Figure 5:** The end result about 1 year after the injury.



## Conclusion

The aim of this article was not to promote new approaches or inventions in medical treatment but to present a rare type of injury, especially in European medicine. Prompt first aid, intervention of local medical team

and subsequent exemplary cooperation and complex treatment in two medical centres, Split and Ljubljana, that included anaesthesiologists, surgeons, hyperbaric medicine specialists and physiotherapists, saved the life of a patient and resulted in a reasonably good functional and aesthetic outcome.

## References

1. Florida Museum of Natural History. Ichthyology. Available at: <http://www.flmnh.ufl.edu/fish/sharks/attacks/howwhen.htm>
2. Florida Museum of Natural History. International Shark Attack File: 2011 Summary. Available at: <http://www.flmnh.ufl.edu/fish/sharks/isaf/2011summary.html>.
3. Lipej L, De Maddalena A, Soldo A. Sharks of the Adriatic Sea. Koper: Univerza na Primorskem, Znanstveno-raziskovalno središče: Zgodovinsko društvo za južno Primorsko; 2004. p. 199.
4. Bouachour G, Cronier P, Gouello JP, Toulemonde JL, Talha A, Alquier P. Hyperbaric Oxygen Therapy in the Management of Crush Injuries: A Randomized Double-Blind Placebo-Controlled Clinical Trial. *J Trauma* 1996; 41(2): 333–9.
5. Argenta LC, Morykwas MJ. Vacuum-assisted closure: a new method for wound control and treatment: clinical experience. *Ann Plast Surg* 1997; 38(6): 563–76; discussion 577.
6. de Bruijn IL, Geertzen JH, Dijkstra PU. Functional outcome after peroneal nerve injury. *Int J Rehabil Res*. 2007; 30(4): 333–7.