

THE OCCURRENCE OF CORTICOTROPHINOMA IN CROSS-BREED AND BREED DOGS

María Florencia Gallelli¹, Diego Daniel Miceli¹, María Fernanda Cabrera Blatter^{1,2}, Mercedes Marina Brañas², Víctor Alejandro Castillo^{2,*}

¹UBACyT Grant Scholar, Facultad de Ciencias Veterinarias; ²Área Clínica Médica Pequeños Animales, U. Endocrinología, Htal. Escuela de Medicina Veterinaria, Facultad de Ciencias Veterinarias, Universidad de Buenos Aires. Av. Chorroarín 280 (1427) Ciudad Autónoma de Buenos Aires, Argentina

*Corresponding author, E-mail: vcastill@fvet.uba.ar

Summary: The aim of this study was to evaluate the presentation of corticotrophinoma in regard to its size and ACTH production in cross-breed and pure breed dogs. A retrospective study based on clinical histories from 2003-2008 was carried out on dogs with confirmed Pituitary Dependent Hypercortisolism (PDH) (n=100). Evaluation of the pituitary was performed by nuclear magnetic resonance imaging (NMRI) and tumours were classified according to their projection with respect to the sella turcica as intrasellar (IS) or extrasellar (ES). 26% (26/100) of the evaluated patients were cross-breeds and 74% (74/100) were dogs of different pure breeds. Both ACTH plasma concentration and urinary cortisol/creatinine ratio did not show significant differences between pure breed and cross-breed dogs. With regard to the frequency of presentation of IS and ES adenomas, no significant differences were observed neither between cross-breed and pure breed dogs nor between the different breeds studied. Thus, it can be concluded that there is no breed predilection for the presentation of IS or ES adenomas in dogs with PDH.

Key words: pituitary dependent hypercortisolism; corticotrophinoma; pituitary; Cushing's disease

Introduction

Pituitary Dependent Hypercortisolism (PDH) is caused by the ACTH producing pituitary adenoma or corticotrophinoma. Its aetiology is being studied and two theories were proposed: (1, 2) the monoclonal theory that suggests a mutation of the corticotroph cell as the mechanism for tumour development and (3, 4, 5) the hypothalamic theory based on overstimulation of the corticotroph that would lead to hyperplasia and afterward, mutation of some of these hyperplastic cells developing the adenoma. With respect to the hypothalamic theory, it has been proposed that the hypothalamus would exert an overstimulation on the corticotroph area by greater secretion of CRH and AVP (3, 5). Also, defects in the hypothalamic glucocorticoid receptor could lead to a greater stimulation of the corticotroph cells due to a

lower inhibitory action of cortisol (6, 7). On the other hand, dopaminergic neurodegeneration in aged individuals (8, 9, 10) or a decreased expression of the D2 dopaminergic receptor in the corticotroph cells might lead to diminished inhibition on the corticotroph area (11, 12, 13), hence producing hyperplasia. Consequently, the adenoma could develop from a somatic mutation in one of these hyperplastic cells. However, the characterization of a monoclonal state in the majority of the adenomas studied (2, 3), makes the monoclonal theory the most likely. Still, it is not clear which mutations could provoke the appearance of the tumour, and what factors are involved in its development (4). Candidate mutations would be defects in proteins that control the cell cycle (14, 15), as well as changes in the glucocorticoid and mineralocorticoid receptors and the 11- β -hydroxysteroid dehydrogenase type 1 (11 β -HSD1) (7). Considering that gene alterations could be involved in the development of the corticotrophinoma and taking into account that in breed dogs the level of homozygosis

increases, a greater incidence of PDH would be expected in these animals than in cross-breeds.

The corticotrophinoma can be evaluated by nuclear magnetic resonance imaging (NMRI). In humans, NMRI would be the most precise image diagnosis method for detecting and evaluating pituitary tumours (16, 17), which can be classified according to their size to micro- and macroadenomas (5, 18). There are also studies that describe the use of NMRI in dogs with PDH with good results (19, 20). According to the adenoma projection with respect to the sella turcica, we have recently classified these adenomas as intrasellar (IS) and extrasellar (ES); thus avoiding the inappropriate evaluation of the pituitary size which varies according the size of the dog (21).

The aim of the following study was therefore to evaluate the tumour size and ACTH secretion in cross-breed and pure breed dogs.

Materials and methods

Animals and tests

A retrospective study using clinical histories from 2003-2008 was carried out on dogs with confirmed PDH (n=100) in the Endocrinology Unit of the Hospital of the School of Veterinary Sciences of the University of Buenos Aires.

Dogs were divided into two groups: cross-breeds and pure breeds, and the latter were distributed according to the breed (more than 2 dogs by breed) or as "other breeds" in case to have a maximum of 2 dogs per breed.

The following diagnostic criteria were used: presence of clinical signs associated to hypercortisolism (polydipsia-polyuria, polyphagia, pendulous abdomen, dermatologic problems, anoestrus), cortisol : creatinine ratio (C/CR) in urine greater than 70 (according to our reference values); more than 50% reduction with regard to the basal levels of C/CR after administration of 0.1 mg/kg dexamethasone every 8 hours, according to Rijnberk et al. (22) and Galac et al. (23) and increase in plasmatic ACTH, measured by immunoradiometric assay (RIA) using a commercial kit (ACTH Alpcó immunoassays, Alpcó Diagnostics, Salem, USA). The ACTH intra-assay and inter-assay coefficients of variation were 3.1% and 5.8% respectively. Urine cortisol was measured by RIA, using a commercial kit (DPC Corporation, San Diego, California, USA) and its intra-assay and inter-assay coefficients of variation were 5% and

8% respectively. Urine creatinine was measured by Metrolab Autoanalyzer Merck, Germany, according to the manufacturer's instructions. Presence of the adenoma was confirmed using NMRI.

Diagnostic imaging

To perform the study dogs underwent general anaesthesia. Evaluation of the pituitary was carried out using NMRI on sagittal, axial and coronal sections, with slices every 2 mm, with gadolinium to contrast (General Electric 1Tesla). Tumours were classified according to their projection in IS or ES as it has been previously described (21).

Statistical analysis

Comparison of plasma ACTH concentration, C/CR (both basal and post dexamethasone) between breeds and cross-breed dogs was performed by Mann-Whitney's test and its values are expressed as median and range. Comparison of the adenomas IS or ES between breed and cross-breed dogs were carried out by Chi Square's test followed by Exact Fisher's test. For comparison of IS or ES projection between different breed dogs Chi Square's test was used. $P < 0.05$ was considered significant.

Ethical approval

The study was approved by the Ethics Committee of the Faculty of Veterinary Sciences of the University of Buenos Aires and by the Secretaría de Ciencia y Técnica (Secretariat of Science and Techniques) of the University of Buenos Aires (UBACyT; V006 project) in fulfilment of the national laws on experiments with animals.

Results

From the total number of patients evaluated, 26% (26/100) were cross-breed and 74% (74/100) were dogs of different breeds, with Poodles being predominant (Tab. 1). Average time of presentation of the first clinical signs noticed by the owners previous to PDH confirmation was 4.1 months (range of 1 year to 1 month before PDH was diagnosed). ACTH plasma concentration did not show significant differences between breed and cross-breed dogs (16.08 pmol/L [3.9-132] and 14.03 pmol/L [1.8-48], respectively) (Fig. 1). C/CR did not show significant differences between breed and cross-breed dogs, either

basal (cross-breed dogs: 210 [83-317]; breed dogs: 153 [66-756]) and post dexamethasone (cross-breed dogs: 95 [35-180]; breed dogs: 70 [30-147]). Inhibition after dexamethasone treatment did not occur in 20% (20/100) of the total dogs, showing similar proportions in both cross-breed (19.2%; 5/26) and breed dogs (20.3%; 15/74).

Table 1: Corticotrophinoma presentation according to NMRI in cross-breed dogs and different breeds

Breed	Number of cases	IS	ES
Cross-breed	26	7	19
Poodle	12	8	4
Beagle	8	1	7
Schnauzer mini	8	2	6
Daschund	8	4	4
S. Husky	5	3	2
Cocker	3	1	2
G.Shepherd	4	3	1
Other breeds	26	9	17

Other breeds: Shit-zu, Breton, Pitbull, Foxterrier, Boxer, Airedale Terrier, Welsh Terrier, Yorkshire Terrier, Bichon Frise, Belgian Sheepdog, Labrador, Bullterrier, Akita Malamut, Maltese, Pekinese, Pincher, Scottish Terrier, Irish Setter, Whippet, Bobtail. S. Husky: Siberian Husky; G. Shepherd: German Shepherd Dog. IS: intrasellar, ES: extrasellar

Regarding tumour morphology, a greater number of ES adenomas were observed in cross-breeds, Bea-

gles, Schnauzer mini, Cocker Spaniel and in the “other breeds” group. In Poodles and German Shepherds a greater number of IS adenomas were observed, whereas in Siberian Husky and Daschund, presentation was similar for both types (Tab. 1 and Fig. 2). Dogs that did not show inhibition to dexamethasone presented mostly ES adenomas (16/20); and no significant differences were found between cross-breed and breed dogs, holding the same proportion than in total dogs (ES: cross-breed dogs 80%, 4/5; breed dogs 80% 12/15; IS: 20% in both cross-breed and breed dogs)

Comparing frequency of presentation of ES and IS adenomas between breeds and cross-breeds, no significant differences were observed neither between groups nor between the different breeds studied.

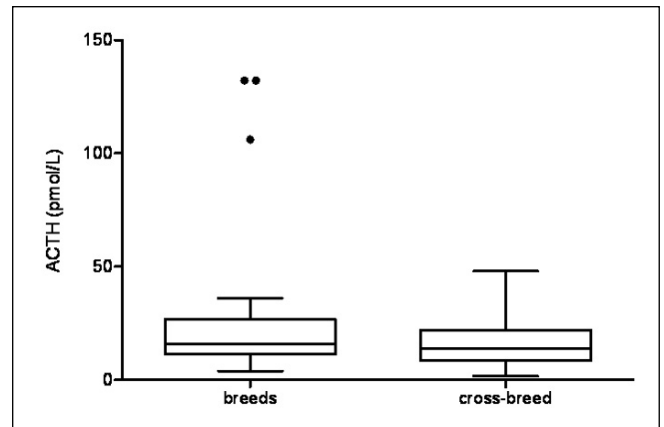


Figure 1: Plasma ACTH concentration (pmol/L) in pedigree and cross-breed dogs. Full circles represent 3 outlier values corresponding to dogs with ES adenomas (G. Shepherd, Schnauzer and Siberian husky)

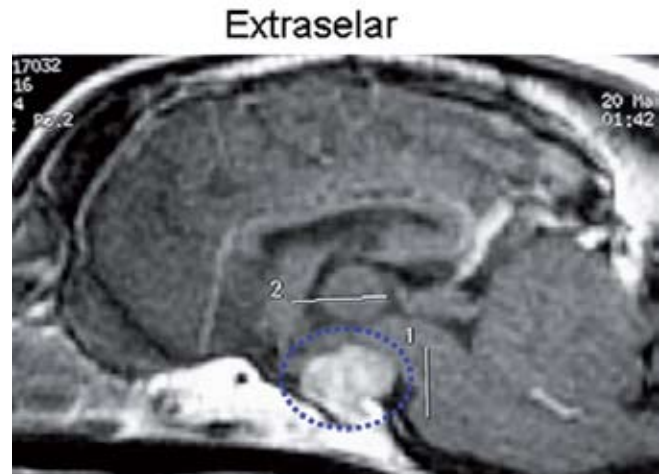
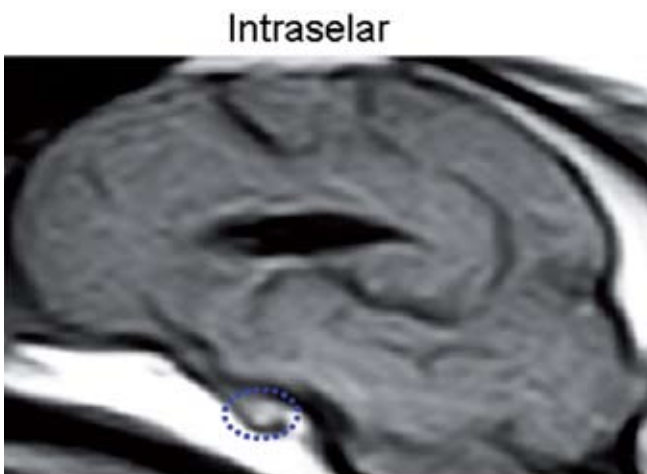


Figure 2: Nuclear magnetic resonance imaging (NMRI) on sagittal slice. Examples of intrasellar (left) and extrasellar (right) projection of the adenoma in 2 dogs. The adenoma is encircled with dotted line. Intrasellar tumour does not exceed the upper limit of the sella turcica and shows an increase of the paramagnetic signal. In contrast, the extrasellar tumour is expanding to the hypothalamic area and is showing irregular appearance

Discussion

Variations according to the type of corticotrophinoma regarding hormone production, size and resistance to corticoid inhibition as well as sex and age of presentation have been established (18, 21, 24). In this study we did not find significant differences in adenoma presentation (IS or ES), ACTH plasma concentration and C/CR between cross-breed and pure breed dogs, nor between different dog breeds.

Although a higher prevalence of PDH has been described in Poodles, Daschund and Terriers (25), this could be caused by temporal preferences for certain breed in different countries. In South America, cross-breed dogs are usually preferred, while different breed preference varies with trends and in different time periods. These preferences might determine the higher prevalence of cross-breed dogs with PDH in our country (Argentina), comparing this group with the different groups of each pure breed. However, according to our study, no significant differences were found between cross-breed and pure breed dogs. While the higher level of homozygosity in breed dogs could lead to the expectations that these animals could have a greater tendency for developing corticotrophinomas; based on our results, breed is not a risk factor for developing PDH. Other factors, independent of the genetic background, are most likely involved.

We have noticed that cross-breed dogs and certain breeds show a different kind of presentation with regard to the adenoma projection (ES or IS). It is possible that specific molecular defects more often occur in certain breeds. The fact that the time elapsed since the appearance of the first clinical signs and the diagnosis is not very long suggests that different sizes of corticotrophinomas are caused by different molecular alterations, as it has been described by many authors (1, 4, 18, 26). Thus, corticotrophinomas would not grow indefinitely; they would grow until reaching a self-limiting size. However, some of these tumours, usually macroadenomas, show a different behaviour: they not only present a sustained growth but they are also resistant to endogenous and exogenous glucocorticoid inhibition (18, 24). These findings are consistent with our study, where 80% of dogs that showed lack of inhibition to dexamethasone, presented ES adenomas, independently of their breed. Nevertheless, it must be considered that 20% of the adenomas, not inhibited by dexamethasone, are IS. It might be possible that these tumours grow over time, especial-

ly if steroideogenic inhibitors are used as medical treatment, as it has been described by Teshima et al (27). From these studies follows the importance of combining diagnostic tests with NMRI and the use of a specific treatment such as ACTH synthesis/tumour's growth inhibitors or surgical removal of the adenoma (28, 29, 30).

More studies are necessary to clarify which factors can provoke gene alterations (mutations, loss of heterozygosity, mRNA translation or transcription defects, etc.) or affect the hypothalamus-pituitary-adrenal axis regulation, leading to the development of the corticotrophinoma. The study by Teshima et al (7) suggested the GR defect is a major contribution to the tumour development, although this has not been yet conclusive.

Cell cycle proteins, particularly Rb and p27, have been reported to be associated with aggressive corticotrophinomas that develop from the intermediate lobe in mice (14, 31).

In summary, according to our study there is no genetic predisposition to develop neither PDH nor a particular type of adenoma (IS or ES); and pure breed dogs are not more susceptible than cross-breed dogs to develop the corticotrophinoma.

Acknowledgments

This project received funding from UBACyT, University of Buenos Aires (V006).

References

1. Melmed S. Mechanisms for pituitary tumorigenesis: the plastic pituitary. *J Clin Invest* 2003; 112: 1603–18.
2. Levy A, Lightman S. Molecular defects in the pathogenesis of pituitary tumors. *Front Neuroendocrinol* 2003; 24: 94–127.
3. Dahia PLM, Grossman AB. The molecular pathogenesis of corticotroph tumors. *Endocr Rev* 1999; 20:136–55.
4. Castillo VA, Gallelli MF. Corticotroph adenoma in the dog: pathogenesis and new therapeutic possibilities. *Res Vet Sci* 2009, article in press, doi:10.1016/j.rvsc.2009.07.005
5. Asa SL, Ezzat S. The cytogenesis and pathogenesis of pituitary adenomas. *Endocr Rev* 1998; 19:798–827.
6. Lamberts SW. Glucocorticoid receptors and Cushing's disease. *Mol Cell Endocrinol* 2002; 197: 69–72.
7. Teshima T, Hara Y, Takekoshi S, Teramoto A, Osamura RY, Tagawa M. Expression of genes related to corticotropin production and glucocorticoid feedback in corticotroph adenomas of dogs with Cushing's disease. *Domest Anim Endocrinol* 2009; 36: 3–12.

8. Bruyette DS, Ruehl WW, Smidberg TL. Canine pituitary-dependent hyperadrenocorticism: a spontaneous animal model for neurodegenerative disorders and their treatment with L-deprenyl. *Prog Brain Res* 1995; 106: 207–15.
9. Hereñú C, Brown O, Sosa Y, et al. The neuroendocrine system as a model to evaluate experimental gene therapy. *Curr Gene Ther* 2006; 6: 125–9.
10. Hereñú C, Rimoldi O, Becú-Villalobos D, Cambiaggi D, Portiansky E, Goya R. Restorative effect of insulin-like growth factor-I gene therapy in the hypothalamus of senile rats with dopaminergic dysfunction. *Gene Ther* 2006; 13: 1–9.
11. Colao A, Lombardi G, Annunziato L. Cabergoline. *Expert Opin Pharmacother* 2000; 1: 555–74.
12. de Bruin C, Hanson JM, Meij BP, et al. Expression and functional analysis of dopamine receptor subtype 2 and somatostatin receptor subtypes in canine Cushing's disease. *Endocrinology* 2008; 149: 4357–66.
13. Pivonello R, Ferone D, de Herder W, et al. Dopamine receptor expression and function in corticotroph pituitary tumors. *J Clin Endocrinol Metab* 2004; 89: 2452–62.
14. Nakayama K, Ishida N, Shirane M, et al. Mice lacking p27(Kip1) display increased body size, multiple organ hyperplasia, retinal dysplasia and pituitary tumors. *Cell* 1996; 85:707–20.
15. Kovalovsky D, Refojo D, Liberman AC, et al. Activation and induction of Nur77/Nurr1 in corticotrophs by CRH/cAMP: involvement of calcium, protein kinase A and MAPK pathways. *Mol Endocrinol* 2002; 16: 1638–51.
16. Lambrecht L, Rubens R. MRI signal intensity profiles of sellar and perisellar lesions. *Acta Clin Belgica* 1989; 44: 303–10.
17. Korogi Y, Mutsumasa T. Current concepts of imaging in patients with pituitary/hypothalamic dysfunction. *Semin Ultrasound CT MR* 1995; 16: 270–8
18. Selvais P, Donckier J, Buysschaert M, Maiter D. Cushing's disease: a comparison of pituitary Corticotroph microadenomas and macroadenomas. *Eur J Endocrinol* 1998; 138: 153–9.
19. Bertoy EH, Feldman EC, Nelson RW, et al. Magnetic resonance imaging of the brain in dogs with recently diagnosed but untreated pituitary-dependent hyperadrenocorticism. *J Am Vet Med Assoc* 1995; 206: 651–6.
20. Duesberg CA, Feldman EC, Nelson RW, Bertoy EH, Dublin AB, Reid MH. Magnetic resonance imaging for diagnosis of pituitary macrotumors in dogs. *J Am Vet Med Assoc* 1995; 206:657–62.
21. Gallelli MF, Cabrera Blatter MF, Castillo VA. A comparative study by age and gender of the pituitary adenoma and ACTH and α -MSH secretion in dogs with pituitary-dependent hyperadrenocorticism. *Research in Veterinary Science* 2009; article in press, doi 10.1016/j.rvsc.2009.06.011
22. Rijnberk A, Van Wees A, Mol J. Assessment of two tests for the diagnosis of canine hyperadrenocorticism. *Vet Res* 1988; 122:178–80.
23. Galac S, Kooistra H, Teske E, Rijnberk A. Urinary corticoid/creatinine ratios in the differentiation between pituitary-dependent hyperadrenocorticism and hyperadrenocorticism due to adrenocortical tumour in the dog. *Vet Q* 1997; 19: 17–20.
24. Bosje J, Rijnberk A, Mol J, Voorhout G, Kooistra H. Plasma concentrations of ACTH precursors correlate with pituitary size and resistance to dexamethasone in dogs with pituitary-dependent hyperadrenocorticism. *Domest Anim Endocrinol* 2002; 22: 201–10.
25. Feldman EC, Nelson RW. Comparative aspects of Cushing's syndrome in dogs and cats 1994; 23: 671–91.
26. Ikeda H, Yoshimoto T, Ogawa Y, Mizoi K, Murakami O. Clinicopathological study of Cushing's disease with large adenoma. *Clin Endocrinol* 1997; 46: 669–79.
27. Teshima T, Hara Y, Takekoshi S, et al. Trilostane-induced inhibition of cortisol secretion results in reduced negative feedback at the hypothalamic– pituitary axis. *Domest Anim Endocrinol* 2009; 36: 32–44.
28. Castillo VA, Giacomini DP, Paez-Pereda M, et al. Retinoic acid as a novel medical therapy for Cushing's disease in dogs. *Endocrinology* 2006; 174: 4438–44.
29. Castillo VA, Gomez NV, Lalia JC, Cabrera Blatter MF, Garcia JD. Cushing's disease in dogs: Cabergoline treatment. *Res Vet Sci* 2008; 85: 26–34.
30. Meij B, Voorhou GT, Rijnberk A. Progress in trans-sphenoidal hypophysectomy for treatment of pituitary-dependent hyperadrenocorticism in dogs and cats. *Gen Comp Endocrinol* 2002; 197: 89–96.
31. Jacks T, Fazeli A, Schmitt EM. Effects of an Rb mutation in the mouse. *Nature* 1999; 359: 295–300.

POJAVNOST KORTIKOTROPNIH TUMORJEV PRI MEŠANCIH IN ČISTOKRVNIH PSIH

M. F. Gallelli, D. D. Miceli, M. F. Cabrera Blatter, M. M. Brañas, V. A. Castillo

Povzetek: Namen naše raziskave je bil proučiti pogostnost kortikotropnih tumorjev hipofize glede na njihovo velikost in proizvodnjo kortikoliberina pri psih mešancih in čistokrvnih psih. Retrospektivna raziskava je zajela 100 psov, ki so imeli v letih 2003 do 2008 potrjeno diagnozo od hipofize odvisnega hiperkortizolizma. Hipofize so bile pregledane s pomočjo jedrske magnetne resonance, tumorje pa smo razdelili glede na njihovo velikost v tiste, ki so bili samo znotraj turškega sedla in na tumorje, ki so segali preko njegovih robov. Šestindvajset odstotkov preiskanih psov je bilo mešancev, 74 % pa je bilo čistokrvnih psov različnih pasem. Raven kortikoliberina v krvni plazmi in razmerje med kortizolom in kreatininom v seču se ni razlikovalo med mešanci in čistokrvnimi psi. Prav tako ni bilo razlike med mešanci in čistokrvnimi psi v pogostnosti pojavljanja tumorjev, omejenih znotraj turškega sedla ali tumorjev, razširjenih izven turškega sedla, prav tako pa nismo opazili nobenih razlik med pasmami čistokrvnih psov. Raziskava tako kaže, da pasma psov ne vpliva na pojavnost in hitrost rasti kortikotropnih tumorjev pri psih.

Ključne besede: od hipofize odvisen hiperkortizolizem; kortikotropni tumor; hipofiza; Cushingova bolezen