

Lokalna kateterska tromboliza kot terapija za globoko vensko trombozo – poročilo o primeru

Catheter-directed thrombolytic therapy for lower-extremity deep vein thrombosis: a case report

Avtor / Author

Ustanova / Institute

Aja Pajnik Snoj, MD¹, Andrej Markota, MD, PhD²

¹Urgentni center, Univerzitetni Klinični Center Maribor, Maribor, Slovenija; ²Oddelek za intenzivno interno medicino, Univerzitetni Klinični Center Maribor, Maribor, Slovenija;

¹Emergency Department, University Medical Centre Maribor, Maribor, Slovenia; ²Medical Intensive Care Unit, University Medical Centre Maribor, Maribor, Slovenia;

Ključne besede:

globoka venska tromboza; lokalna usmerjena tromboliza; perkutano interventno zdravljenje; phlegmasia cerulea dolens

Key words:

catheter-directed thrombolysis; deep vein thrombosis; percutaneous interventional treatment; phlegmasia cerulea dolens

Članek prispel / Received

27. 9. 2021

Članek sprejet / Accepted

19. 5. 2022

Naslov za dopisovanje /

Correspondence

Aja Pajnik Snoj, Emergency Department,
University Medical Centre Maribor,
Maribor, Slovenia
E-pošta: aja.pajnik.snoj@gmail.com

Izvleček

Globoka venska tromboza spodnjih okončin je pogost razlog za obravnavo bolnika v urgentni ambulanti. Kljub temu so napredovale oblike globoke venske tromboze redke (npr. phlegmasia cerulea dolens). Lokalna kateterska tromboliza velja za terapijo izbora pri zdravljenju napredovalih oblik globoke venske tromboze, kot je phlegmasia cerulea dolens. V članku bomo predstavili prvi primer tovrstnega zdravljenja v Univerzitetnem kliničnem centru Maribor (UKC Maribor).

Abstract

Patients with lower-extremity deep vein thrombosis commonly present to emergency departments. However, the propagation of deep vein thrombosis to phlegmasia cerulea dolens is rarely seen. Catheter-directed thrombolytic therapy is widely accepted as an appropriate treatment for severe forms of lower-limb deep vein thrombosis such as phlegmasia cerulea dolens. It is usually available only in a few selective hospitals. This study aimed to present a case of the first such procedure performed in the University Medical Centre Maribor.

INTRODUCTION

Deep venous thrombosis (DVT) is a common disease with an annual incidence of around 1–5 per 1000 people/year or an 11% absolute lifetime risk for an individual (1). It usually manifests with leg swelling, pain, warmth, and erythema, and is usually diagnosed with ultrasound. A majority of patients are treated with anticoagulation therapy (2). Infrequently, DVT progresses to phlegmasia cerulea dolens (PCD), which can manifest in venous gangrene. The symptoms result from the obstruction of venous drainage from the extremity and include severe pain, swelling, cyanosis, and edema. The resulting compartment syndrome impairs arterial supply, such that circulatory collapse and shock frequently occur. A delay in treatment may result in death or loss of the patient's limb (3).

PCD is usually managed with catheter-directed thrombolysis or thrombectomy using mechanical techniques (4,5,6). We presented a case of a 56-year-old man suffering from PCD. Catheter-directed thrombolytic therapy and mechanical thrombectomy were required to prevent further complications.

CASE REPORT

A 56-year-old Caucasian male patient presented to the emergency department complaining of pain, swelling, and discoloration of his lower left extremity. The symptoms started on the morning of the day he presented to the emergency department. He was otherwise healthy with no regular medication and unremarkable medical history.

The examination revealed that his entire left lower extremity was swollen with purple discoloration and was very painful to palpate (figure 1). The arterial pulses distally were present but weak. He was hypotensive, tachycardic, and normopnoeic. A bedside ultrasound revealed DVT of the femoral and popliteal veins. Computed tomography angiography revealed a filling defect in the inferior vena cava, extending from the branching of the right renal vein caudally through the iliac veins and the entire left

lower extremity. The patient also had signs of DVT in the right leg.

The laboratory results revealed leukocytosis ($44 \times 10^9/L$), acute renal failure [creatinine $275 \mu\text{mol/L}$, urea 9.8 mmol/L , calculated glomerular filtration rate $21 \text{ mL}/(\text{min} \cdot 1.73 \text{ m}^2)$], and hyperkalemia (7.3 mmol/L). The levels of inflammatory markers (C-reactive protein 231 mg/L , procalcitonin $1.6 \mu\text{g/L}$) and myoglobin ($9855 \mu\text{g/L}$) were also elevated. The arterial blood gas analysis revealed metabolic acidosis (pH 7.3) with low bicarbonate (12 mmol/L) and high lactate levels (4.6 mmol/L).

He was admitted to the medical intensive care unit. At admission to the intensive care unit, he was unresponsive to fluids. He required $0.3 \mu\text{g}/(\text{kg} \cdot \text{min})$ of noradrenaline and vasopressin ($0.035 \text{ IU}/\text{min}$) to maintain mean arterial pressure around 75 mm Hg . Bicarbonate was continuously infused for urine alkalization. Hyperkalemia was treated with insulin and glucose. Anticoagulation was performed by continuous infusion of unfractionated heparin. The catheter-directed thrombolysis was initiated via a catheter inserted through the left popliteal vein after other options were exhausted approximately 16 h following admission to the hospital (figure 3). Over the following 24 h, our patient received a continuous infusion of tissue plasminogen activator at $2 \text{ mg}/\text{h}$. Control venography showed a significantly improved flow through the venous system. At the same time, clinical and laboratory improvement was observed (figure 2). The infusion of noradrenaline was discontinued on day 3, along with the reduction of the fraction of inspired oxygen to 22% and normalization of urine output at around $80 \text{ mL}/\text{h}$. He was discharged from the intensive care unit on day 4 and discharged from the hospital on day 12.

DISCUSSION

We rapidly obtained the diagnosis of PCD with evidence of cardiocirculatory instability and

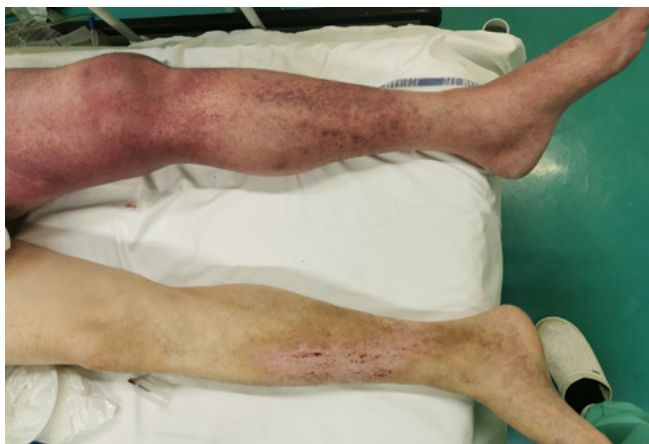

Figure 1. Patient's legs upon the first examination.

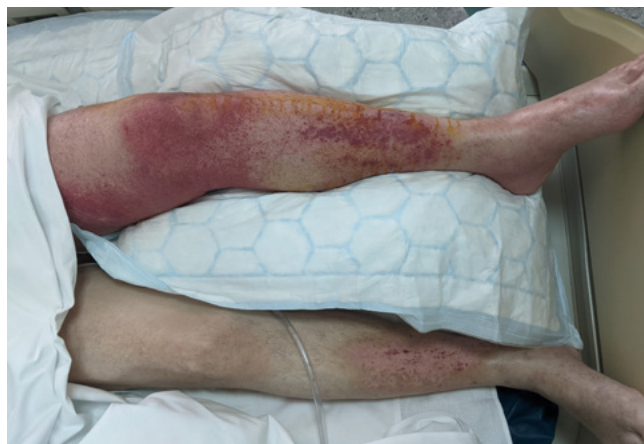

Figure 2. Patient's legs after successful reperfusion.

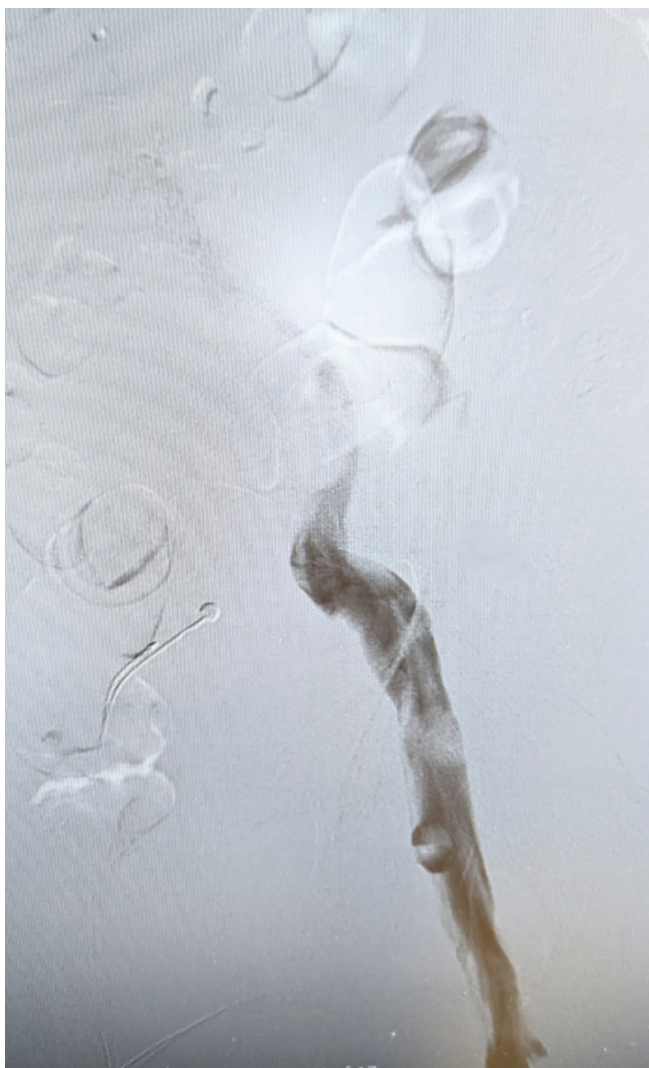


Figure 3. Filling defect of the patient's left iliac veins seen on a venogram.

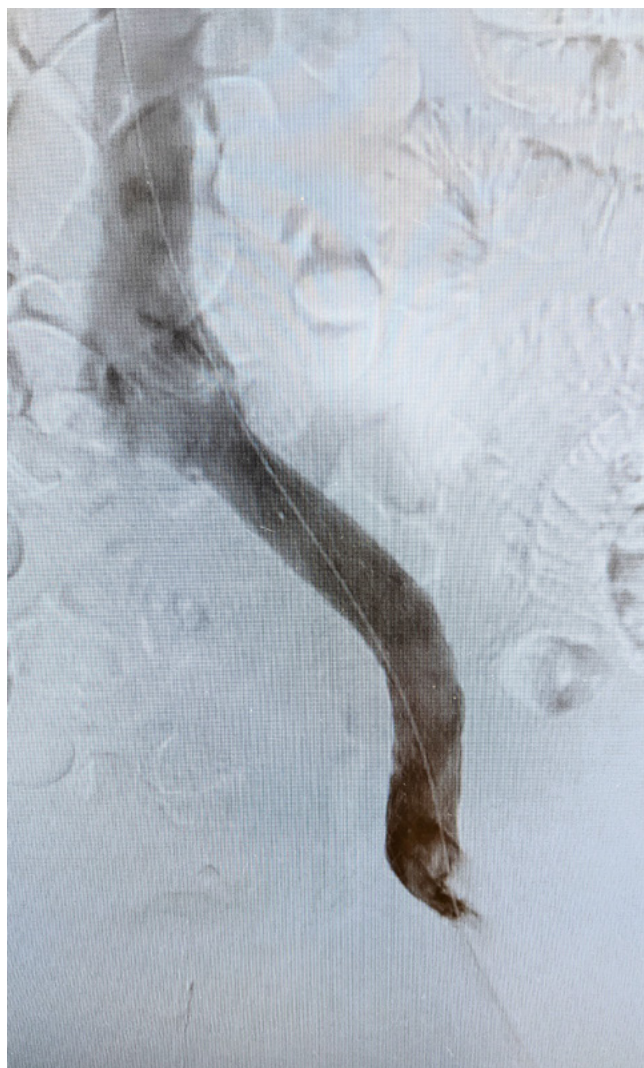


Figure 4. Venogram of the left iliac veins after stent placement.

multiorgan failure, which demonstrated the need for more immediate and aggressive therapy.

Catheter-directed rather than systemic thrombolytic therapy is now the most common method of administering thrombolytic agents in patients with PCD. Patients should receive systemic anticoagulation, usually with an infusion of unfractionated heparin. A number of studies have shown that thrombolytic therapy results in a more rapid and complete lysis of clots, compared with anticoagulant therapy alone, but it has no impact on recurrent thromboembolism or mortality (2,4,5,6). Also, it does not reduce the incidence of post-thrombotic syndrome (2,4,5).

Catheter-directed approaches have the additional advantage of combining thrombolysis with mechanical thrombus removal, which results in faster restoration of limb perfusion (5,6). Usually, the catheter is placed deep into the thrombus by an interventional radiologist with the help of a guidewire using the Seldinger technique (3,5). During the procedure, sometimes an inferior vena cava (IVC) filter is placed to trap thrombus fragments and prevent pulmonary embolism. Pulmonary embolism, which causes significant morbidity and mortality, has been reported to occur in as many as 4.5% of patients who undergo catheter-directed procedures for DVT. The absolute indication for this procedure is in patients who have DVT despite adequate anticoagulation therapy or those who cannot take anticoagulation therapy (7). The morbidity associated with additional interventional procedures of insertion and retrieval of the filter should also be considered. Furthermore, IVC filters that are not removed on time have been reported to be associated with an increased risk of complications such as IVC thrombosis, recurrent DVT, thrombophlebitis, and venous stasis disease (8). In our case, the aforementioned procedure was not performed, since the thrombus extended to the level of renal veins.

The most commonly used drug for thrombolysis is tissue plasminogen activator, with the usual dose 0.5–1 mg/h. As for our patient, a venogram is usually performed 12–24 h after the start of the infusion (5). The manual extraction of the thrombus

was continued in the present case using aspiration. The venogram uncovered an underlying stenotic lesion at the level of external iliac veins, and the interventional radiologist postponed venous graft placement (figure 4).

While the catheter is in place, it is imperative to check the patient frequently for adverse effects, such as bleeding. Sometimes, reperfusion results in further swelling and ischemia. Possible local complications are catheter displacement, perforation, infection, and hematoma (5). If catheter-directed thrombolysis is not successful, alternative approaches include mechanical extraction using aspiration; angioplasty; rotational, rheolytic, or ultrasound devices; and surgical thrombectomy (4).

Furthermore, establishing the cause of DVT is important. PCD is most commonly caused by malignancy, but it may also be because of procoagulant states, genetic disorders, or May-Thurner syndrome (3). Our patient tested negative for coagulopathies. However, we discovered a stenotic segment of the common iliac vein. Therefore, the most likely cause of the disease in the present case was May-Thurner syndrome.

CONCLUSIONS

Our case demonstrated that prompt treatment of the life-threatening forms of DVT, such as PCD, with catheter-directed thrombolysis and mechanical aspiration of the thrombus can result in a rapid clinical, laboratory, and radiological improvement. This treatment strategy should be made available 24/7 in tertiary-level hospitals.

DISCLAIMER

The images were taken with explicit permission from the patient to be used for educational purposes.

REFERENCES

1. Lijfering WM, Rosendaal FR, Cannegieter SC. Risk factors for venous thrombosis – current understanding from an epidemiological point of view. *Vr J Haematol*. 2021 Jun; 149 (6): 824-33.
2. Broderick C, Watson L, Armon MP. Thrombolytic strategies versus standard anticoagulation for acute deep vein thrombosis of the lower limb. *Cochrane Database Syst Rev*. 2021 Jan 19;1(1):CD002783.
3. Oguzkurt L, Ozkan U, Demirturk OS, Gur S. Endovascular treatment of phlegmasia cerulea dolens with impending venous gangrene: manual aspiration thrombectomy as the first-line thrombus removal method. *Cardiovasc Intervent Radiol*. 2011 Dec;34(6):1214-21.
4. Wong PC, Chan YC, Law Y, Cheng SWK. Percutaneous mechanical thrombectomy in the treatment of acute iliofemoral deep vein thrombosis: a systematic review. *Hong Kong Med J*. 2019 Feb;25(1):48-57.
5. Rabuffi P, Vagnarelli S, Bruni A, Gallucci M, Ambroggi C, Passaro G, Flore RA, Tondi P. Pharmacomechanical catheter-directed thrombolysis for acute iliofemoral deep vein thrombosis: our case series. *Eur Rev Med Pharmacol Sci*. 2019 Mar;23(5):2244-2252.
6. Enden T, Haig Y, Kløw NE, Slagsvold CE, Sandvik L, Ghanima W, Hafsahl G, Holme PA, Holmen LO, Njaastad AM, Sandbæk G, Sandset PM; CaVenT Study Group. Long-term outcome after additional catheter-directed thrombolysis versus standard treatment for acute iliofemoral deep vein thrombosis (the CaVenT study): a randomised controlled trial. *Lancet*. 2012 Jan 7;379(9810):31-8.
7. Lee SH, Kim HK, Hwang JK, Kim SD, Park SC, Kim JI, Won YS, Youn SS, Moon IS. Efficacy of Retrievable Inferior Vena Cava Filter Placement in the Prevention of Pulmonary Embolism during Catheter-Directed Thrombectomy for Proximal Lower-Extremity Deep Vein Thrombosis. *Ann Vasc Surg*. 2016 May;33:181-6.
8. Ni H, Win LL. Retrievable inferior vena cava filters for venous thromboembolism. *ISRN Radiol*. 2013 Apr 22;2013:959452.