

PERCUTANEOUS TRANSLUMINAL ANGIOPLASTY OF AN AORTIC RECOARCTATION

PERKUTANA TRANSLUMINALNA ANGIOPLASTIKA AORTNE REKOARKTACIJE

Pavčnik D., Robida A.

Abstract — Two cases of successful dilatation of recoarctation of the aorta due to a subclavian turn-down operation are reported. In both cases Grüntzig technique was used. The first patient, aged 10 months, had the gradient reduced from 40 mm Hg to 10 mm Hg. The second, aged 1 year, had the gradient reduced from 80 mm Hg to 30 mm Hg. In the second patient right femoral pulse disappeared after procedure and surgery (thrombarterectomy) was performed.

UDC: 616.132-008.17-089.844

Key words: aortic coarctation, angioplasty transluminal

Case report

Radiol. lugosl. 21 (2) 117–119, 1987

Introduction — Percutaneous transluminal angioplasty (PTA) was originally developed by Dotter and Judkins (3) in 1964 for treatment of atherosclerotic peripheral vascular disease. Ten years later, Grüntzig and Hopff (5) developed balloon catheter for successful treatment of stenoses and occlusions throughout the vascular system.

Sos successfully dilated a postmortem specimen of coarctation in 1979 (14), and his success was confirmed by Lock in an excised human specimen (10). Following surgical repair of coarctation of the thoracic aorta, stenosis recurs in 6–48% of children (7, 15). Repeated surgery carries a high morbidity and mortality rate (2, 7), and the patient is often left with residual gradient. For these reasons Casteneda-Zuniga developed an experimental model to examine the feasibility of dilating recoarctation of the aorta (1). Lock reported on five patients who had dilation of post-operative coarctation (9). Despite a lower incidence of recoarctation following the subclavian turn-down operation, we had the opportunity to dilate two such restenoses.

Methods — The wire and 5 F cobra catheter was passed across the coarctation into the ascending aorta for pressure recording and injection of contrast material through the end hole of

the catheter. The gradient across the coarctation was measured just before the balloon was placed across the area of narrowing. The balloon was inflated by hand with 10cc syringe 5 times over 15–20 minute period. Each time balloon was inflated over 5-second period. Post-

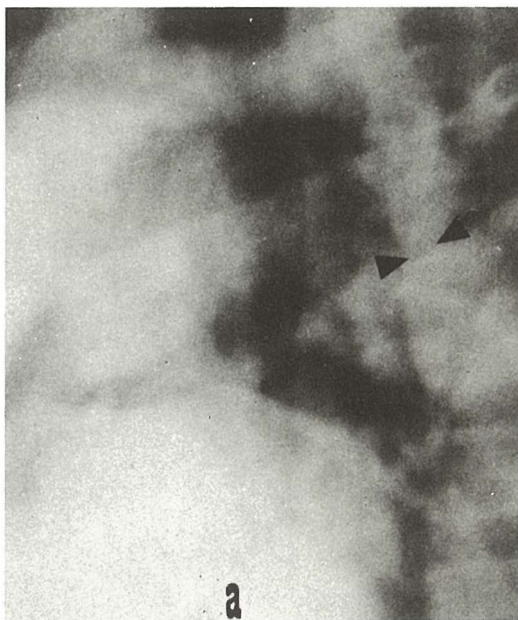

Fig. 1 a — Aortogram before dilatation

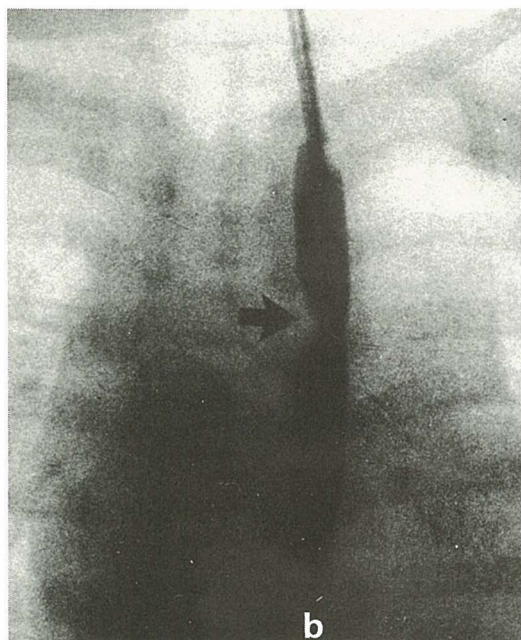


Fig. 1 b – Hourglass deformity of the balloon at the site of recoarctation

dilatation angiograms and pressure measurements were obtained. Heparin is indicated during the procedure to reduce thrombotic complications. We used 100 IU/kg body weight.

Case 1 – In a 10-month old girl with ventricular septum defect and mild pulmonary hypertension stenosis was dilated with a number 7 F, 7 mm balloon catheter. Percutaneous transluminal dilatation resulted in 70 % enlargement of the coarctate areas (Fig. 1 a, b, c). Blood pres-

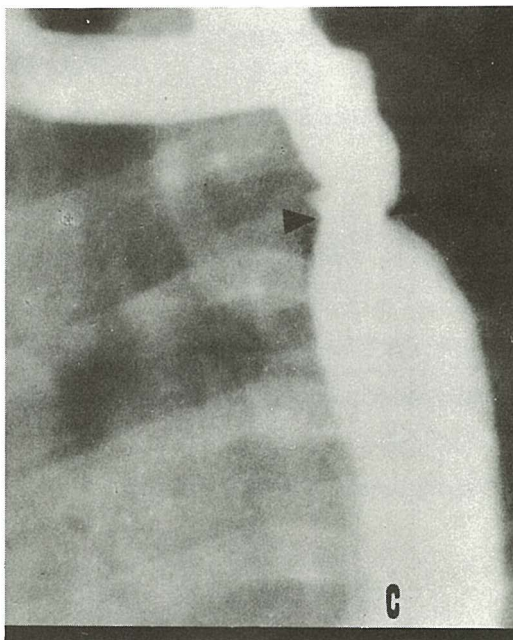


Fig. 1 c – Postdilatation aortogram

sure was 140/105 mm Hg in the right arm. Gradient was reduced from 40 mm Hg to 10 mm Hg (Fig. 2). After a few days blood pressure was 110/90 mm Hg in the right arm and the patient had normal femoral pulses.

Case 2 – In a 1-year old boy after subclavian flap operation examination revealed a systolic murmur and aortic bruit. Blood pressure was 185/95 mm Hg in the right arm. There was a hypoplastic aortic arch and an eccentric narrowing of the aorta.

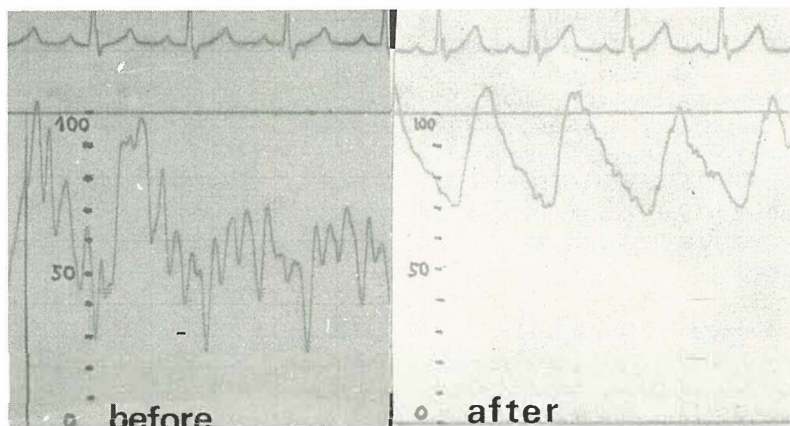


Fig. 2 – Pressure gradient measurements before and after dilatation

Restenosis was dilated with a number 8 F, 8 mm balloon catheter. The patient had an immediate reduction of gradient from 80 mm Hg to 30 mm Hg, with 40 % increase in diameter. In this patient a complication was noted. After the procedure, right femoral pulse disappeared and surgery (thrombariectomy) had to be performed. Next day blood pressure was 140/90 in the right arm.

Discussion – The surgical repair of coarctation of the aorta in infancy results in a significant incidence of restenosis, varying from 6 percent to as much as 48 percent in one report of excision and end to end reanastomosis (7, 15). Dissatisfaction with these results has led to alternative repairs, such as the subclavian turn-down operation (12, 13). Since surgery for recoarctation entails considerable morbidity as well as mortality rate, advantages of PTA are obvious. Percutaneous transluminal angioplasty may well represent an alternative or initial method of therapy with decreased morbidity and mortality. Balloon dilatation of aortic recoarctation could be accomplished in the highest risk infant population (9).

Medical literature, up to 1986 reported several successfully dilated restenoses of aorta. Lock and coworkers reported on good results in five patients (9). Similar results were published by Fellows (4), Lorber (11), Hess (6) and Kan (8).

We had one complication-thrombosis at the site of puncture. The complication was recognised in time for successful emergency surgery. In this case number 8 F catheter was used. We find 8- and 9-F catheters to be too large for infants.

Povzetek

Poročava o dveh uspešnih dilatacijah restenoze aorte, ki sta nastali po »subclavia flap« operaciji. V obeh primerih sva uporabila Grünzigovo tehniko. Pri prvem bolniku, starem 10 mesecev, je bil gradient pritiska znižan s 40 mm Hg na 10 mm Hg, medtem ko je bil pri drugem bolniku, starem 1 leto, gradient pritiska znižan z 80 mm Hg na 30 mm Hg. Pri drugem bolniku je nastala komplikacija – tromboza na vbođenem mestu. Potrebna je bila tromboarteriektomija desne femoralne arterije.

References

1. Castaneda-Zuniga W. R., Lock J. E., Vlodaver Z., Rusnak B., Rysavy J. P., Herrera M., Amplatz K.: Transluminal dilatation of coarctation of the abdominal aorta. An experimental study in dogs. *Radiology* 143: 693–697, 1982.

2. Cerilli J., Lauridsen P.: Reoperation for coarctation of the aorta. *Acta Chir Scand* (129) 391–394, 1965.

3. Dotter C. T., Judkins M. P.: Transluminal treatment of arteriosclerotic obstruction. Description of a new technique and a preliminary report of its application. *Circulation* 30: 654–670, 1964.

4. Fellows K. E.: Therapeutic procedures in CHD: Current status and future prospects. *Cardiovasc Intervent Radiol.* 7: 170–177, 1984.

5. Grünzig A., Hopff H.: Perkutane Rekanalisation chronischer arterieller Verschlüsse mit einem neuen Dilationskatheter. Modifikation der Dotter-Technik. *Dtsch Med Wochenschr.* 99: 2502–2505, 2511, 1974.

6. Hess J.: Percutaneous transluminal balloon angioplasty in restenosis of coarctation of the aorta. *Br Heart J* 55 (5): 459–61, 1986.

7. Ibarra-Pérez C., Castaneda A. R., Varco R. L., Lilehei C. W.: Recoarctation of the aorta. Nineteen year clinical experience. *Am J Cardiol* 23: 778–784, 1969.

8. Kan J. S.: Treatment of restenosis of coarctation by percutaneous transluminal angioplasty. *Circulation* 68 (5): 1087–94, 1983.

9. Lock J. E., Bass J. L., Amplatz K., Fuhrman B. P., Castaneda-Zuniga W. R.: Balloon dilation angioplasty of aortic coarctations in infants and children. *Circulation* 68: 109–116, 1983.

10. Lock J. E., Castaneda – Zuniga W. R., Bass J. L., Foker J. E., Amplatz K., Anderson R. W.: Balloon dilatation of excised aortic coarctations. *Radiology* 143: 689–691, 1982.

11. Lorber A. et al.: Balloon angioplasty for recoarctation following the subclavian flap operation. *Int J Cardiol.* 10 (11): 57–63, 1986.

12. Pierce W. S., Waldhausen J. A., Verman W., Whitman V.: Late results of the subclavian flap procedures in infants with coarctation of the thoracic aorta. *Circulation* 58 (suppl. 1): 178–182, 1978.

13. Ring E. J., McLean G. K.: *Interventional Radiology: Principles and Techniques.* Boston, Little, Brown, 1981 (227–239).

14. Sos T., Sniderman K. W., Rettlek-Sos B., Strupp A., Alonso D. R.: Percutaneous transluminal dilatation of coarctation of thoracic aorta post-mortem (letter). *Lancet* 1979 (2): 970–971.

15. Williams W. G., Shindo G., Trusler G. A., Dische M. R., Olley P. M.: Results of repair of coarctation of the aorta during infancy. *J Thorac Cardiovasc Surg* 79: 603–608, 1980.

Author's address: as. dr. Dušan Pavčnik, Institut za rentgenologijo UKC, Zaloška 7, 61000 Ljubljana.