

Cutaneous paradoxical inflammatory reaction of erythema induratum of Bazin to standard antituberculosis treatment

Miloš D. Pavlović^{1,2}✉, Motunrayo Adisa³

¹Section of Dermatology, Circle Care Clinic, Dubai, United Arab Emirates. ²School of Medicine, University of Maribor, Maribor, Slovenia.

³Dermatopathology Unit, The Skin Care Center, Glenview, IL, United States.

Abstract

Cutaneous tuberculosis (TBC) is rather rare and has diverse clinical presentations relative to host immunity and the number of bacilli present in the tissue. A group of cutaneous lesions called tuberculids represent a strong, delayed-type hypersensitivity reaction to mycobacteria. Among them, erythema induratum of Bazin (EIB) typically presents as tender erythematous nodules that ulcerate and are usually confined to the posterior aspects of the calves. Paradoxical reactions (PRs) to appropriate treatment involving the skin have mostly been described in the setting of miliary tuberculosis. These PRs are encountered in infectious and inflammatory diseases during the institution of appropriate treatment representing a worsening or relapse of disease under treatment or unmasking of subclinical disease. This case report describes a patient with EIB developing a necrotic PR shortly after initiation of antituberculosis therapy. The skin lesions cleared with a topical corticosteroid treatment and continued antituberculosis therapy. It is important to recognize cutaneous PR in the setting of treated cutaneous TBC and to reassure patients about the excellent outcome that can be achieved with continuation of treatment.

Keywords: erythema induratum of Bazin, cutaneous tuberculosis, tuberculids, paradoxical reaction

Received: 25 September 2024 | Returned for modification: 7 January 2025 | Accepted: 16 February 2025

Introduction

Cutaneous tuberculosis (TBC) is a skin infection due most often to *Mycobacterium tuberculosis*, an acid- and alcohol-fast bacillus, and rarely due to *M. bovis* and bacillus Calmette–Guérin (BCG). Cutaneous TBC is rather rare, making up 1.5% to 3% of all extrapulmonary TBC cases (1, 2). It has diverse clinical presentations relative to host immunity and the number of bacilli present in the tissue. Direct inoculation of *M. tuberculosis* from an exogenous source can lead to tuberculous chancre, TBC verrucosa cutis, and occasionally lupus vulgaris. The endogenous infection may manifest as scrofuloderma, acute miliary TBC, tuberculous gummas, orificial TBC, and lupus vulgaris (1, 2). A separate group of lesions, termed tuberculids, arise due to delayed hypersensitivity reactions to *M. tuberculosis* or its antigens in individuals with strong cell-mediated immunity. The diagnostic criteria include tuberculoid granuloma (or other suggestive microscopic features) on histopathology, strongly positive Mantoux or interferon-gamma release assay, absence of mycobacteria in the skin and culture, and resolution of skin lesions with antituberculosis therapy (1–4). Mycobacterial DNA can usually be identified with the use of polymerase chain reaction (PCR), proving its causal role. However, failure to detect *M. tuberculosis* by PCR does not exclude the diagnosis of tuberculids. Among tuberculids, erythema induratum of Bazin (EIB) presents as ulcerative tender, erythematous nodules that are usually confined to the posterior aspects of the calves, although the lesions may affect the lateral and anterior surfaces as well (1, 3, 4), and it has a female predominance. In cases with negative TBC findings (chest radiograph, tuberculin testing, and PCR), testing for chronic hepatitis C viral infection or other infections is recommended (4). It is the most common form of cutaneous tuberculosis in Japan and China (35%–40%) (5–7).

Paradoxical reactions (PRs) to appropriate treatment involving the skin have mostly been described in the setting of miliary tu-

berculosis (8, 9). Only two cases of cutaneous TBC (tuberculosis cutis verrucosa and lupus vulgaris) have been reported to be accompanied by a PR to treatment (10, 11). Both forms of tuberculosis are paucibacillary and occur with good host immunity.

Here we describe a patient with EIB, a tuberculid developing a necrotic PR shortly after initiation of antituberculosis therapy.

Case report

A 36-year-old black woman from South Africa presented with recurrent painful nodules on her lower legs that had developed 6 months earlier. The hyperpigmented nodules were tender to the touch, occurring in succession, and were located on both her calves and shins. Apart from a medical history of gastroesophageal reflux disease, she was otherwise healthy.

Complete blood cell count along with liver and renal function tests, C reactive protein, and chest X-rays were within normal limits except for mild absolute neutrophilia ($9.36 \times 10^9/l$). A deep skin biopsy of one of the plaques on the right calf was performed. The histopathological review was consistent with the diagnosis of EIB or nodular vasculitis. The histologic sections showed suppurative lobular panniculitis with necrosis, dermal and septal fibrosis in addition to septal expansion, and a superficial and deep lymphohistiocytic inflammatory infiltrate with neutrophils, few eosinophils, multinucleated giant cells, and focal areas of extravasated red blood cells (Fig. 1). A QuantiFERON-TB Gold+ test (interferon-gamma release assay) was positive (6.60 IU/ml; less than 0.35 is negative), confirming the diagnosis of EIB. Additional imaging excluded other sites of extrapulmonary TBC.

A standard 6-month course of antituberculosis treatment was initiated (isoniazid, rifampin, pyrazinamide, and ethambutol for 2 months, and then isoniazid and rifampin for another 4 months). Two weeks into the treatment, the patient presented with newly developed pain, swelling, and bullous changes in the largest of

✉ Corresponding author: mdpavlovic2004@yahoo.com

the lesions (Fig. 2a). The reaction occurred 2 weeks into the treatment on a single lesion with a negative bacterial culture, and so treatment failure, relapse, and secondary or recurrent infection as possible differential diagnoses were excluded. Thus a PR was suspected, and the patient was encouraged to continue with the oral treatment. The bulla was incised and drained, after which she was instructed to apply mometasone furoate 0.1% ointment once daily for a week. Ten days later the reaction subsided, and soon the lesion healed with post-inflammatory hyperpigmentation along with almost complete regression of all the other lesions (Fig. 2b, c).

Discussion

PRs are encountered in infectious and inflammatory diseases during the institution of appropriate treatment in both immunosuppressed and immunocompetent subjects (8). PRs represent a worsening or relapse of disease under treatment or the unmasking of subclinical disease.

Tuberculids are well known to occur in subjects with excel-

lent immune reactivity toward *M. tuberculosis* (1, 3). The development of a PR during the treatment indirectly confirms the presence of viable bacteria in at least some cutaneous lesions that, upon their death, offer the immune system a boosting number of antigens (12). Historically, a prototype of systemic PR is the Jarisch–Herxheimer reaction seen in patients with spirochetal infections within 24 hours of institution of antibiotic treatment (13). These reactions can be fatal in some cases of parasitic infections (e.g., gnathostomiasis and neurocysticercosis) by affecting the central nervous system, or in cardiovascular syphilis when the inflammation affects the heart (13, 14). PRs in non-HIV-infected patients with TBC may affect 6% to 30% of appropriately treated subjects (4). The most common cutaneous form of PR is development of subcutaneous abscesses in miliary tuberculosis (8). In these cases, a huge number of bacterial antigens are released in the background of a weak immunity to *M. tuberculosis*. In general, it seems that PRs in the setting of an infectious disease may be a consequence of either increased availability of microbial antigens locally or systemically, or improvement in the immune system reaction toward the antigens (e.g. HIV treatment, removal of immu-

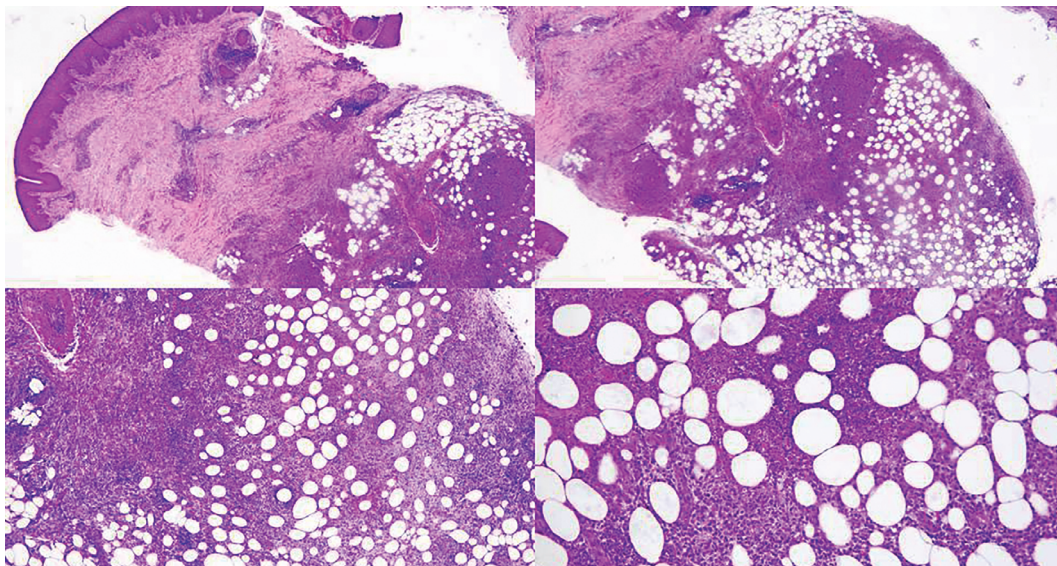


Figure 1 | Low- to high-power view of the histological sections. Superficial and deep mixed inflammatory infiltrate with suppurative lobular panniculitis with tissue necrosis, dermal and septal fibrosis, and expansion. The inflammatory infiltrates are comprised of lymphocytes, histiocytes, multinucleated giant cells, many neutrophils, few eosinophils, and focal areas of extravasated red blood cells.

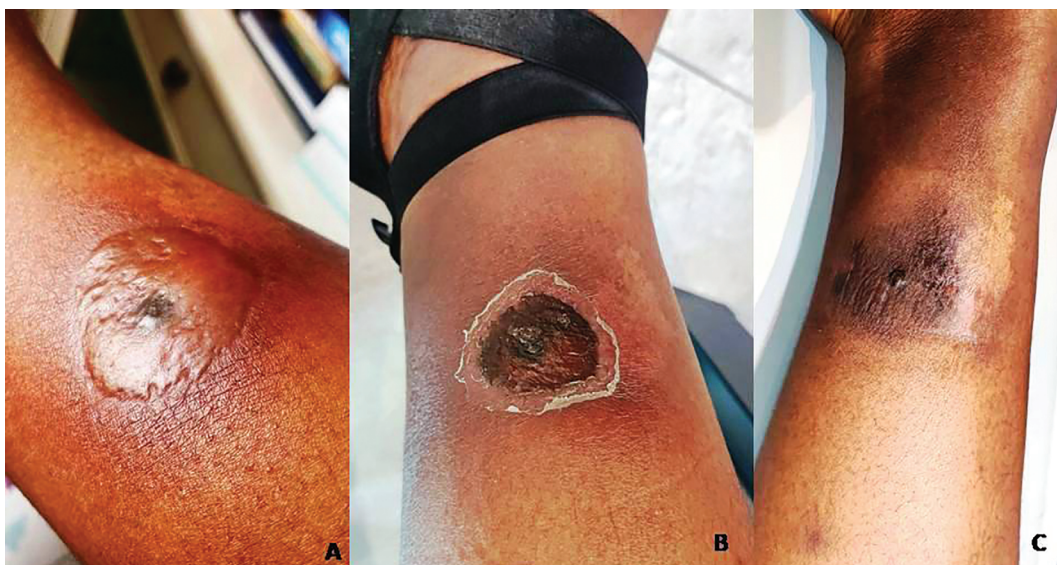


Figure 2 | Development of (a) a bulla surrounded by erythema on one of the lesions on the lower leg, which (b) evolved into a shallow ulceration covered by a dry crust in 10 days and (c) resolved with hyperpigmentation 3 weeks later.

nosuppressives), or both simultaneously (12).

This case may be used to highlight two aspects of tuberculids. Although the number of mycobacteria in lesions is very low, their degradation products may be sufficient to stimulate a vigorous immune response. A delayed start of the PR (2 weeks or longer) compared to a classic Jarisch–Herxheimer reaction (24 h) may be linked to slower division of dormant *M. tuberculosis* in tissues and/or different pathways of antigen presentation, or it may have to do with the immune system reactivation (15, 16).

PRs in patients with cutaneous TBC can affect the preexisting lesion(s) themselves or develop at a distant site (10, 11). Cutaneous PRs are usually mild and transient, and they do not require systemic immunosuppressive treatment. The timeframe of PRs in cutaneous TBC has been reported to range between 2 weeks and 5 months after institution of treatment. In a reported case of lu-

pus vulgaris, it began earlier, after 2 weeks, as in our patient, and it recurred upon treatment resumption following a break due to hepatotoxicity caused by methotrexate given for misdiagnosis of cutaneous lymphoma (10). The authors suspect that the removal of immunosuppressant contributed to the PR. In another report of a patient with tuberculosis verrucosa cutis on a thumb, PR developed between 5 and 6 months into the treatment at a distant site as an ulcerated nodule in the axilla (11).

Conclusions

It is important to recognize cutaneous PR in the setting of treated cutaneous TBC and to reassure patients about the excellent outcome that can be achieved with continuation of treatment.

References

1. Kaul S, Kaur I, Mehta S, Singal A. Cutaneous tuberculosis. Part I: pathogenesis, classification, and clinical features. *J Am Acad Dermatol*. 2023;89:1091–103.
2. Kaul S, Jakhar D, Mehta S, Singal A. Cutaneous tuberculosis. Part II: complications, diagnostic workup, histopathologic features, and treatment. *J Am Acad Dermatol*. 2023;89:1107–19.
3. Dhattarwal N, Ramesh V. Tuberculids: a narrative review. *Indian Dermatol Online J*. 2022;14:320–9.
4. Mascaró JM Jr, Baselga E. Erythema induratum of Bazin. *Dermatol Clin*. 2008;26:439–45.
5. Zhang J, Fan YK, Wang P, Chen QQ, Wang G, Xu AE, et al. Cutaneous tuberculosis in China—a multicentre retrospective study of cases diagnosed between 1957 and 2013. *J Eur Acad Dermatol Venereol*. 2018;32:632–8.
6. Ho CK, Ho MH, Chong LY. Cutaneous tuberculosis in Hong Kong: an update. *Hong Kong Med J*. 2006;12:272–7.
7. Azevedo TP, Oliveira ML. Analysis of cutaneous tuberculosis cases reported from 2000 to 2013 at a university hospital in Rio de Janeiro. *Rev Soc Bras Med Trop*. 2016;49:373–5.
8. Cheng VC, Ho PL, Lee RA, Chan KS, Chan KK, Woo PC, et al. Clinical spectrum of paradoxical deterioration during antituberculosis therapy in non-HIV-infected patients. *Eur J Clin Microbiol Infect Dis*. 2002;21:803–9.
9. Mert A, Bilir M, Ozturk R, Tabak F, Ozaras R, Tahan V, et al. Tuberculous subcutaneous abscesses developing during miliary tuberculosis therapy. *Scand J Infect Dis*. 2000;32:37–40.
10. Santesteban R, Bonaut B, Córdoba A, Yanguas I. Paradoxical reaction to antituberculosis therapy in a patient with lupus vulgaris. *Actas Dermosifiliogr*. 2015;106:e7–12. English, Spanish.
11. Melwani PM, Hernández-Machín B, Borrego L, Peñate Y. Paradoxical response during antituberculosis therapy in a patient with tuberculosis verrucosa cutis. *J Am Acad Dermatol*. 2011;65:e53–4.
12. Lanzafame M, Vento S. Tuberculosis-immune reconstitution inflammatory syndrome. *J Clin Tuberc Other Mycobact Dis*. 2016;3:6–9.
13. Dhakal A, Sbar E. Jarisch–Herxheimer reaction. *StatPearls* [Internet]. [Cited 2024 Sep 25]. Available from: <https://www.ncbi.nlm.nih.gov/books/NBK557820/>.
14. García HH, Del Brutto OH; Cysticercosis Working Group in Peru. Antiparasitic treatment of neurocysticercosis—the effect of cyst destruction in seizure evolution. *Epilepsy Behav*. 2017;76:158–62.
15. Salina EG, Makarov V. Mycobacterium tuberculosis dormancy: how to fight a hidden danger. *Microorganisms*. 2022;10:2334.
16. Carlson JA, Dabiri G, Cribier B, Sell S. The immunopathobiology of syphilis: the manifestations and course of syphilis are determined by the level of delayed-type hypersensitivity. *Am J Dermatopathol*. 2011;33:433–60.