

# Makroanevrizma retinalne arterije pri bolniku z arterijsko hipertenzijo

## Retinal arterial macroaneurysm in a patient with arterial hypertension

### Avtor / Author

Ustanova / Institute

Matejka Masten<sup>1</sup>, Mojca Hudovernik<sup>2,3</sup>, Dušica Pahor<sup>1,3</sup>

<sup>1</sup>Univerzitetni klinični center Maribor, Oddelek za očne bolezni, Maribor, Slovenija,

<sup>2</sup>Očesni center Hudovernik, Maribor, Slovenija, <sup>3</sup>Univerza v Mariboru, Medicinska fakulteta, Katedra za oftalmologijo, Maribor, Slovenija

<sup>1</sup>University Medical Centre Maribor, Department of Ophthalmology, Maribor, Slovenia,

<sup>2</sup>Eye Center Hudovernik, Maribor, Slovenia, <sup>3</sup>University of Maribor, Faculty of Medicine, Department of Ophthalmology, Maribor, Slovenia

### Ključne besede:

makroanevrizma, retinalna krvavitev, edem v makuli, arterijska hipertenzija

### Key words:

macroaneurysm, retinal haemorrhage, macular oedema, arterial hypertension

### Članek prispel / Received

18.04.2014

### Članek sprejet / Accepted

28.05.2014

### Naslov za dopisovanje /

#### Correspondence

Prof. dr. Dušica Pahor, dr. med.

Univerzitetni klinični center Maribor

Oddelek za oftalmologijo,

Ljubljanska 5, SI – 2000 Maribor,

Slovenija

Telefon +386 23211630

Fax +386 23312393

E-pošta: d.pahor@ukc-mb.si

### Izvleček

**Namen:** Namen prispevka je prikazati primer bolnika z makroanevrizmo retinalne arterije ob neurejeni sistemski arterijski hipertenziji.

**Poročilo o primeru:** 48-letni bolnik je bil sprejet na naš oddelek zaradi poslabšanja vidne ostrine desnega očesa. Navajal je dvojne slike in zamegljen centralni del vidnega polja. Sicer se je zdravil zaradi arterijske hipertenzije. Drugih zdravstvenih težav ni imel. Predstavljeni so klinični potek, diagnostični pristop in zdravljenje bolnika z makroanevrizmo retinalne arterije.

**Zaključek:** Pri zdravljenju bolnika z makroanevrizmo retinalne arterije je pomemben celosten pristop. Za čim uspešnejši končni izid zdravljenja bolnikov je poleg zdravljenja očesne simptomatike potrebno tudi zdravljenje sistemskih dejavnikov tveganja. Za opredelitev natančne vloge laserske fotokoagulacije, intravitrealne aplikacije

### Abstract

**Purpose:** To present a case of retinal arterial macroaneurysm in a 48-year-old male patient with systemic arterial hypertension.

**Case report:** A 48-year-old male was admitted to our department because of progressive deterioration of visual acuity in his right eye. He reported diplopia and blurred central field vision. The patient was treated for systemic arterial hypertension and had no other known medical problems.

Medical treatment, examination results, and therapy were presented in this case report.

**Conclusions:** In the treatment of patients with retinal arterial macroaneurysm a holistic approach is important. In an attempt to optimize the final outcome of the patient's treatment, both the ocular symptoms and systemic risk factors should be

plina, kirurških vitreoretinalnih tehnik, uporabo Nd:YAG ali argon laserja in intravitrealne aplikacije anti-VEGF zdravil v zdravljenju makroanevrizme retinalne arterije bodo potrebne še dodatne raziskave.

*treated. Therapeutic interventions for eyes with retinal arterial macroaneurysm include laser photocoagulation, pneumatic displacement of haemorrhage, vitreoretinal surgical techniques, the use of neodymium-doped yttrium aluminium garnet or argon laser, and intravitreal injections of anti-vascular endothelial growth factor drugs. Their precise roles should be evaluated in further studies.*

## INTRODUCTION

Retinal arterial macroaneurysms (RAMs) are acquired saccular or fusiform dilatations of the large retinal arterioles, usually within the first three orders of bifurcation. They usually arise, enlarge, and eventually undergo thrombosis and fibrosis (1,2). There are several theories on the pathogenesis of RAM. The most consistent association is with systemic hypertension, which is present in two thirds of patients with macroaneurysm. A macroaneurysm can also occur at bifurcations, or at the site of a previously detected embolus or arterial wall atheroma, where previously a focal arterial damage took place. They are most often located on the temporal arcades. Macroaneurysms can also sometimes rarely occur on the optic nerve head, cilioretinal artery, and nasal vessels (1,3).

RAMs in most cases occur in older people over 60 years of age. Numerous studies report a higher incidence in women, in the range of 60%–100% (3). Macroaneurysms are usually unilateral, and are bilateral in less than 10% of the cases (1,4).

Many clinical entities may simulate RAM, including Coat's disease, IRVAN syndrome (idiopathic retinal vasculitis, aneurysms, and neuroretinitis), diabetic retinopathy, Valsava retinopathy, retinal teleangiectasia, old retinal branch vein occlusion, retinal capillary haemangioma, retinal cavernous haemangioma,

choroid melanoma, haemorrhagic retinal pigment epithelial detachment seen in age-related macular degeneration, Terson's syndrome (1).

In most cases, RAM can be diagnosed clinically. The key fundoscopic finding is the presence of blood at multiple layers, including the preretinal, intraretinal, subretinal, the sub-ILM spaces, and the vitreous. Other common but less pathognomonic findings include exudative retinopathy, consisting of yellow-white hard lipid exudates in a circinate pattern surrounding the aneurysm. Pulsations of the aneurysm may also be visible in 10% of the cases (1).

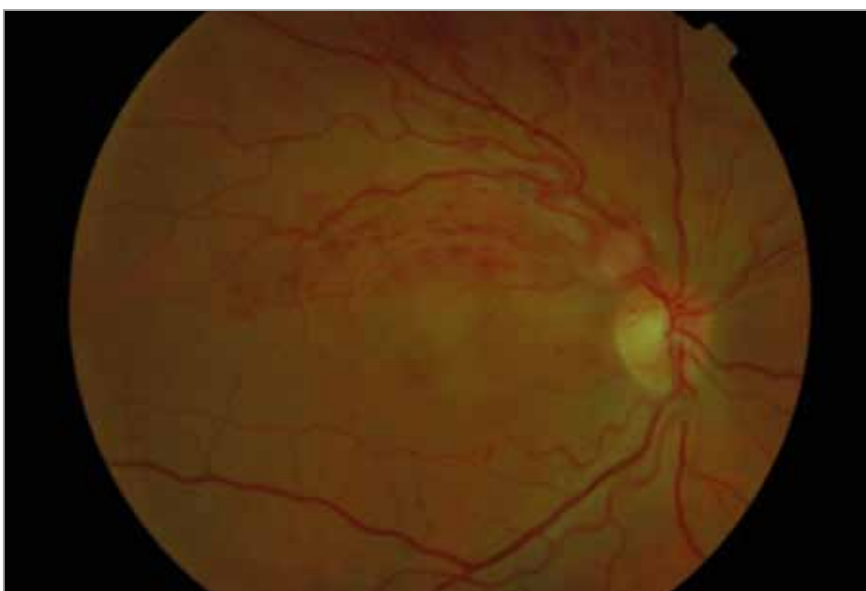Intravenous fluorescein angiography (IVFA) may reveal the presence of a macroaneurysm, showing an immediate filling of the aneurysm, which may leak throughout the examination. If retinal haemorrhage is present, an area of blocked fluorescence around the aneurysm may be observed. The involved artery may be narrow and irregular, and the surrounding capillaries may demonstrate leakage (4). In cases with dense haemorrhage, IVFA does not provide definitive evidence of a retinal macroaneurysm. In such cases, indocyanin green angiography can be useful (5). Optical coherence tomography (OCT) can also be used to monitor serous detachment following photocoagulation treatment and retinal structural changes (6,7).

## CASE REPORT

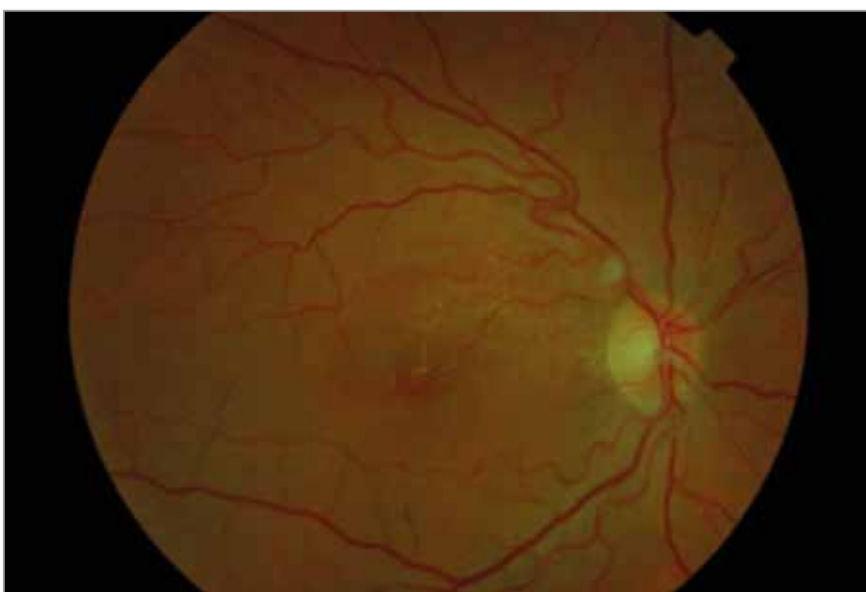
A 48-year-old patient presenting with arterial hypertension was primarily examined in the out-patient clinic in April 2010. He complained of occasional non-painful decreases in visual acuity of his right eye, which had started two months earlier. He reported double vision, with letters appearing one above the other, and blurred vision in the central part of the visual field. The best corrected visual acuity (BCVA) of his left eye was 0.1 decimal equivalents of Snellen visual acuity, because of eye injury since childhood. The anterior segments of both eyes were within normal limits. Dilated fundus examination revealed hypertensive retinopathy at stage II. A lesion, suspicious for macroaneurysm on the superotemporal arcade near the optic nerve head, and surrounded with blazing-shaped and spotty haemorrhages, was observed in the right eye. The macula was within normal limits. The BCVA (Snellen chart) was 0.8. Possible changes were monitored, and the patient was advised to strictly control his blood pressure.

Two weeks later, the patient presented for an earlier follow-up due to additional, significant decrease of vision. The BCVA of his right eye was 0.25. The lesion, suspicious for macroaneurysm, had become larger and was also causing some pressure to the underlying vein. Small, spotty haemorrhages with surrounding oedema in the area of the superotemporal arcade were visible (Fig.1). OCT showed subretinal fluid beneath the fovea (macular oedema up to

600 microns) (Fig.3). The patient was admitted to our department. Because the values of systolic blood pressure were very high, the patient was examined by an internist, who modified the patient's antihypertensive therapy. IVFA was performed and revealed a large macroaneurysm in the front of the first bifurcation of the superotemporal artery. It was partially thrombosed, yet leaking into the macula. Blood flow in the affected artery was still present (Fig.5).



**Figure 1.** Fundus photography before treatment

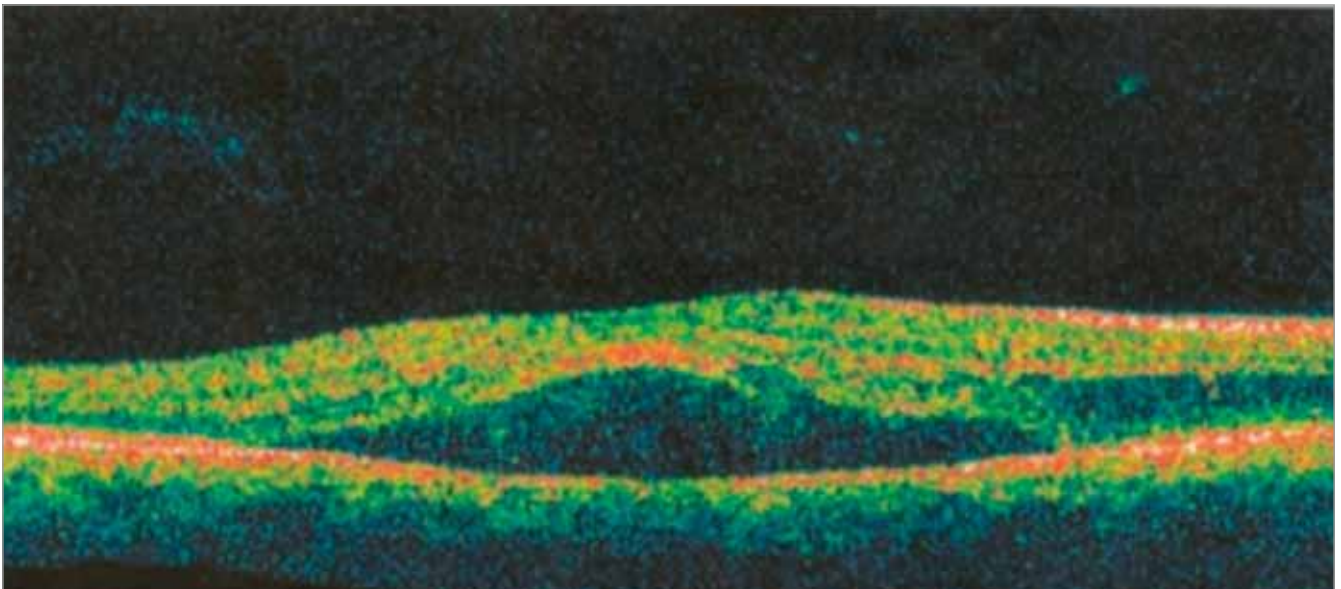


**Figure 2.** Fundus photography 6 weeks after treatment

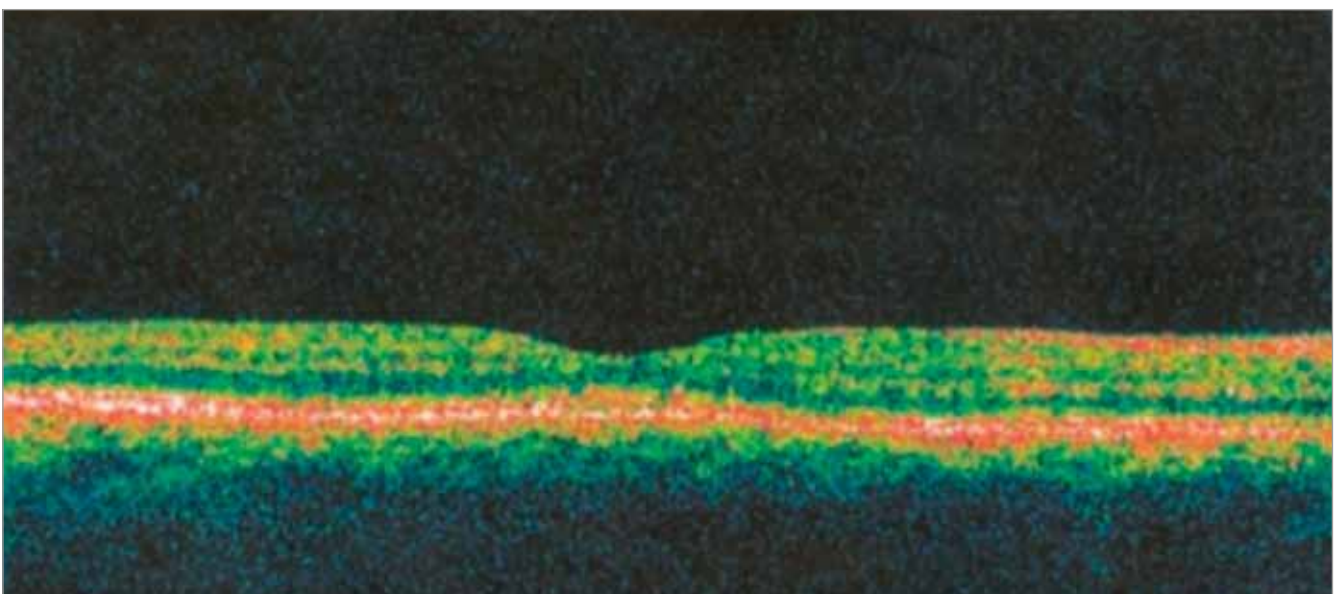
Focal laser photocoagulation of the retina was performed in the area between the macroaneurysm and macula to reduce or prevent exudation into the macula. Seventy-six laser burns were applied in two sessions; the first session upon admission to our department, and the second at discharge. The spot size of the laser burns was 100  $\mu\text{m}$ , with 100 ms duration (time), and power of 60–130 mW. The patient was also receiving 4 mg injections of

dexamethasone into the sub-Tenon's space from the 4th to 10th day of hospitalization, with a total of seven injections.

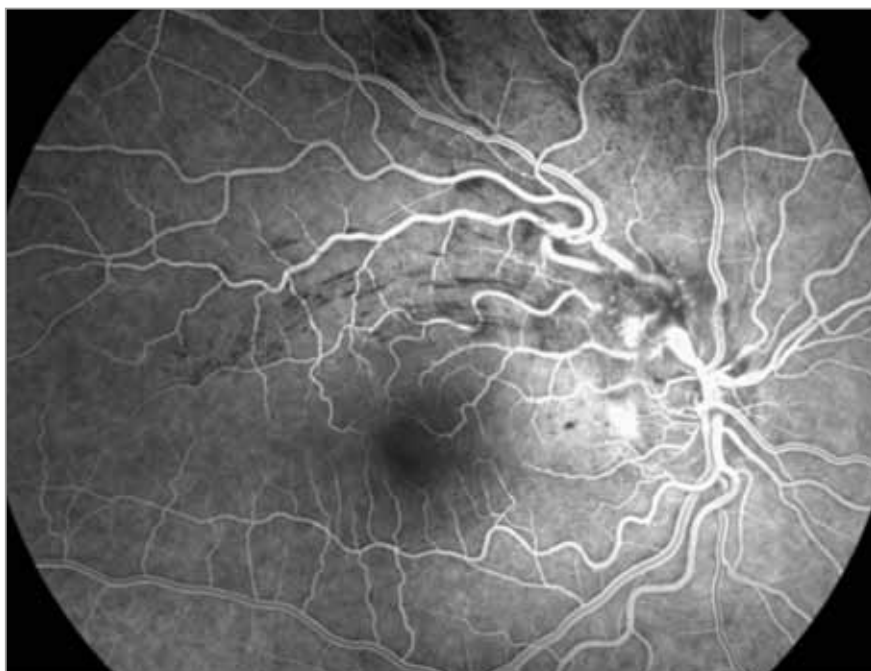Visual acuity of his right eye gradually improved, and after 10 days it was 0.63 with correction. OCT showed reduction of macular oedema. The patient's blood pressure normalized after modifying anti-hypertensive therapy. He was dismissed from our



**Figure 3.** Optical coherence tomography (OCT) findings before treatment



**Figure 4.** Optical coherence tomography (OCT) findings 6 weeks after treatment



**Figure 5.** Intravenous fluorescein angiography (IVFA) findings before treatment

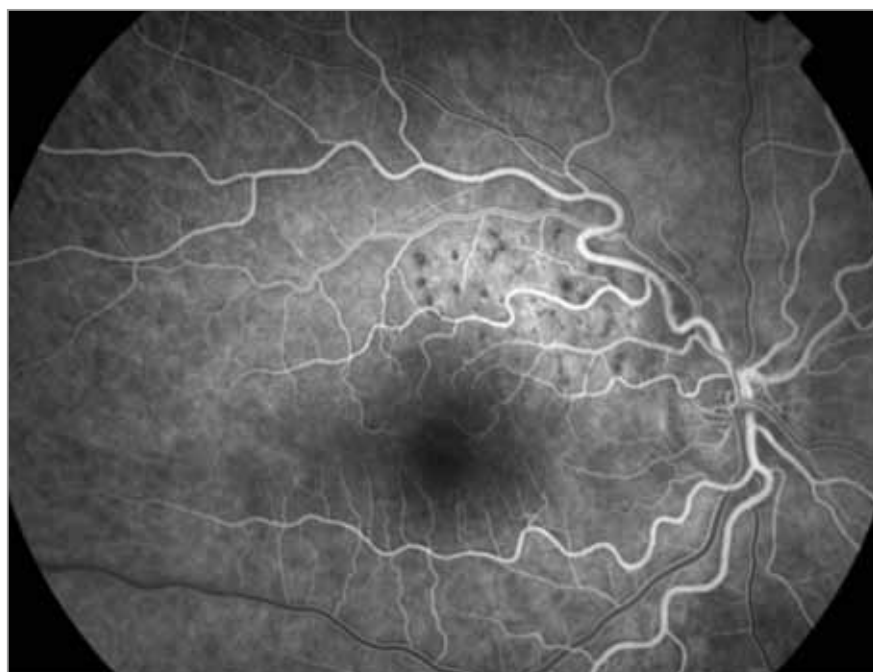Six weeks later the BCVA of the right eye was 0.8–1.0. Fundoscopy revealed completely white, fibrosed, and much smaller macroaneurysm. There were no intraretinal haemorrhages found. In the upper nasal part of the macula, small, whitish lipid deposits were visible, yet without an evident macular oedema (Fig.2). On the follow-up IVFA, no filling of the macroaneurysm was observed, and no leakage involving the macula in the late phases was noted (Fig.6). The OCT findings were normal (Fig.4). At the 1 and 3 year follow-up examinations the BCVA was 1.0, and OCT findings were normal.

## DISCUSSION

In most cases macroaneurysms thrombose spontaneously. Hypertension and other systemic risk factors should be treated adequately. Monitoring and observation in anticipation of spontaneous involution of the macroaneurysm is indicated in eyes with good visual acuity in which the macula is not threatened and in those patients with minor retinal haemorrhage without significant oedema or exudation. An extensive chronic foveal exudation or subretinal blood leakage can cause permanent structural changes to the retina, and may therefore indicate poor visual acuity (1–4). Indications for direct or indirect laser treatment

department on the 11th day post-treatment. On weekly follow-up examinations, the patient reported gradual visual acuity improvement.

include vision loss due to chronic macular exudates, or oedema (4). In such cases, the most commonly employed approach is conventional threshold laser



**Figure 6.** Intravenous fluorescein angiography (IVFA) findings 6 weeks after treatment

treatment, which may be burdened by many complications, including enlargement of the laser scar, choroidal neovascularization, subretinal fibrosis, branch retinal artery occlusion, increased retinal exudation, and scarring with possible retinal traction. RAM obliteration can also be achieved using subthreshold laser treatment, with no visible laser scars or complications (8). Studies reported evidence of treating larger premacular and submacular haemorrhages with the use of neodymium-doped yttrium aluminium garnet laser, but there is a risk of vitreous haemorrhage or damage to the macula (4). For the removal of dense, thick subretinal haemorrhage associated with the macroaneurysm, a pars plana vitrectomy, with the use of tissue plasminogen activator (t-PA), can be useful (9). An intravitreal gas application (perfluoropropane or sulphur hexafluoride), with or without the use of t-PA, can be used to apply direct pressure on the macula and to displace the haemorrhage, while in a face-down position, for at least 24 h (10). There are several case reports on RAM treated with intravitreal injection of vascular endothelial growth factor (VEGF) inhibitors. Anti-VEGF drugs can prevent the formation of abnormal blood vessels and counteract VEGF-induced vascular permeability. These inhibitors could help to close

the involved retinal artery and normalize the vessel wall through the localized inhibition of VEGF. This treatment option should be considered when laser therapy is inappropriate or not effective, or in patients where there is evidence of extensive macular oedema. This treatment could also be used for cases involving ruptured RAM (11,12). These new interventions should be evaluated in further studies.

In our patient, laser photocoagulation was used in the area surrounding the macroaneurysm to reduce exudation into the macula. This produced less risk for complications, such as thrombosis and retinal arterial obstruction distal to the macroaneurysm, associated with applying laser burns directly to the lesion. The patient was receiving dexamethasone injections into the sub-Tenon's space, to reduce macular oedema. The patient's blood pressure normalized after modifying antihypertensive therapy. An improvement of BCVA from 0.25 to 0.8–1.0 was observed within 6 weeks, and OCT showed complete regression of subretinal fluid under the fovea.

In conclusion, despite the wide use of anti-VEGF drugs, laser treatment for RAM remains an effective treatment for visual recovery.

## REFERENCES

1. Contreras JE, Mieler WF, Mittra RA, Pollack JS, Jiyamapa J. Retinal arterial macroaneurysm. In Yanoff M, Duker JS. *Ophthalmology: Expert Consult*. Mosby; 2008: 912–7.
2. Pitkänen L, Tommila P, Kaarniranta K, Jääskeläinen JE, Kinnunen K. Retinal arterial macroaneurysms. *Acta Ophthalmol*. 2014 Mar; 92(2): 101–4.
3. Lewis RA, Norton EW, Gass JDM. Acquired arterial macroaneurysms of the retina. *Br J Ophthalmol* 1987; 71: 817–25.
4. Rabb MF, Gagliano DA, Teske MP. Retinal arterial macroaneurysms. *Surv Ophthalmol* 1988; 33: 73–96.
5. Townsend-Pico WA, Meyers SM, Lewis H.: Indocyanine green angiography in the diagnosis of retinal arterial macroaneurysms associated with submacular and preretinal haemorrhages: a case series. *Am J Ophthalmol* 2000; 129: 33–7.
6. Takahashi K, Kishi S. Serous macular detachment associated with retinal arterial macroaneurysm. *Jpn J Ophthalmol* 2006; 50: 460–4.
7. Tsujikawa A, Sakamoto A, Ota M, Oh H, Miyamoto K, Kita M, et al. Retinal structural changes associated with retinal arterial macroaneurysm examined with optical coherence tomography. *Retina*. 2009 Jun; 29(6): 782–92.

8. Battaglia Parodi M, Iacono P, Pierro L, Papayannis A, Kontadakis S, Bandello FM. Subthreshold laser treatment versus threshold treatment for symptomatic retinal arterial macroaneurysm. *Invest Ophthalmol Vis Sci.* 2012; 53: 1783–6.
9. Ibanez HE, Williams DF, Thomas MA, Ruby AJ, Meredith TA, Boniuk I, et al. Surgical management of submacular haemorrhage: a series of 47 consecutive cases. *Arch Ophthalmol* 1995; 113: 62–9.
10. Cakir M, Cekiç O, Yilmaz OF. Pneumatic displacement of acute submacular haemorrhage with and without the use of tissue plasminogen activator. *Eur J Ophthalmol.* 2010 May–Jun; 20(3): 565–71.
11. Javey G, Moshfeghi AN, Moshfeghi AA. Management of ruptured retinal arterial macroaneurysm with intravitreal bevacizumab. *Ophthalmic Surg Lasers Imaging.* 2010 Aug 30; 41.
12. Zweifel SA, Tönz MS, Pfenninger L, Becker M, Michels S. Intravitreal anti-VEGF therapy for retinal macroaneurysm. *Klin Monbl Augenheilkd.* 2013 Apr; 230(4): 392–5.