

Primary Pulmonary Mycobacteriosis in a Cat: Immunohistochemical and Histopathological Evaluation

Key words

feline mycobacteriosis;
immunohistochemistry;
histopathology;
pulmonary

Osman Dağar*, Mehmet Burak Ateş, Mustafa Ortatatli, Ertan Oruç

Department of Pathology, Faculty of Veterinary Medicine, Selçuk University, Konya, Turkey

*Corresponding author: osmndgr20@gmail.com

Abstract: In this case report, primary pulmonary mycobacteriosis in a domestic cat was assessed using histopathological and immunohistochemical methods. The cat was admitted to a private veterinary clinic and presented with hyporexia, lethargy, and dyspnea with an abdominal component. For diagnostic purposes, thorax radiography was performed. Radiographic lung imaging showed the presence of opaque foci that were widely distributed throughout the lung. The cat's condition gradually deteriorated, and the cat died 2 hours after being brought to the clinic. Following owner consent, gross post-mortem examination was performed immediately after death at the same clinic. White foci measuring 2–10 mm in diameter covered the surface of the lungs and were present throughout the parenchyma, mostly multifocally and occasionally coalescing. No other macroscopical pathological findings were observed in other organs or on the skin. Some of the lung tissue with macroscopic lesions underwent further histopathological and immunohistochemical examination. Multifocal to coalescing areas of caseous necrosis (without a fibrous capsule) with karyorrhectic nuclei, and numerous macrophages were observed. Ziehl-Neelsen staining revealed many acid-fast bacteria. Immunohistochemical staining revealed positive immunostaining for *Mycobacterium* spp. This case study highlights the importance of considering zoonotic risks in cats diagnosed with primary pulmonary mycobacteriosis.

Received: 27 July 2023
Accepted: 19 March 2024

Introduction

Mycobacteria are nonsporulating, acid-fast, weakly Gram-positive, and straight to slightly curved bacilli that measure 0.3–0.6 µm in width and 1–4 µm in length (1-4). They are associated with local and disseminated infections in a range of host species (1-4) and include the *Mycobacterium avium* and *Mycobacterium tuberculosis* complexes as well as many other nontuberculous species. The *M. tuberculosis* complex includes *M. tuberculosis*, *M. bovis*, and *M. microti* (1, 4, 5).

Mycobacteria are phagocytosed by macrophages after entering the body through the alimentary tract, lungs, and skin. In the event of an insufficient cell-mediated immune response, they can persist and replicate within phagocytes by inhibiting phagosome-lysosome fusion, among other defence mechanisms. Mycobacteria cause some of the most difficult and significant infections in the world due to these defence mechanisms (6, 7).

Granulomatous inflammation occurs not only in cases of tuberculosis but also in other mycobacterial infections (8). Mycobacteriosis is usually characterized by a proliferative lesion type, in contrast to the rarely observed exudative lesion type (9). Exudative lesions, in which neutrophils are the major cell type, are both triggered by and induce high local bacillary load and tend to enlarge and progress toward liquefaction and cavitation. By contrast, proliferative lesions are triggered by low bacillary loads, mainly comprise epithelioid cells and fibroblasts, and tend to fibrose, encapsulate, and calcify (10).

Infected cats typically present with localised cutaneous disease with possible local lymph node involvement, which may become systemic, but can also present with primary gastrointestinal or respiratory disease as well as other primary disorders (11-16). Pulmonary involvement most likely arises via haematogenous spread from distant sites to the lungs,

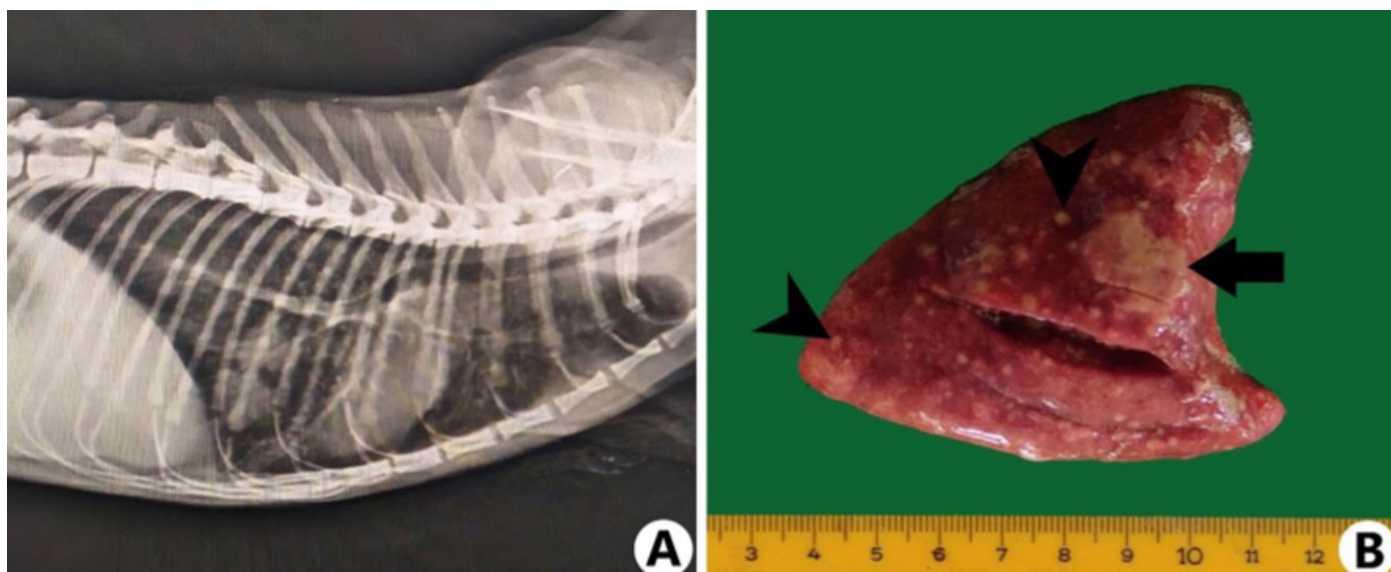


Figure 1: Radiographic and macroscopic findings. A: Lateral thoracic radiograph showing the presence of opaque foci that were widely distributed throughout the lungs. B: Medium-soft white foci measuring 2–10 mm in diameter (arrowheads) covered the surface of the lung and were present throughout the parenchyma, either multifocally or coalescing over larger extensive areas (arrow)

and pulmonary lesions are typically interstitial and extensive, causing dyspnoea and rarely progressing to coughing (4, 17).

Mycobacterial infections are recognised as a global health concern, both for humans and animals (18–20). One species known to be infected by a range of different mycobacteria is the domestic cat (12). Mycobacterial disease in domestic cats can cause many different syndromes, including tuberculosis, feline leprosy, and nontuberculous mycobacteriosis caused by nontuberculous mycobacteria (4, 21–24). A study in Great Britain included 339 cases of mycobacterial diseases in cats, from which the following bacteria were cultured: *M. microti* (19%), *M. bovis* (15%), *M. avium* (7%), and non-*M. avium* nontuberculous mycobacteria (6%); no bacterial growth in culture occurred in 53% of the cases (12). Different species cause feline mycobacterial infections, including *M. avium*, *M. tuberculosis*, *M. bovis*, and *M. microti*, of which the latter two are the most important (25, 26).

This report describes a case of primary pulmonary feline mycobacteriosis using histopathological and immunohistochemical techniques. Furthermore, this report aims to attract the attention of veterinarians and cat owners regarding this disease with zoonotic potential in terms of public health.

Case presentation

A 2-year-old, neutered, female, domestic shorthair Mackerel tabby cat was presented to a private veterinary clinic with reported hyporexia, lethargy, and dyspnea with an abdominal component. According to the anamnesis, the cat had no previous chronic disease or outdoor access, and there was no other cat in the house. For diagnostic purposes, thoracic radiography was performed. Multifocal ill-defined and sometimes confluent lesions with soft tissue opacity were

widely distributed throughout the lung parenchyma (Figure 1A). While the cat was being treated for respiratory problems, its condition gradually deteriorated, and it died 2 hours after being brought to the clinic. Following owner consent, gross post-mortem examination was performed immediately after death at the same private veterinary clinic. Macroscopic examination revealed firm white foci measuring 2–10 mm in diameter on the surface of the lung and throughout the parenchyma, which occasionally coalesced over larger extensive areas (Figure 1B). The trachea lumen was filled with a foamy serous liquid. No gross pathological findings were observed in other organs or skin. After identifying macroscopic lesions in the lung, a sample of the fresh lung tissue was submitted to the Department of Pathology, Faculty of Veterinary Medicine, Selçuk University, for further histopathological examination.

Five samples of the lesioned lung tissue were fixed in 10% neutral buffered formaldehyde solution. After routine histopathological tissue processing, tissues were embedded in paraffin and cut into 5-µm-thick sections. These sections underwent haematoxylin and eosin and Ziehl-Neelsen staining (27) and immunohistochemical staining with an anti-*M. tuberculosis* antibody (1:100, Abcam, ab214721) in a staining device (Leica, Bondmax) using the Bond™ polymer refine detection system (Leica DS9800) according to a previously reported method (28). Sections treated with phosphate buffer saline instead of primary antibodies served as negative controls. Slides were examined by light microscopy (Olympus BX51, Tokyo, Japan) and photographed (Olympus EP50, Tokyo, Japan).

Multifocal to coalescing nodular areas consisting of caseous necrosis with karyorrhectic nuclei were widely observed in the lung. Around the necrotic areas, no fibrous capsules were observed but many lymphohistiocytic cell infiltrations and alveolar oedema were seen (Figure 2A). Mineralisation

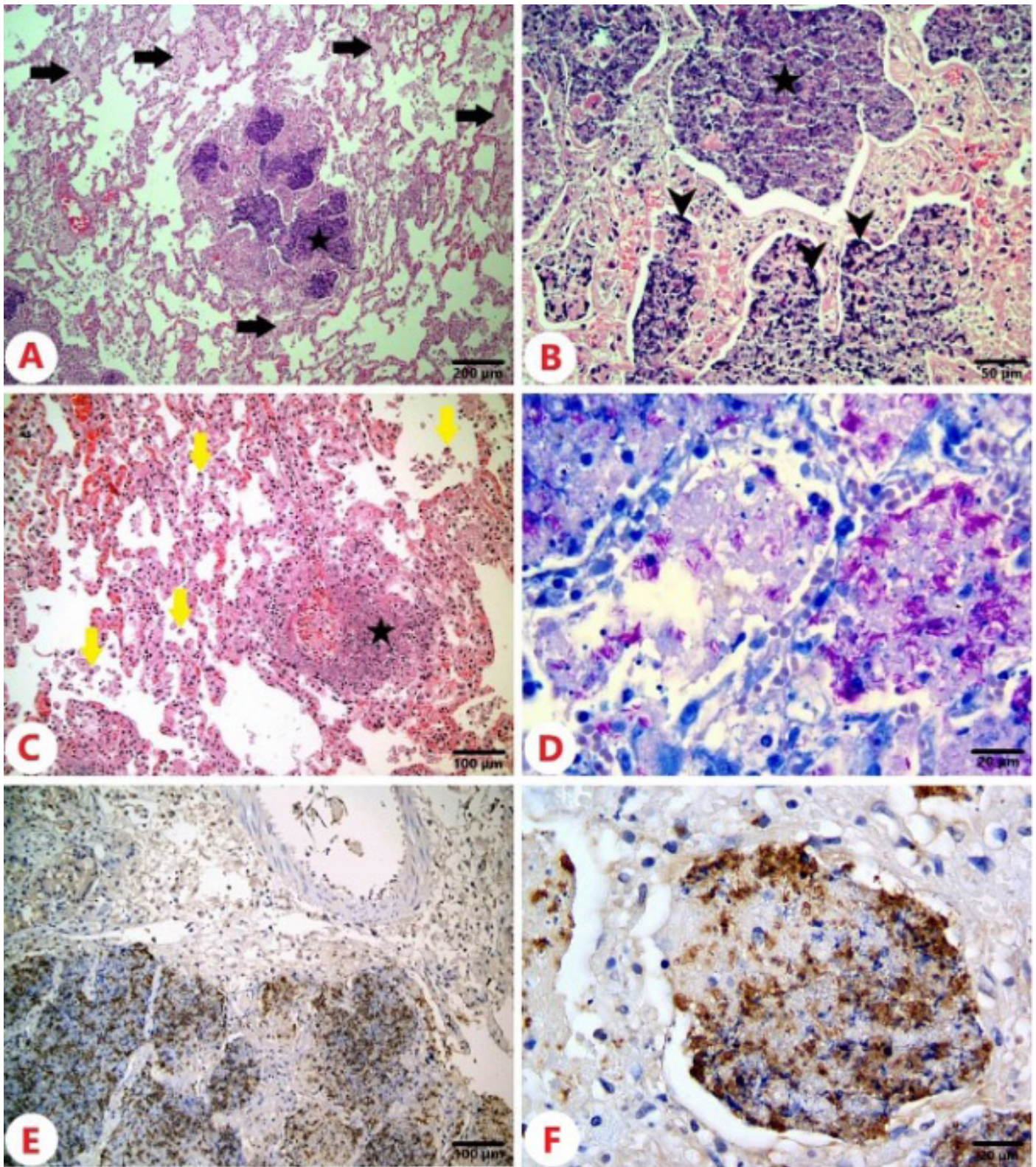


Figure 2: Histopathological and immunohistochemical findings of the lungs. A: Multifocal and coalescing nodular areas consisting of caseous necrosis without fibrous capsules (asterisk) and oedemas (arrows). Haematoxylin-Eosin staining; scale bar: 200 μ m. B: High magnification of nodular lesion: caseous necrosis (asterisk), mineralisation (arrowheads), and lymphohistiocytic cell infiltration. Haematoxylin-Eosin staining; scale bar: 50 μ m. C: Necrotic areas (asterisk) and numerous macrophages (arrows) around the vessel and necrotic vasculitis. Haematoxylin-Eosin staining; scale bar: 100 μ m. D: Acid-fast bacteria in areas of caseous necrosis. Ziehl-Neelsen staining; scale bar: 20 μ m. E: Positive immunostaining for *Mycobacterium* spp. in areas of caseous necrosis. IHC; scale bar: 100 μ m. F: High magnification of *Mycobacterium* spp. immunostaining. IHC; scale bar: 20 μ m

was observed in the areas of caseous necrosis (Figure 2B). Around the vessel, similar necrotic areas and necrotic vasculitis were observed (Figure 2C). Local haemorrhagic areas were also identified. Although there were very few epithelioid macrophages, no giant cell types were found. In the areas of caseous necrosis and in the cytoplasm of macrophages, Ziehl-Neelsen staining revealed numerous acid-fast bacilli (Figure 2D), and anti-*M. tuberculosis* immunostaining was positive (Figure 2E, F).

Discussion

This case report presents primary pulmonary mycobacteriosis in a domestic cat diagnosed using histopathological and immunohistochemical techniques. Radiography can detect pulmonary involvement in many cases of mycobacteriosis; however, the radiographic appearance of lesions is variable and nonspecific. In feline mycobacteriosis, pulmonary involvement is commonly interstitial, but may progress to bronchial changes in chronic cases (17). In the current case, diffuse interstitial changes were observed.

Mycobacterial lesions in carnivores differ from those in other species. Typical tuberculous granulomas are not as common, and when they occur, caseous necrosis is not a prominent gross feature. More often there is nonspecific granulation tissue in which macrophages are scattered at random, and giant cells are rare or absent (29). Necrosis associated with feline mycobacteriosis is called caseous necrosis and is defined as areas where cellular and structural details are lost due to the accumulation of eosinophilic and basophilic (karyorrhectic) residues (30). In the current case, mycobacterial lesions displayed caseous necrosis, in which karyorrhectic nuclei were observed, whereas giant cells were not. Few epithelioid macrophages and no evidence of a fibrous capsule were observed, which suggests a more acute infection. Macroscopic lesions were only observed in the lungs, which indicates that the route of infection was via inhalation of infectious particles.

The current case was of a domestic cat without access to the outdoors or other animals, indicating the possibility of human-to-animal transmission. Mycobacterial diseases are considered both zoonanthroponotic and zoonotic (31). If an immunocompromised individual has an active untreated mycobacterial infection, there is a potential risk of transmission to others, including cats (32). There is a theoretical risk of transmission of infection from cats to humans via infectious aerosols. However, if the cat has untreated productive respiratory disease, the greatest risk to humans is exposure to infectious fluids (33). In the current case, the presence of respiratory tract symptoms increased the zoonotic risk. In terms of public health, cats infected with mycobacteria should be examined, and necessary measures should be taken.

Conclusions

This study characterized the radiographic, pathological, and immunohistochemical appearance of primary pulmonary mycobacteriosis lesions in a cat. The purpose of this case report was to draw attention to feline mycobacteriosis, which is under-reported but increasingly recognised. Suspected or infected cats with respiratory symptoms should be examined on a regular basis because they can pose a zoonotic risk to cat owners, children, and veterinarians.

Acknowledgements

We would like to thank Erkan Aslan for performing and sharing the radiographic imaging with us. We thank dr. Eva Lasic for reviewing a draft of this manuscript.

References

1. Sakamoto K. The pathology of *Mycobacterium tuberculosis* infection. *Vet Pathol* 2012; 49(3): 423–39. doi: 10.1177/0300985811429313
2. O'Reilly LM, Daborn C. The epidemiology of *Mycobacterium bovis* infections in animals and man: a review. *Tuber Lung Dis* 1995; 76(Suppl. 1): 1–46. doi: 10.1016/0962-8479(95)90591-x
3. Schrenzel M, Nicolas M, Witte C, et al. Molecular epidemiology of *Mycobacterium avium* subsp. *avium* and *Mycobacterium intracellulare* in captive birds. *Vet Microbiol* 2008; 126(1/3): 122–31. doi: 10.1016/j.vetmic.2007.06.016
4. Gunn-Moore D, Dean R, Shaw S. Mycobacterial infections in cats and dogs. *In Pract* 2010; 32(9): 444–52. doi: 10.1136/inp.c5313
5. Rufenacht S, Bogli-Stuber K, Bodmer T, et al. *Mycobacterium microti* infection in the cat: a case report, literature review and recent clinical experience. *J Feline Med Surg* 2011; 13(3): 195–204. doi: 10.1016/j.jfms.2011.01.012
6. Palmer M. *Mycobacterium bovis*: characteristics of wildlife reservoir hosts. *Transbound Emerg Dis* 2013; 60(Suppl. 1): 1–13. doi: 10.1111/tbed.12115
7. Monies R, Cranwell M, Palmer N, Inwald J, Hewinson RG, Rule B. Bovine tuberculosis in domestic cats. *Vet Rec* 2000; 146(14): 407–8. doi: 10.1136/vr.146.14.407
8. Oztomurcuk D, Terzi O, Demirci C, Kılıçaslan Z. Investigation of granulomatous inflammations in terms of tuberculosis diagnosis: A 5-year multi-center laboratory study. *Turk Thorac J* 2022; 23(1): 11–6. doi: 10.5152/TurkThoracJ.2022.20314
9. Maxie G ed. Jubb, Kennedy & Palmer's Pathology of Domestic Animals Pathology of domestic animals. Vol. 1. St. Louis: Elsevier, 2016: 639–41.
10. Cardona P-J. The key role of exudative lesions and their encapsulation: lessons learned from the pathology of human pulmonary tuberculosis. *Front Microbiol* 2015; 6: 612. doi: 10.3389/fmicb.2015.00612
11. Jennings AR. The distribution of tuberculous lesions in the dog and cat, with reference to the pathogenesis. *Vet Rec* 1949; 61: 380–4.
12. Gunn-Moore DA, McFarland SE, Brewer JI, et al. Mycobacterial disease in cats in Great Britain: I. Culture results, geographical distribution and clinical presentation of 339 cases. *J Feline Med Surg* 2011; 13(12): 934–44. doi: 10.1016/j.jfms.2011.07.012

13. Miller M, Fales W, McCracken W, et al. Inflammatory pseudotumor in a cat with cutaneous mycobacteriosis. *Vet Pathol* 1999; 36(2): 161–3. doi: 10.1354/vp.36-2-161
14. O'Halloran C, Ioannidi O, Reed N, et al. Tuberculosis due to *Mycobacterium bovis* in pet cats associated with feeding a commercial raw food diet. *J Feline Med Surg* 2019; 21(8): 667–81. doi: 10.1177/1098612X19848455
15. Madarame H, Saito M, Ogihara K, et al. *Mycobacterium avium* subsp. *hominissuis* meningoencephalitis in a cat. *Vet Microbiol* 2017; 204: 43–5. doi: 10.1016/j.vetmic.2017.04.008
16. Stavinohova R, O'Halloran C, Newton JR, et al. Feline ocular mycobacteriosis: clinical presentation, histopathological features, and outcome. *Vet Pathol* 2019; 56(5): 749–60. doi: 10.1177/0300985819844819
17. Bennett AD, Lalor S, Schwarz T, Gunn-Moore DA. Radiographic findings in cats with mycobacterial infections. *J Feline Med Surg* 2011; 13(10): 718–24. doi: 10.1016/j.jfms.2011.06.006
18. Glaziou P, Floyd K, Raviglione M. Global burden and epidemiology of tuberculosis. *Clinics in Chest Medicine* 2009; 30: 621–36.
19. LoBue P, Enarson D, Thoen C. Tuberculosis in humans and animals: an overview. *Int J Tuberc Lung Dis* 2010; 14(9): 1075–8.
20. Shiloh MU, Champion PAD. To catch a killer. What can mycobacterial models teach us about *Mycobacterium tuberculosis* pathogenesis? *Curr Opin Microbiol* 2010; 13(1): 86–92. doi: 10.1016/j.mib.2009.11.006
21. McIntosh D. Feline leprosy: a review of forty-four cases from Western Canada. *Can Vet J* 1982; 23(10): 291–5.
22. Baral RM, Metcalfe SS, Krockenberger MB, et al. Disseminated *Mycobacterium avium* infection in young cats: overrepresentation of Abyssinian cats. *J Feline Med Surg* 2006; 8: 23–4. doi: 10.1016/j.jfms.2005.06.004
23. Horne KS, Kunkle GA. Clinical outcome of cutaneous rapidly growing mycobacterial infections in cats in the south-eastern United States: a review of 10 cases (1996–2006). *J Feline Med Surg* 2009; 11(8): 627–32. doi: 10.1016/j.jfms.2008.10.008
24. Smith N, Crawshaw T, Parry J. *Mycobacterium microti*: more diverse than previously thought. *J Clin Microbiol* 2009; 47(8): 2551–9.
25. Barry M, Taylor J, Woods JP. Disseminated *Mycobacterium avium* infection in a cat. *Can Vet J* 2002; 43(5): 369–71.
26. Pesciaroli M, Alvarez J, Boniotti M, et al. Tuberculosis in domestic animal species. *Res Vet Sci* 2014; 97(Suppl.): S78–85. doi: 10.1016/j.rvsc.2014.05.015
27. Luna L. Manual of histologic staining methods of the Armed Forces Institute of Pathology. 3rd ed. New York: McGraw-Hill Book Company, 1968: 32.
28. Ates MB, Ciftci MK, Oruc E, et al. *Mycobacterium bovis* tuberculosis in a neonatal Holstein calf. *Eurasian J Vet Sci* 2019; 35(3): 175–9. doi: 10.15312/EurasianJVetSci.2019.242
29. Maxie G ed. Jubb, Kennedy & Palmer's Pathology of Domestic Animals Pathology
30. Mitchell J, Del Pozo J, Woolley C, Dheendsa R, Hope JC, Gunn-Moore DA. Histological and immunohistochemical (muco) cutaneous feline tuberculosis lesions. *J Small Anim Pract* 2022; 63(3): 174–87. doi: 10.1111/jsap.13386
31. Lloret A, Hartmann K, Pennisi MG, et al. Mycobacterioses in cats: ABCD guidelines on prevention and management. doi: 10.1177/1098612X13489221
32. Ramdas KE, Lyashchenko KP, Greenwald R, Robbe-Austerman S, McManis C, Waters R. *Mycobacterium bovis* infection *Emerg Infect Dis* 2015; 21(3): 480–3. doi: 10.3201/eid2103.140715
33. O'Connor CM, Abid M, Walsh AL, et al. Cat-to-human transmission of *Mycobacterium bovis*, United Kingdom. *eid2512.190012*

Primarna pljučna mikobakterioza pri mački: imunohistokemična in histopatološka ocena

Osman Dağar, Mehmet Burak Ateş, Mustafa Ortatli, Ertan Oruç

Izvelek: V tem poročilu o primeru je bila ocenjena primarna pljučna mikobakterioza pri domači mački z uporabo histopatoloških in imunohistokemičnih metod. Mačka je bila sprejeta v zasebno veterinarsko kliniko zaradi simptomov hiporeksije, letargije in dispneje z abdominalno komponento. Za diagnostične namene je bila opravljena rentgenska preiskava prsnega koša, ki je pokazala prisotnost motnih žarišč, široko razporejenih po pljučih. Stanje mačke se je postopoma slabšalo, umrla je dve uri po prihodu v kliniko. Po privolitvi lastnika je bila takoj po smrti opravljena raztelesba. Bela žarišča, premera od 2 do 10 mm, so prekrivala površino pljuč. Prisotna so bila po celotnem parenhimu večinoma multifokalno in mestoma zlivajoče. V drugih organih in na koži ni bilo opaznih drugih makroskopskih patoloških sprememb. Nekateri dele pljučnega tkiva z makroskopskimi spremembami smo dodatno histopatološko in imunohistokemično pregledali. Opazili smo multifokalna do zlivajoča se območja kazeozne nekroze (brez fibrozne kapsule) s karioznimi jedri in številnimi makrofagi. Ziehl-Neelsenovo barvanje je razkrilo številne acidofilne bakterije. Imunohistokemično barvanje je pokazalo pozitivno imunobarvanje za *Mycobacterium* spp. To poročilo o primeru poudarja pomen upoštevanja zoonotskih tveganj pri mačkah z diagnozo primarne pljučne mikobakterioze.

Ključne besede: mikobakterioza mačk; imunohistokemija; histopatologija; pluća