

## Ontogenetic development of dentition in the cave bear

### Ontogenetski razvoj zobovja pri jamskem medvedu

Irena Debeljak

Ivan Rakovec Institute of Palaeontology,  
Scientific Research Centre of the Slovenian Academy of Sciences and Arts,  
Gosposka 13, SI-1000 Ljubljana, Slovenia

**Key words:** *Ursus spelaeus*, Ursidae, dentition, jawbones, ontogenetic development, growth, age determination, sex dimorphism, mortality, Divje babe I

**Ključne besede:** *Ursus spelaeus*, Ursidae, zobovje, čeljustnice, ontogenetski razvoj, rast, določanje starosti, spolni dimorfizem, mortaliteta, Divje babe I

#### Abstract

In this contribution the ontogenetic development of dentition in the cave bear (*Ursus spelaeus* Rosenmüller & Heinroth) is described up to the age of about four years, when the animals became adult and the formation of their teeth was completed. The process of tooth growth and the replacement of deciduous teeth by permanent dentition took place in a similar way as with the present-day brown bear (*Ursus arctos* Linné). The teeth eruption sequence is the same in both species.

The specimens of cave bear jawbones that served for this study were collected from the well-known Palaeolithic site Divje babe I (W Slovenia). Individual age estimations of these jawbones were made on the supposition that a certain ontogenetic stage in the development of cave bear dentition corresponds to an approximately equal age of an individual as with the brown bear. The growth of the jaw, however, was essentially faster in cubs of the cave bear. We also presume that the secondary sex dimorphism in cave bears with males having larger jawbones than females was already expressed in the first year of life.

With regard to some indices, especially after noting the obvious discordance between the expected and actually observed mortality profile, we should also consider another possibility; that ontogenetic development in the cave bear was significantly slower than in present-day bears. However, this alternative does not seem very probable, because a proper ontogenetic development has its functional importance. A long time lag in the eruption of permanent molars would mean a certain disadvantage to the species.

#### Kratka vsebina

V prispevku je opisan ontogenetski razvoj zobovja jamskega medveda (*Ursus spelaeus* Rosenmüller & Heinroth) vse do starosti približno štirih let, ko so živali odrastle, njihovi zobje pa so bili dokončno formirani. Proces rasti zob in zamenjave mlečnega zobovja s stalnim je pri jamskem medvedu potekal na podoben način kot

pri današnjem rjavem medvedu (*Ursus arctos* Linné). Zaporedje izraščanja zob je pri obeh vrstah enako.

Primerki čeljustnic jamskega medveda, na katerih je opisan ontogenetski razvoj zobovja, so iz znanega paleolitskega najdišča Divje babe I (W Slovenija). Individualno starost teh čeljustnic smo ocenili glede na domnevo, da določena ontogenetska stopnja v razvoju zobovja jamskega medveda ustreza približno isti starosti osebkov kot pri rjavem medvedu. Rast čeljusti pa je bila pri mladičih jamskega medveda vendarle bistveno hitrejša. Domnevamo tudi, da je bil pri jamskih medvedih sekundarni spolni dimorfizem izražen že v prvem letu življenja; samci so imeli večje čeljusti od samic.

Glede na nekatere pokazatelje, še posebej po očitnem razhajanju med pričakovanim in dejansko ugotovljenim mortalitetnim profilom, bi morali upoštevati tudi drugo možnost; da je bil ontogenetski razvoj zobovja jamskega medveda bistveno počasnejši kot pri današnjih medvedih. Vendar, ta alternativa se ne zdi zelo verjetna, ker ima primeren ontogenetski razvoj svoj funkcionalen pomen. Dolg časovni zaostanek pri izraščanju stalnih molarjev bi za vrsto pomenil določeno pomanjkljivost.

## Introduction

In contrast with the phylogenetic evolution, the ontogenetic evolution of cave bear dentition has not been explicitly described so far, and it is generally little known to the professional public.

Most researchers of the cave bear limit themselves to the statement that a certain jawbone is juvenile, which means that it belonged to a cub. Only seldom do the authors (as Rădulescu & Samson, 1959) accompany the photographs or descriptions with more detailed information on the age of the cub. The latter can be estimated by comparison with the present-day brown bear. In the present work all data on teeth eruption in the brown bear are collected that are important for determining the individual age of juvenile jawbones of the cave bear and of other bear species as well.

The reason for interest in the age determination of relatively rare juvenile jawbone finds is not simple curiosity. Palaeontologists and archaeologists are also interested in the behaviour of cave bears and the environment in which they lived, especially including the relationship between prehistoric man and bear. From this point of view, the precise assessment of individual ages of jawbones that belonged to cubs less than one year old offers us very important information, i.e. on the season in which the animals died.

By all means, the most accurate data on cave bear mortality can be achieved by the age analysis of single, isolated teeth found in tens of thousands in those Palaeolithic cave sites that had also served as typical dens of the cave bear. The individual age of particular juvenile teeth can be correctly estimated, however, only after previous study of their development and degree of formation at various ages on the set of the whole jawbones.

Exactly this was the primary reason for our analysis of the jawbones of cave bear cubs from the Palaeolithic locality Divje babe I. This study was the basis for our further research on the age structure of the cave bear population from the upper part of the Pleistocene deposits (Debeljak, 1996a, 1997). The age analysis was carried out on isolated deciduous teeth  $d_4$  and permanent teeth  $M_1$ . Therefore in the present paper a more detailed description of the ontogenetic development of these teeth is given.

### Previous research

Ehrenberg was the first to study the ontogenetic evolution of the cave bear. He established the identity of the ontogenetic stages of dentition with those of the brown bear (1931, 640). He described the different steps in the development of mandibles, and he approximately estimated their individual ages (1931, 659–675, 701–703). In those times only scarce data were available on tooth growth in the brown bear, so it is understandable that Ehrenberg's age estimates were imprecise. He concluded that in the well-known locality Drachenhöhle near Mixnitz many remains belong to cubs that perished from exhaustion prior to spring – less than 4 months old. According to Ehrenberg, this age-class was followed by a long gap after which appeared the group of most numerous remains of cubs about 1 year old. The supposed mortality peak at that age was explained as the consequence of complications in eruption of the last, i.e. distal molars. Ehrenberg's interpretation of the presumed absence of remains of 4–10-month-old cubs was that cave bears occupied caves only in winter, during hibernation. This opinion has prevailed among researchers until the present day. Former spectacular ideas of cave bear hunting were withdrawn by sober scientific judgement.

After 30 years Ehrenberg obtained good comparative data for the present-day brown bear. He attributed the age of 7 months to an almost complete skeleton of a cave bear cub from Hartlesgraben (1964, 217–219). In the same contribution he corrected age estimates of certain mandibles made in 1931. Nevertheless, he remained convinced about the existence of the above-mentioned gap in the age composition of the cave bear remains while explaining the rare remains of 4–10-month-old cubs as an exception that confirms the rule.

Musil (1965, 72) sorted the juvenile jawbones of cave bears from the Pod hradem cave according to their progressive ontogenetic development, and described them in detail. However, he did not determine their individual ages.

### Material and methods

The ontogenetic development of cave bear dentition will be described on eleven examples of jawbones from the Palaeolithic site Divje babe I, which is located below the edge of the plateau Šebreljska planota, above the Idrijca River valley (W Slovenia). The larger part of Pleistocene deposits in the cave originate from the Middle Würm period. All fossil cave bear remains from the Divje babe I are kept in the National Museum of Slovenia in Ljubljana. General information on the locality can be found in Turk et al., 1989a, b and Turk ed., 1997.

Age estimations of individual jawbones were made according to Dittrich's (1960) comprehensive data set on present-day bears, and the comparisons with juvenile jawbones of the brown bear from Slovenia. The sex was determined from the size of the teeth, especially of canines, according to the works of Koby (1949) and Kurtén (1955).

Some facts on the living habits of the brown bear that can also be attributed to its relative the cave bear are summarized from Macdonald ed., 1985, 88–95 and Kryštufek, 1991, 191–193.

### Jawbones and teeth of the cave bear – general

The lower jaw of bears consists of two mandible bones (i.e. hemimandibles or mandibles). They are joined in a symphysis that never ossifies. The upper jaw is formed on each side by two paired bones: the premaxilla that bears the incisors and extends to the canine, and the upper jawbone or maxilla. These two bones are fused only in grown up individuals. In jawbones tooth sockets or alveolae appear in which tooth roots are attached.

The brown bear as well as the cave bear have in both jaws on each side the following deciduous teeth: 3 incisors (di1–3), one canine (dc) and usually 3 premolars (d2–4 or p2–4). On each side of the lower jaw of the cave bear the following permanent teeth are present: three incisives ( $I_{1-3}$ ), one canine (C), usually a single premolar ( $P_4$ ) and three molars ( $M_{1-3}$ ). In the maxilla there is one molar less.

The molars have a broad masticatory surface with numerous low, rounded cusps. Early researches into the morphology of dentition and the skull revealed that the cave bear was almost exclusively vegetarian in habits (cf. Kurtén, 1976). Recent isotopic analyses confirmed this hypothesis (Bocherens et al., 1994).

The permanent dentition of bears was described in detail by Rode (1935). Koby (1952) and Rădulescu and Samson, (1959) described the deciduous dentition of the cave bear.

For the orientation of jawbones and teeth a variety of terms is used. In this paper the following terms are met: Front – anterior – mesial. Back – posterior – distal. (This is simplified! The listed terms are not equivalent generally.) Side facing the cheeks – buccal – lateral. Towards the tongue – lingual (in the mandible) or palatal (in the maxilla). The biting (upper) surface or edge of the teeth is called occlusal.

### The ontogenetic development of dentition in bears (family Ursidae)

Certain data on the eruption of permanent teeth in present-day bears can be found in the following references: Pohle, 1923; Couturier, 1954; Rausch, 1961; Marks and Erickson, 1966. However, the most detailed study of the development of deciduous dentition and its replacement by permanent teeth in the brown bear was done by Ditttrich (1960). He established that this process is practically the same and also synchronous in other bear species. The succession of eruption of individual teeth from the gums is presented in figure 1. Ditttrich's other data on the ontogenetic development of dentition in bears can be summed up in the following principal points:

The cubs are born toothless. The first milk teeth start erupting during the second month of life, and they come into position during the third month. The first permanent molars start piercing through the gum in the fifth month of life. The cubs are able to chew solid food only after they get the first pair of permanent molars ( $M_1$  &  $M^1$ ). The deciduous dentition has almost no functional meaning in chewing. The deciduous teeth are shed by the end of the 15th month. The eruption of the last permanent teeth is accomplished at a mean age of one year and a half.

Ditttrich (1960, 119–123) found out that the body weight in bears generally does not influence the growth and the rate of eruption of teeth. Also individual differences in this process are relatively small (see fig. 1).

The disposition of deciduous and permanent teeth in the jaws of a brown bear cub is illustrated by figs. 2a and 2b.

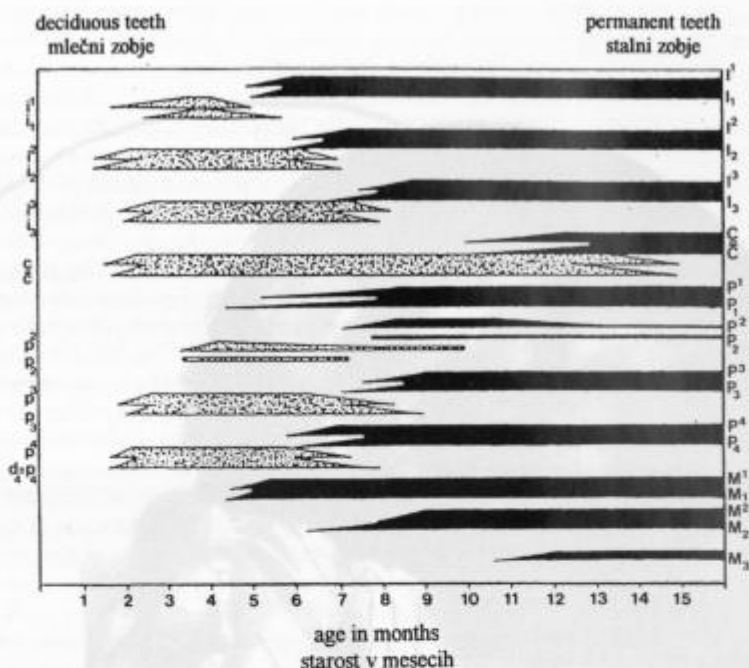


Fig. 1. Ontogenetic development of dentition in the brown bear up to the age of 16 months (after Dittrich, 1960, 86, fig. 27). Individual deciduous teeth (left) are marked with a dotted pattern, and permanent teeth (right) with black. An arrow at the beginning or at the end of the symbols indicates the period in which the start of eruption of milk and permanent teeth, or shedding of milk teeth could take place. The length of the arrow therefore illustrates individual differences

Sl. 1. Ontogenetski razvoj zobovja pri rjavem medvedu do 16. meseca starosti (po Dittrichu, 1960, 86, sl. 27). Posamezni mlečni zobje (levo) so označeni pikčasto, stalni zobje (desno) pa s črno barvo. Konica na začetku in koncu simbolov nakazuje obdobje, v katerem lahko pride do začetka izraščanja mlečnih in stalnih zob oziroma do izpada mlečnih zob. Dolžina konice torej ponazarja individualne razlike

## The ontogenetic development of dentition in the cave bear

### *The first three months*

Osteological remains of unborn animals (fetuses) and of those cubs who died at birth or shortly thereafter (neonates), are preserved only exceptionally in the Pleistocene localities. Nevertheless, such finds are not so rare in the Divje babe, because the cave served for long millenia as a den, especially to cave bear females who whelped their young in the winter months from December to February (Turk et al., 1989b; Debeljak, 1997). The thin and fragile (owing to porosity) mandibles of still unborn or newborn bears are 2–3 cm long and only around 5 mm wide.

Cave bear young were born toothless. The same is true in present-day bears. Already in the first week of the brown bear's life, the germs of deciduous teeth can be

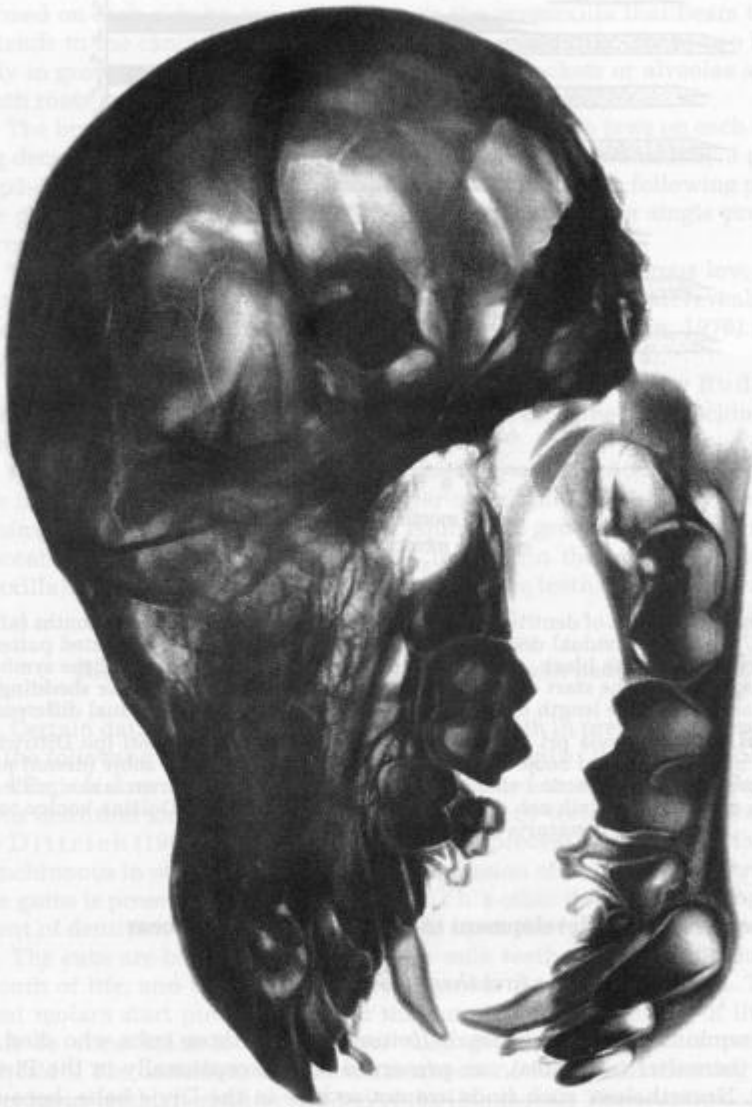


Fig. 2a. X-ray photograph of the skull of an approximately four-month-old brown bear cub from the Pyrenees (after Couturier, 1954, 142, Pl. 30). The individual age was estimated after Dittrich's (1960) data. Natural size  
 Sl. 2a. Rentgenski posnetek lobanje približno štiri mesece starega rjavega medveda s Pirenejev (po Couturieri, 1954, 142, tab. 30). Ocena starosti po Dittrichovih (1960) podatkih. Naravna velikost

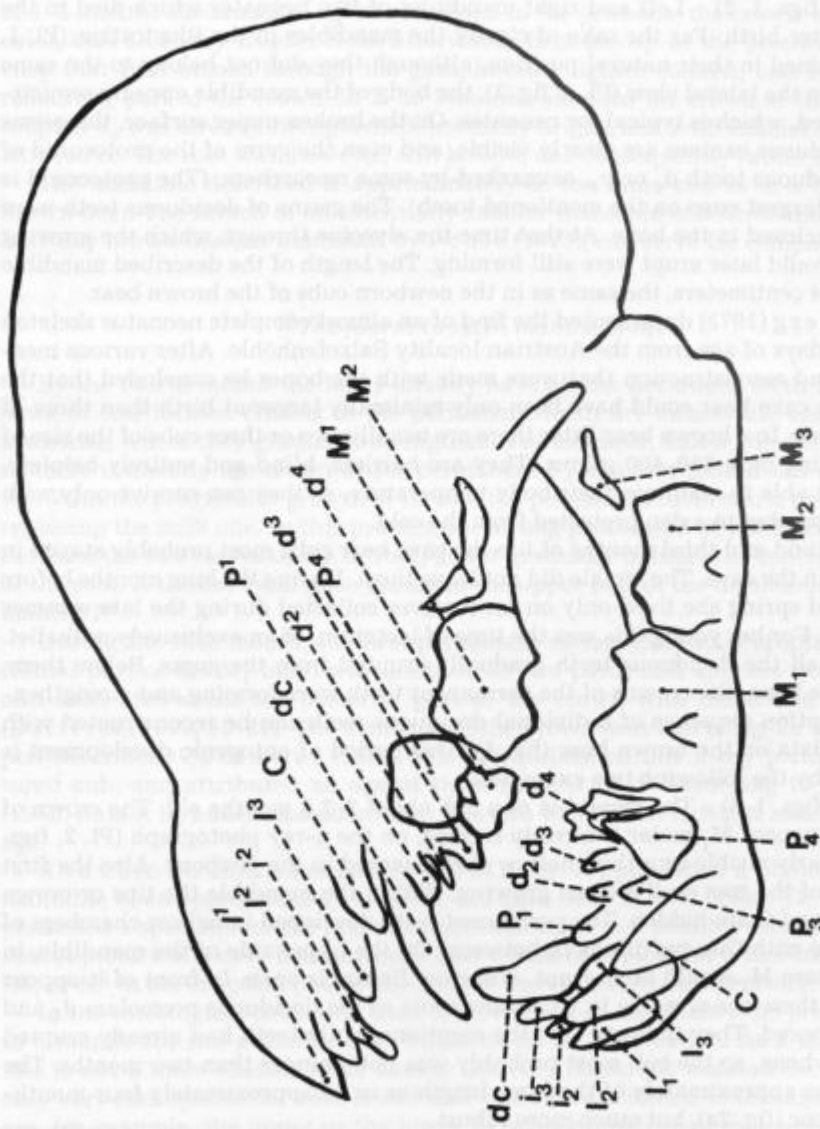


Fig. 2b. Schematic illustration of fig. 2a (modified after Couturier, 1954, 143, Pl. 30). Small letters mark deciduous teeth, and capital letters permanent teeth

Sl. 2b. Shematska ponazoritev slike 2a (prirejeno po Couturiero, 1954, 143, tab. 30). Male črke označujejo mlečne zobe, velike črke stalne zobe

found in preparations of their jaws: small, hollow caps of crowns that had not yet erupted from the gums (Dittrich, 1960, 11, figs. 1, 2). This neonatal phase of the ontogenetic evolution is represented by the following example:

1. (Pl. 1, figs. 1, 2) - Left and right mandibles of two neonates which died in the first days after birth: For the sake of clarity the mandibles in the illustration (Pl. 1, fig. 1) are joined in their natural position, although they did not belong to the same individual. In the lateral view (Pl. 1, fig. 2), the body of the mandible appears semicircularly curved, which is typical for neonates. On the broken upper surface, the germs of both deciduous canines are clearly visible, and even the germ of the protoconid of the last deciduous tooth  $d_4$  or  $p_4$ , as marked by some researchers. (The protoconid is the central, largest cusp on the mentioned tooth). The germs of deciduous teeth were originally enclosed in the bone. At that time the alveolae through which the growing milk teeth would later erupt were still forming. The length of the described mandible was around 4 centimeters, the same as in the newborn cubs of the brown bear.

Ehrenberg (1973) documented the find of an almost complete neonatus skeleton of about 10 days of age from the Austrian locality Salzofenhöhle. After various measurements and reconstruction that were made with the bones he concluded that the young of the cave bear could have been only minimally larger at birth than those of the brown bear. In a brown bear litter there are usually two or three cubs of the size of a rat, weighing only 350-400 grams. They are hairless, blind and entirely helpless. They are not able to maintain their body temperature, so they can survive only with their caring mother in a den protected from the cold.

In the second and third months of life the cave bear cubs most probably stayed in the den, i.e. in the cave. The female did not leave them. During the long months before the advent of spring she lived only on fat reserves collected during the late summer and autumn. For her young this was the time of lactation, of an exclusively milk diet. Meanwhile, all the deciduous teeth gradually erupted from the gums. Below them, hidden in the bone, the crowns of the permanent teeth were forming and strengthening. The eruption sequence of individual deciduous teeth can be reconstructed with the help of data on the brown bear (fig. 1). This period of ontogenic development is represented by the following two examples:

2. (Pl. 2, figs. 1-3) - The mandible of a cub about 2-2.5 months old: The crown of the first permanent  $M_1$  molar is already formed; on the x-ray photograph (Pl. 2, figs. 2, 3) it is clearly visible as a thin, hollow shell encased in the jawbone. Also the first millimeters of the root wall started growing. Within the mandible the tips or crown germs of  $P_4$  and  $C$  are hidden. The permanent teeth developed in hollow chambers of the mandible with thin partitions in between. On the upper side of the mandible, in the place where  $M_1$  would later erupt, a narrow fissure is open. In front of it appear small holes; these are alveolae in which the roots of the deciduous premolars  $d_4$  and  $d_3$  were anchored. They indicate that the mentioned milk teeth had already erupted from the jawbone, so the cub most probably was not younger than two months. The mandible was approximately of the same length as in an approximately four-month-old brown bear (fig. 2a), but much more robust.

3. (Pl. 3, figs. 1-3) - Both halves of the mandible of a cub about 2.5-3 months old: The furrow broadened in the place where in a month or two  $M_1$  would start erupting. Observed from above, the dark crown of  $M_1$ , fragile like an egg shell, is visible through it. The upper quarter of the  $M_1$  root was already formed (Pl. 3, figs. 2, 3); it is as thin as paper however. Also the crowns of the permanent incisors and the germs of  $C$  and  $P_4$  teeth are concealed in the jawbone. On the upper side of the mandible the



alveolae of deciduous teeth are clearly visible. At this age almost all the deciduous teeth were in place, although they are not preserved here in this specimen. (The process of the eruption of milk teeth can be illustrated on an example of  $d_4$ : at the age of 1–2 months the crown of  $d_4$  was enclosed in the jawbone; the crown was brown in color, dull and very fragile. Soon afterwards first the tip of the protoconid, i.e. the cusp that first breaks through the gum, became lighter colored, and later also the remaining part of the crown. In 2- to 3-month-old cubs the crown of the completely erupted  $d_4$  was already strengthened, normally bright, and with enamel of characteristic lustre. The root was, however, still hollow, and consequently rather fragile.)

The mandible described is approximately of the same size as in a half-year-old brown bear. The sketch of an essentially smaller mandible of a three-month-old present-day brown bear, as published by Pohle (1923), can serve for comparison.

#### *The fourth to sixth months of life*

By the fourth month the bears already have all the deciduous teeth in place. The more or less formed crowns of the permanent teeth are meanwhile enclosed in the jawbones, where they gradually strengthen. For example, below the deciduous tooth  $d_4$  there is already the crown of the permanent  $P_4$  in a four-month-old cub (figs. 2a, 2b). With the progressive growth of its root the permanent tooth starts protruding and replacing the milk one. In this process, the strong protoconid of the  $P_4$  crown wedges between the two halves of the  $d_4$  root, and it gradually induces the contact resorption of the root. A similar result also occurs in the upper pair of the deciduous  $d^4$  and permanent  $P^4$ .

During the fifth month, the first permanent molars ( $M_1$ ) start erupting. First the frontal part of the  $M_1$  tooth with protoconid and paraconid appears from the gums, and soon afterwards the posterior part of the crown with metaconid and talonid (Dittrich, 1960, 80–81). The dentition of the brown bear cub in fig. 2a is in the stage just described. Couturier (1954, 142–143) published this x-ray picture of a captured cub, and attributed an age of three months to it. According to Dittrich's (1960) data it is, however, evident that this cub was in fact older, at least 4 months of age.

Rădulescu and Samson (1959, 211, fig. 11) published a photograph of the mandible of an approximately 4-month-old cave bear. Musil (1965, 72, Pl. 3, fig. 10) presented a specimen of the mandible that belonged to a possibly somewhat younger cub. A picture of a cave bear jawbone that would be typical for a five-month-old cub ( $M_1$  or  $M^1$  in the eruption phase) has not yet been found in the literature.

In the osteological collection from the Divje babe I site there is no jawbone of a 4- to 5-month-old cub available that would be fit for publication. As a matter of fact, this is not a mere chance, since among the very numerous isolated deciduous teeth only very rare specimens were found that could be attributed to this age class. (Such are, for example, the upper or the lower  $d_4$  with strengthened root which is already somewhat resorbed at the apex. Individual cusps on the crown are rounded, and often bear tiny wear facets. Debeljak, 1996a, 1997). Evidently the mortality of four- to five-month-old cubs in the Divje babe cave was much lower than at the younger age.

The present contribution does not intend to discuss possible reasons for varying mortality rates during the year. It should only be mentioned that the fourth to sixth month of life was the time of spring. The brown bear cubs accompanied by their

mother leave the den after the third month, in April or May, at times as late as the beginning of June. The same practice was probably true of the cave bear.

In addition to the milk sustenance that they get from their mother, the living bears also begin to chew solid food, starting at the fifth or sixth month. This becomes possible only after they get the first pair of permanent molars (Dittrich, 1960, 14–15). The small, pointed milk teeth are of little use for chewing. Only the new back-teeth can provide the necessary mastication surface.

#### *The seventh and eighth months of life*

Summer finally arrived. For the whole bear family came the time of intensive feeding. In the following months they had to collect a sufficient amount of fat, necessary for survival through the next winter. The dentition of 6–8-month-old cubs were then in the following condition:

4. (Pl. 4, figs. 1–5) – The mandible of a female approximately 6–7 months old: Considerable progress is evident, as compared to the specimen discussed earlier (Pl. 3). The crowns of all the permanent teeth are already formed. Later they would not grow any more, but only become stronger with the secondary dentine which was gradually filling their interior. The  $M_1$  of this cub has been “in place” for a month or so, and it has more than 4/5 of the crown developed. The crown is moderately strengthened, but the root is still entirely hollow and open at the apexes (Pl. 4, fig. 5).  $M_1$  shows the first signs of wear, which indicates that the animal had already chewed hard food for some time. As a consequence of chewing numerous tiny wear facets developed, showing a characteristic glossy surface. It is obvious that the ontogenetic development of the individual teeth progressed at different rates, in accordance with the data for the brown bear presented in fig. 1. The  $M_1$  surpassed the other permanent teeth in development. It is followed by  $I_1$ , which was at that time already in place, but is not preserved here.  $I_2$  emerged through the gum shortly before the cub died.  $P_4$  and  $M_2$  were just prior to the eruption phase. The tops of their crowns are already of lighter color. The last incisor  $I_3$  is still enclosed in the mandible, and can be seen only on the x-ray photograph. The same applies to the canine that has only the crown, but not yet the root. In this phase of growth,  $P_4$  was pushing the overlying  $d_4$  and  $d_3$  deciduous teeth from the jaw. Their roots were at that time already strongly resorbed. At the latest in a month or so  $d_4$  (not preserved in our specimen) would fall out in a natural way with an entirely resorbed root. (In bears, the last deciduous premolar  $d_4$  is in use for a short period only. It takes part in chewing solid food for only about 3 months, therefore its occlusal surface is scarcely ever heavily worn away.) The size of the described mandible corresponds to a brown bear cub about one year old (Pl. 9, fig. 1; Pl. 10, fig. 2).

**Are our age estimates correct?** Was the development of dentition in the cave bear faster, or perhaps slower than in the living brown bear? Let us discuss this problem with reference to the example of the above described mandible:

It is physiologically necessary that in the sixth or at least in the seventh month the ontogenetic development results in the inclusion of the first pair of permanent molars in dentition. This is valid for the present-day brown bear, and could not have been much different for the cave bear. As already mentioned, during the transition to solid plant food the most important part is assumed by the first permanent molars  $M_1$ . The mother's milk gradually ceases to suffice for growth, and the cubs have to start feeding on solid food, too. The deciduous teeth, with the exception of the last  $d_4$  premo-

lars, are so tiny that they have practically no functional importance for chewing hard plant food (Dittrich, 1960, 14–15, 50, 81–82).

The age of the described mandible of the cave bear, therefore, cannot differ much from our estimate. In the case of a much higher age,  $M_1$  with its chewing surface would not be "in place" soon enough to enable adequate feeding, so that the growing cub could make the best use of the summer and autumn food supply. On the other hand, the size of the mandible and the wear of  $M_1$  that could not be caused by mere milk nutrition testify against a lower age. Perhaps this could be proven by isotopic analyses of dental tissues.

In my opinion errors in the age estimates are not large, and certainly not essential. I consider that concerning the ontogenetic development of cave bear dentition, the comparison with the brown bear is appropriate.

5. (Pl. 5, figs. 1, 2) – The mandible of a male bear about 6.5–7.5 months old: The size of the mandible is almost equal to that of a brown bear at the age of a year and a half (Pl. 16, figs. 1, 2; Pl. 18, fig. 1). The anterior part of  $M_2$  protrudes out of the jawbone. The enamel becomes lighter in color during this process. In the canine the wall of the root has just started forming. The crown of  $M_3$  is enclosed in the ascending mandibular branch (i.e. ramus mandibulae), and is consequently of typical dark brown color, without lustre. A thin bone wall above  $M_3$  is broken, so it can be observed that the occlusal surface is turned lingually (inwards, towards the tongue), and it stands almost vertically with the anterior part oriented downward. Only after subsequent growing of the jawbone would the space for the two distal molars be created. (In bears,  $M_3$  rotates 90° in two directions in order to be included in the tooth row, while the jaw grows to accommodate it.)

6. (Pl. 6, figs. 1–4) – The mandible of a female about 6.5–7.5 months old: The jawbone belonged to a cub of a similar age as in the previous case, it was possibly only a trifle older.  $M_1$  was for a time "in place" and in use. For this reason its crown bears shallow wear facets approx. up to 3 millimeters in size. The root wall is almost entirely formed, but still open at the ends (Pl. 6, fig. 4). More than half of the  $M_2$  crown already protrudes from the mandible, and about one half of the root is formed. Its wall is very thin, and the interior hollow (Pl. 6, fig. 4). The  $M_1$  root is more developed and firm; the wall is about one millimeter thick. In the same phase of the ontogenetic development or at the same age, the last lower  $M_3$  molar has no root at all, and the thin, flat crown of this tooth could easily be broken in pieces (cf. Pl. 5).

It is quite obvious that individual teeth of the same cub were developed to various stages, they were, therefore, of varying mechanical resistance, and consequently did not have equal possibilities to be preserved as fossils. In analyses of various isolated teeth we should take into account different degrees of taphonomic losses. Such differences occurred either as a result of the diverse shapes and sizes of individual teeth, or owing to various degree of ontogenetic development, which meant unequal firmness at a certain age.

It is interesting to compare the mandible sizes in plates 4–6 (and also 11–15). Normally, the size of the bone depends upon the age of the individual. However, it is noticeable that the mandible size can be rather variable at a similar age as well – in proportion to the size of permanent teeth. The latter occupy practically the entire jawbone, as can be clearly seen on the x-ray photographs. Larger dentition also requires more space. The following conclusions can be made:

1. The cave bear had markedly larger sized dentition than the present-day brown bear. It is understandable that its jaws had to be much larger and more robust in the

same ontogenetic phase and age. Although the cave bear cubs were as small at birth or perhaps only minimally larger than those of the brown bear, the growth of their jaws in the following months was essentially faster. For instance, it was indicated that the mandible of a cave bear hardly much older than half a year (Pl. 5) can be of the same size as that of a one-and-a-half-year-old brown bear. Was the rest of the body also that much larger? Most probably one cannot reckon with such a rapid growth of the body mass in cave bear cubs. The female could hardly breed two or even three such big cubs during the first half-year when their diet was predominantly milk. It is more probable that the cubs had distinctly large jaws. Therefore, the jaws/body ratio must have been essentially higher than in adult cave bears, and larger than in brown bear cubs. Confirmation of this supposition is found in the only extant precisely described and measured skeleton of an approximately seven-month-old cave bear cub (finds of this kind are extremely rare!). The author of the article, Ehrenberg (1964, 243–244), was surprised to discover that the facial part of the skull was much larger than one would expect with regard to the cranium, short trunk and weak thorax. The reconstruction revealed that at a total length of 60 cm and height of 30 cm more than one third was occupied by the head (Ehrenberg, 1964, 223). It seems that the most probable reason for such a "disproportion" was the functional development of dentition that must have been as fast as with the present-day brown bear. During this process the jawbone size was consequently adapted to the growing dentition.

2. Cave bear males have on the average larger teeth than females. This holds especially for the canines, according to the size of which the sex can be determined (Koby, 1949; Kurtén, 1955). In cubs the wide crown base and its growing root occupy a very large part of the jawbones. It is clear in x-ray photographs that the height and thickness of the mandible body at a particular age clearly depend precisely on the size of the canines. Numerous specimens from the Divje babe indicate that in the same ontogenetic phase the mandibles of females are smaller and more gracile than those of males. Accordingly, it could be inferred that sexual dimorphism in cave bear mandibles was already manifested during the first year of life. We must also consider another possibility: that the development of permanent dentition in males lagged behind that in females. However, if such differences existed at all, they could have not been essential for the above-mentioned reason: the young must get their permanent teeth in place at a certain age to be able to feed properly. Also in present-day bears no important differences between the sexes were observed in the process of teeth growth during the first year (Dittrich, 1960; Marks & Erickson, 1966, 393).

At least one example will represent the upper dentition:

7. (Pl. 7, figs. 1–3) – The premaxilla and maxilla of a male approximately 6.5–7.5 months old: both bones are not fused at this particular age. In present-day bears they become inseparable in adult animals – after the 4th year (Marks & Erickson, 1966, 398–400). The  $M^1$  crown shows the first signs of wear. According to the shape of the alveola,  $P^4$  must have been just in the eruption phase; most of the crown probably already protruded out of the jawbone. Of the incisors only  $I^2$  is preserved. Shortly before the cub died it had probably already pierced the gum with the tip of its crown. The tooth socket of the  $I^1$  root is not damaged, which permits the observation on the completed eruption of the tooth. By contrast, the narrow aperture of the  $I^3$  alveolus proves that the eruption of this incisive had not yet started. Above this alveolus the shallow alveolus of the deciduous  $di^3$  is also preserved; at that age the tooth was still

in the gum, but would have dropped out of the gum in a month or so. The upper canine is hidden in the maxilla. In the x-ray photograph (Pl. 7, fig. 3) it can be seen that its root had not yet started to form. The crown is hollow and is still situated much below, or better, above the rim of the upper jawbone. The deep root socket of the deciduous eye-tooth is entirely preserved and separated completely by a solid bone wall from the developing crown of the permanent canine. Therefore we presume that the root of the deciduous canine in this phase of the ontogenetic development still did not display signs of contact resorption.

Before we end the description of ontogenetic development in the seventh and eighth months of life, another curiosity should be mentioned: Among the juvenile jawbones from the Divje babe I, most specimens belong precisely to the age period being discussed, although according to other researchers (Ehrenberg, 1931, 1964; Kurtén, 1958, 1976) the remains of 7-month-old cubs that died in the middle of summer must have been a real rarity. The general conviction of the last few decades is that the massively preserved remains of the cave bear in typical Pleistocene cave sites are of animals that died of exhaustion during long hibernation - in winter and mostly just before spring. However, also the analysis of isolated  $d_4$  and  $M_1$  teeth (Debeljak, 1996a, 1997) indicated that a remarkably high proportion of the fossil population belongs to cubs that perished presumably at an age of 6-8 months, between July and September. The Divje babe as a typical cave bear site does not represent any exception. Such results about the age structure of the fossil population are therefore surprising and unexpected. We could explain them in two different ways:

a) Our age estimates of the individual jawbones (and consequently also of isolated juvenile teeth) are not correct, and the most frequent age group of 7-month-old animals actually represents those cubs that died during their second hibernation. In this case, the ontogenetic development of cave bear dentition should lag as much as 6 months behind the ontogenetic development that was ascertained for present-day bears. According to the feeding habits and needs in the first year (that were described before), this seems to be almost impossible. On the other hand, in favour of the supposition above, the appearance of the first thin cementum deposit on the  $M_1$  root of the 7-month-old cave bear cubs could be mentioned. This cementum layer was explained as the "neonatal zone" (Debeljak, 1996a, 29-30, Pl. 26-28), but it is very similar to the following "winter" increments.

b) The other possible interpretation of the discordance between the expected and observed mortality profile is that our age estimates are correct. Life habits and the mortality of the cave bear are then different than was thought so far. (Similarly, Musil (1965, 74-76), after measuring long bones of extremities, came to the conclusion that cave bears kept visiting the cave Pod hradem and also died there in the summer months.)

Perhaps the final answer will be given by further researches into the ontogenetic development in present-day bears from different environments, and by detailed analyses of the dental cementum in bear cubs.

#### *From the ninth month to the end of the first year*

During the 9th or 10th month the bears finally get the second lower  $M_2$  molars. The last upper  $M^2$  molars start erupting in the ninth month. Sometimes after only the tenth month the permanent canines begin to pierce through the jawbone. Shortly

before the completed first year (11th or 12th month) the  $M_3$  teeth also appear through the gum. Owing to the inclined position and remarkably flat crown much time is needed before they become erupted entirely.

Ehrenberg (1931, Pl. 120, fig. 6) published a photograph of a mandible of a cave bear cub to which an age of approximately 8–9 months could be ascribed.

Plate 8, fig. 1 and plate 10, fig. 1 show the lower jawbone of an approximately 10-month-old present-day brown bear from Slovenia. The anterior part of the  $M_3$  is "out". The tips of the permanent canines have just appeared out of the alveola, but have not yet penetrated the gum. Lateral-distal from them the deciduous canines are attached. All the other milk teeth were shed before the tenth month.

The mandible in plate 9, fig. 1 and plate 10, fig. 2 belonged to an approximately one-year-old brown bear from the Kočevje region (S Slovenia). Somewhat more than 1 cm of the canine reaches above the rim of the mandible. Beside it the deciduous canine with a worn out crown and strongly resorbed root is still in place. For a certain period during replacement of their canines the bears have the permanent and the deciduous canines in their gums at the same time. The deciduous canines are shed at an age of 12–15 months only, during hibernation in the den.

The above two examples of brown bear mandibles are shown here owing to the lack of an appropriate mandible for the age period being considered in the collection from the Divje babe. A well-defined gap was observed among isolated teeth ( $M_1$ ) as well. It appears that the Divje babe I site contains scarcely any remains of cave bears that died between the 10th month and the completed first year of life, i.e. during the first part of wintering in the cave den (Debeljak, 1996a, 1997).

However, with regard to the previous discussion, it is also possible that this "missing" age-group represents the juveniles of the next summer period.

#### *From one year to one and a half years*

In bears, during the period between one year and one and a half years the eruption process of permanent dentition comes to an end. The individual differences become more pronounced (Dittrich, 1960), thus the age determinations are less accurate than for the previous period. The last permanent teeth ( $M^2$ ,  $M_3$  and canines) are usually completely erupted in the present-day bears of one and a half years old.

This period of ontogenetic development in the cave bear is represented by the following three examples. Their individual ages were estimated according to the data for present-day brown bears. Nevertheless, we should also consider the other possibility of slower ontogenetic development of dentition in the cave bear. In this case, the next three mandibles could belong to two-year-olds or even older cubs that died during their third winter.

8. (Pl. 11, figs. 1, 2; Pl. 13, fig. 1) – The mandible of a male approximately 12–15 months old: The mandible size was equal to that of the adult present-day brown bear. The symphyseal part, where the left and right mandibles were joined, is most probably pathologically deformed. The inflammatory alteration was possibly the result of a traumatic lesion of the jaw. About a centimeter and a half of the canine crown protrudes out of the alveolus, and more than half of the root wall is formed already. The anterior part of the chewing surface of  $M_2$  is slightly worn out. A large part of the  $M_3$  crown had not yet erupted through the gum. Its position is still inclined with respect to the tooth row.

During the eruption of the last lower  $M_3$  molar it sometimes happened that its crown became wedged with the adjacent  $M_2$  crown. On some adult cave bear mandibles corresponding pathologic changes can be observed that most certainly caused serious troubles to the animals. According to certain authors the irregularities in eruption of the last molars were the main, or at least a very important cause of mortality in cubs during their second winter (Ehrenberg, 1931; Abel, 1931). The investigations at the Divje babe, however, did not confirm this assumption. I believe that the difficulties mentioned could have seriously endangered cave bears mostly later in their lives. Although it was also possible that the eventual infection in a weakened cub sometimes terminated even with its death.

9. (Pl. 12, figs. 1, 2; Pl. 13, fig. 2) – The mandible of a female about 15 months old: Two thirds of the canine root are already formed. The crown has not yet erupted entirely. It extends for more than two centimeters beyond the margin of the alveolus.  $M_3$  is not yet “in place” or in the occlusal plane. The  $P_4$  and  $M_2$  roots are still open at the ends. The root canal of  $M_1$  is sealed and the crown “polished”, with individual, 2–3 mm wide attrition facets. Wear is also evident on the anterior part of  $M_2$ . On the chewing surface of  $M_3$ , however, no traces of wear are visible. Owing to lack of space in the tooth row the individual teeth pressed one against the other. (After the first year the facets started appearing at points of contact between certain teeth, and they widened and deepened with time. This is especially pronounced on the anterior wall of the  $M_2$  crown, and the posterior wall of the  $M_1$  crown. This type of wear is called approximal wear, in contrast to occlusal wear on the chewing surface).

For comparison the mandible of the nearly one-and-a-half-year-old brown bear from the surroundings of Kočevje can be taken (Pl. 16, figs. 1, 2; Pl. 18, fig. 1). Here, too, the canines are not yet entirely erupted. However, the tooth roots are already closed, with the exception of the  $M_3$  and canines. The  $M_3$  crown has not yet fully emerged from the gums. The following individual is also in a similar ontogenetic phase:

10. (Pl. 14, figs. 1, 2; Pl. 15, figs. 1–3) – The mandible of a female cave bear approximately one and a half years old: The canine is somewhat more developed than in the brown bear just discussed. Its crown is practically entirely erupted, only about one centimeter of the root is lacking. The  $M_3$  is in place in dentition. The  $M_1$  is somewhat more worn out as in the above-discussed specimens. The surface is smoothed and covered with small wear facets. At the point of contact of  $M_1$  and  $M_2$  a well developed facet appeared on both teeth (approximal wear). On the posterior wall of the  $M_1$  crown this facet is more than 4 mm wide. The  $M_1$  root (tooth canal) has already closed during the first year. At the age of around one and a half years its wall was about 2.5–2.75 mm thick. At the  $M_2$  the tips of the root were still somewhat perforated. The  $M_3$  root is still widely open, and its wall is very brittle (Pl. 15, fig. 3).

Isolated teeth have usually been defined as juvenile if the root is open, or as adult if the root is closed. In this way, certain teeth of the same individual are determined as adult, and others that lag behind in development as juvenile. The problem, however, is not only in the uncertainty of the data. The classification mentioned is inadequate first of all because a large proportion of cub teeth are incorrectly attributed to adults. The bear becomes adult around the fourth year only. The  $M_1$  root closes before the end of the first year, and the  $M_2$  and  $P_4$  at an age of one and a half years. Therefore, the closure of the root apices (or pulp canals) can be a criterion for determining adult status only in the last, most distal molars and canines.

As co-author I am obliged to call attention to an error in a paper from five years

ago, when the ontogenetic development of dentition in bears was not yet sufficiently known to us (Turk et al., 1992). In that contribution the measurements of "adult"  $M_1$  molars were statistically analyzed with the aim of establishing the ratio of the two sexes in the adult population of cave bears. In fact, however, the teeth examined should be attributed to older juveniles (two years, three years, possibly at most four years old). Their root was closed, and on the ground of this criterion we wrongly attributed them to adults.

#### *Further development of dentition and jawbones:*

Presumably in the middle or at the end of the second year of life the cave bears already had the complete permanent dentition erupted. Nevertheless the teeth continued their development. The originally hollow roots and crowns became more and more filled with dentine. Finally, in the center only a narrow canal and the pulp cavity at the passage from root to crown were left. We assume that in the cave bear during the 4th year the last tooth roots also became sealed: those of the  $M_2$ ,  $M_3$  and of canines. The initially explosive growth of jaws in the following years gradually slowed down.

**11.** (Pl. 17, figs. 1, 2; Pl. 18, fig. 2) – The mandible of a subadult male about 4 years old: The age of this specimen was determined by counting the growth lines (i.e. increments) in dental cementum. The method is regarded as the most objective, and it is generally used for estimating the individual ages of wild animals (more in: Debeljak, 1996a, b). The above-mentioned process of dentine deposition in the interior of the teeth is already at an advanced stage, as clearly seen in the x-ray photograph (Pl. 18, fig. 2). The  $M_1$  crown is the most worn out (especially the protoconid and hypoconid),  $M_2$  less and  $M_3$  very little so (Pl. 17, fig. 2). At the contact of individual molars relatively deep facets developed. On the posterior wall of the  $M_1$  crown such a facet is already more than 6 mm wide. The length of the crown in this way could not be exactly measured any more. According to the x-ray picture the canine and  $M_3$  roots are not yet completely closed, although they are near to it. In present-day bears the canine root becomes closed around the 4th year (Marks & Erickson, 1966, 395, 397), i.e. during the time when they reach adulthood.

The above described mandible had not yet reached its final size. The mandibles of fully grown males measure 5–10 cm more in length. The growth of jaws therefore also continued after the fourth year. In the present-day black bear the head of males grows during the first 8 years, while in females the growth is terminated somewhat earlier, soon after reaching sexual maturity (Marks & Erickson, 1966, 400–402). Most probably it was not much different in cave bears either.

#### **Conclusion**

In this contribution the ontogenetic development of dentition in the cave bear, and bears in general, was presented. The process of replacement of deciduous dentition and the eruption of permanent teeth is generally completed by the age of one and a half years. Until then the particular ontogenetic phases are a good indicator of individual age.

On the basis of the cases described and the data collected the age of juvenile cave



bear jawbones can be quite accurately estimated. In the future the ontogenetic development and the criteria for determining the individual age of particular (isolated) teeth that are the most numerous and most informative fossil remains of the cave bear will have to be presented in detail.

Here are the principal conclusions:

– The process of tooth growth and of the replacement of deciduous dentition with the permanent type took place in the cave bear in the same way, through the same and probably also synchronic ontogenetic phases as in the related present-day bears.

– It is possible to infer that a certain ontogenetic phase of dentition development corresponds to approximately the same age of an individual in the cave bear, as well as in the brown bear. The development of dentition in the cave bear must not have significantly lagged behind, since cubs at a certain age (in the 6th or at least in the 7th month of life) needed the first pair of permanent molars ( $M_1$  &  $M^1$ ) to be able to start chewing hard plant food.

– This argument speaks against another possibility, that the ontogenetic development of cave bear dentition was in fact essentially slower than in present-day bears. Such a characteristic would (in certain circumstances) endanger the existence of the species. Nevertheless, this alternative still cannot and should not be simply rejected.

– The size of the jawbones during the first year of life (and also later) was dependent upon the sizes of permanent teeth that were developing during that time, partly encased in the jawbones and almost completely filling them up.

– The growth of jawbones in cave bear cubs was essentially faster than in the present-day brown bear. Already at the age of one year their mandible was of the same size as in the adult brown bear. This most certainly does not mean that the rest of the body was also larger to the same degree.

– It is presumed that in the cave bear the secondary sexual dimorphism was manifested already in the first year of life; males had larger sized jaws than females.

– The generally used criterion of distinguishing teeth as juvenile if their crown is open, and adult when it is closed, is not adequate for most of the cave bear teeth. The bear becomes adult at the age of around four years. The  $M_1$  root, however, closes as early as the first year of life (after the 8th month), most of other teeth by the age of one and a half years, and only the roots of  $M^2$ ,  $M_3$  and canines at about four years.

– In the study of juvenile jawbones from the Divje babe I site the fact cannot be overlooked that the majority of the specimens originally belonged to presumably about seven-month-old cubs that therefore died in the middle of summer. This is in contradiction with the prevailing opinion that massive remains in typical cave bear localities are of animals that perished owing to exhaustion during hibernation, prior to spring.

– An interesting problem and task for the future will be to prove and explain this statement with further researches and additional data.

### Acknowledgements

I am much obliged to Ivan Turk, the leader of excavations at the Divje babe I, for the material he ceded for examination. The excavation has been carried out by the Institute for Archaeology at the Scientific Research Centre of the Slovenian Academy of Sciences and Arts. At the Clinic for surgery and small animals of the Veterinary Faculty in Ljubljana, the x-ray examination of jawbones of the cave and brown bear

was kindly allowed, and performed professionally thanks to the efforts of the veterinarians Teodora Ivanuša, Janez Štubelj and Gregor Frelih. Andrej Bidovec (Veterinary Faculty, University in Ljubljana) and Ciril Štrumbelj (Breeding and hunting ground "Medved", transl. "Bear", Kočevje) provided skulls of present-day brown bear cubs from Slovenia that were necessary for comparisons. Vida Pohar reviewed the manuscript. All others who were of whatever assistance in the elaboration of this paper are also warmly thanked.

## Ontogenetski razvoj zobovja pri jamskem medvedu

### Uvod

Za razliko od filogenetskega razvoja ontogenetski razvoj zobovja jamskega medveda do zdaj še ni bil pregledno in nazorno opisan in je v strokovni javnosti na splošno slabo poznan.

Večina raziskovalcev jamskega medveda se omeji le na podatek, da je neka čeljustnica juvenilna, oz. da je pripadala mladiču. Le redki avtorji (kot npr. Rădulescu & Samson, 1959) fotografije ali opise opremijo z natančnejšim podatkom o starosti mladiča, ki jo lahko ocenimo s pomočjo primerjave z današnjim rjavim medvedom. Tokrat so o izražanju zobovja rjavega medveda zbrani vsi tisti podatki, ki so pomembni za ugotavljanje individualne starosti čeljustnic mladičev jamskega medveda in tudi drugih medvedjih vrst.

Pri tem ne gre samo za to, da bi ob razmeroma redkih najdbah juvenilnih čeljustnic določali starost že davno poginulih živali zgolj iz radovednosti, kot nekakšno zanimivost. Paleontologe in arheologe zanima tudi vedenje jamskih medvedov in okolje, v katerem so živeli, predvsem pa odnos med pračlovekom in medvedom. S tega stališča nam natančna ocena individualne starosti čeljustnic manj kot leto dni starih mladičev ponuja zelo pomemben podatek: to je sezono, ko so živali poginile.

Seveda nam najbolj natančne podatke o mortaliteti jamskega medveda omogoča starostna analiza posamičnih, izoliranih zob; v tistih paleolitskih jamskih najdiščih, ki so bili hkrati tipični brlogi jamskega medveda, jih najdemo v desetisočih primerkih. Vendar, individualno starost posamičnih juvenilnih zob lahko pravilno ugotovimo le, če njihov razvoj oziroma stopnjo formiranosti pri različni starosti najprej preučimo na nizu celih čeljustnic.

Ravno to je bil povod za analizo čeljustnic mladičev jamskega medveda iz paleolitskega najdišča Divje babe I. Ta študija je služila kot osnova za nadaljnjo raziskavo starostne sestave populacije jamskega medveda iz zgornjega dela pleistocenskih sedimentov (Debeljak, 1996 a, 1997). Starostno analizo smo izpeljali na izoliranih mlečnih zobeh  $d_4$  in stalnih zobeh  $M_1$ , zato je v tem prispevku najbolj podrobno predstavljen prav njun ontogenetski razvoj.

### Dosedanje raziskave

Ontogenetski razvoj pri jamskem medvedu je prvi preučeval *Ehrenberg*. Ugotovil je, da so stopnje ontogenetskega razvoja zobovja prav takšne kot pri rjavem medvedu (1931, 640). Opisal je posamezne razvojne stopnje spodnjih čeljustnic in približno ocenil njihovo individualno starost (1931, 659–675, 701–703). V tistem času so bili na voljo le skopi podatki o rasti zobovja pri rjavem medvedu, zato je razumljivo, da so bile *Ehrenberg*ove ocene starosti nenatančne. Sklenil je, da v znanem nahajališču *Drachenhöhle* pri *Mixnitzu* veliko ostankov pripada mladičem, ki so poginili od izčrpanosti, stari manj kot 4 mesece, tik pred nastopom pomladi. Tej skupini naj bi sledila izrazita vrzel in potem najštevilnejši ostanki približno enoletnih mladičev. Višek smrtnosti pri tej starosti naj bi bil posledica težav pri izražanju zadnjih kočnikov. Po domnevni odsotnosti ostankov 4- do 10-mesečnih mladičev je *Ehrenberg* sklepal, da je jamski medved uporabljal jamo le pozimi, v času hibernacije. Takšno mnenje je med raziskovalci prevladovalo vse do danes. Nekdanje spektakularne predstave o lovu na jamskega medveda so se umaknile trezni znanstveni presoji.

Čez 30 let je *Ehrenberg* že imel dobre primerjalne podatke za recentnega rjavega medveda, in je skoraj popolnemu skeletu mladiča jamskega medveda iz *Hartlesgrabna* pripisal starost 7 mesecev (1964, 217–219). V istem prispevku je popravil ocene starosti nekaterih mandibul iz leta 1931. Še vedno pa je vztrajal pri svojem prepričanju, da v starostni sestavi ostankov jamskega medveda obstaja omenjena časovna vrzel, in da so redki ostanki 4–10-mesečnih mladičev zgolj izjema, ki potrjuje to pravilo.

*Musil* (1965, 72) je juvenilne čeljustnice jamskega medveda iz jame *Pod hradem* razvrstil po napredovalem ontogenetskem razvoju in jih podrobno opisal. Ni pa jim natančneje določil individualne starosti.

### Material in metode

Ontogenetski razvoj zobovja pri jamskem medvedu bo v nadaljevanju opisan na enajstih primerih čeljustnic iz paleolitskega najdišča *Divje babe I*. Jama leži pod robom *Šebreljske planote*, nad dolino *Idrijce* (W Slovenija). Večidel pleistocenskih jamskih sedimentov izvira iz obdobja srednjega würma. Vse fosilne ostanke jamskega medveda iz *Divjih bab* hrani *Narodni muzej Slovenije* v *Ljubljani*. Splošne podatke o najdišču najdemo v naslednjih delih: *Turk* s sodelavci, 1989a, b in *Turk* ed., 1997.

Pri oceni starosti posameznih čeljustnic sem si pomagala z izčrpnimi *Dittrichovi*mi (1960) podatki za recentne medvede in s primerjavo juvenilnih čeljustnic rjavega medveda iz Slovenije. Spol sem določila po velikosti zob, predvsem kaninov, glede na ugotovitve *Kobyja* (1949) in *Kurténa* (1955).

Nekatera dejstva o življenjskih navadah rjavega medveda, ki jih lahko pripišemo tudi sorodniku jamskemu medvedu, sem povzela po naslednjih delih: *Macdonald* ed., 1985, 88–95 (slovenski prevod istega dela: *Macdonald* ed., 1996) in *Kryštufek*, 1991, 191–193.

### Čeljustnice in zobje jamskega medveda – splošno

Spodnjo čeljust medvedov sestavljata dve spodnječeljustnični kosti (mandibuli). Sprejaj se stikata v posebni zrasti (simfizi), ki nikoli ne okosteni. Zgornjo čeljust na

vsaki strani oblikujeta dve parni kosti: medčeljustnica, ki nosi sekalce in sega do podočnika ter zgornja čeljustnica ali maksila. Ti dve kosti sta koščeno zraščeni samo pri odraslih medvedih. V čeljustnicah so oblikovane zobnice ali alveole, v katerih tičijo zobne korenine.

Tako rjavi kot tudi jamski medved imata v obeh čeljustih na vsaki strani naslednje mlečne zobe: po 3 sekalce ali incizive ( $d_{1-3}$ ), 1 podočnik ali kanin ( $dc$ ) in ponavadi 3 ličnike ali premolarje ( $d_{2-4}$  oz.  $p_{2-4}$ ). Na vsaki strani spodnje čeljusti jamskega medveda so naslednji stalni zobje: trije incizivi ( $I_{1-3}$ ), kanin ( $C$ ), ponavadi samo en premolar ( $P_4$ ) in trije meljaki ali molarji ( $M_{1-3}$ ). V zgornji čeljusti je en molar manj.

Kočniki imajo široko žvekalno površino z nizkimi, zaokroženimi grbnicami. Že zgodnje raziskave morfologije zobovja in lobanje so pokazale, da so bili jamski medvedi predvsem rastlinojedi (cf. Kurtén, 1976). Sodobne izotopske analize so to domnevo potrdile (Bocherens et al., 1994).

Stalno zobovje medvedov je podrobno opisal Rode (1935). Koby (1952) in Rădulescu in Samson (1959) pa so opisali mlečno zobovje jamskega medveda.

Pri orientaciji čeljustnic in zob so v rabi različni izrazi. V tem prispevku se srečamo z naslednjimi: Spredej – anteriorno – mezialno. Zadaj – posteriorno – distalno. (Poenostavljeno! Vsi našteti izrazi sicer niso ekvivalentni.) Proti licu – bukalno – lateralno. Proti jeziku – lingvalno (pri mandibuli) oziroma palatinalno (pri maksili). Grizna (zgornja) površina zob je okluzalna.

### Ontogenetski razvoj zobovja pri medvedih (družina Ursidae)

Nekaj podatkov o izraščanju stalnih zob pri recentnih medvedih najdemo v naslednjih delih: Pohle, 1923; Couturier, 1954; Rausch, 1961; Marks in Erickson, 1966. Najbolj natančno pa je razvoj mlečnega zobovja in zamenjavo s stalnimi zobmi pri rjavem medvedu raziskal Dittrich (1960). Ugotovil je, da je ta proces enak in sočasen tudi pri drugih vrstah medvedov. Zaporedje izraščanja posameznih zob iz dlesni je predstavljeno na sliki 1. Druge Dittrichove podatke o ontogenetskem razvoju zobovja pri medvedih lahko strnemo v naslednje bistvene ugotovitve:

Mladiči se skotijo brez zob. Prvi mlečni zobje začnejo izraščati v drugem mesecu življenja in so v tretjem mesecu na svojem mestu. Prvi stalni kočniki začnejo prodirati skozi dlesen v petem mesecu življenja. Šele potem ko zraste prvi par stalnih molarjev ( $M_1$  &  $M^1$ ), lahko mladiči žvečijo trdo hrano. Mlečno zobovje pri tem nima skorajda nobenega funkcionalnega pomena. Mlečni zobje izpadejo do konca 15. meseca. Zadnji stalni zobje dokončno izrastejo pri povprečni starosti okoli enega leta in pol.

Dittrich (1960, 119–123) je ugotovil, da prehranjenost (telesna teža) pri medvedih navadno ne vpliva na razvoj in hitrost izraščanja zobovja. Tudi individualne razlike so pri tem procesu razmeroma majhne (glej sl. 1).

Razporeditev mlečnih in stalnih zob v čeljustih mladiča rjavega medveda ponazarjata sliki 2a in 2b.

## Ontogenetski razvoj zobovja pri jamskem medvedu

### Prvi trije meseci

Kostni ostanki še nerojenih živali (fetusov) in tistih mladičkov, ki so poginili ob rojstvu ali kmalu zatem (neonati), so se v pleistocenskih najdiščih ohranili le izjemoma. Tovrstne najdbe v Divjih babah pa kljub temu niti niso tako redke, saj je jama kot brlog skoz dolga tisočletja služila predvsem samicam jamskega medveda, ki so tu v zimskih mesecih, od decembra do februarja kotile mladiče (Turk et al., 1989b; Debeljak, 1997). Drobne in zaradi poroznosti krhke spodnje čeljustnice še nerojenih ali novorojenih medvedkov so dolge 2–3 centimetre, široke pa le okoli 5 milimetrov.

Mladiči jamskega medveda so se skotili brez zob. Tako je tudi pri današnjih medvedih. Že v prvem tednu življenja pa najdemo v preparatih čeljusti rjavega medveda zametke mlečnih zob: majhne, votle vršičke kron, ki še niso prodrli iz dlesni (Dittrich, 1960, 11, sl. 1, 2). To fazo ontogenetskega razvoja predstavlja naslednji primer:

1. (Tab. 1, sl. 1, 2) – Leva in desna mandibula dveh neonatov, ki sta poginila že v prvih dneh po rojstvu: Zaradi nazornosti sta mandibuli na sliki združeni v naravni legi, čeprav ne izvirata od istega osebka. Od strani vidimo (tab. 1, sl. 2), da je telo mandibule polkrožno upognjeno, kar je značilno za neonate. Na polomljeni zgornji površini se lepo vidita zametka obeh mlečnih kaninov in celo zametek protokonida zadnjega mlečnega zoba  $d_4$  oz.  $p_4$ , kot ga nekateri označujejo. (Protokonid je osrednja, največja grbinica na omenjenem zobu). Zametki mlečnih zob so bili prvotno zaprti v kosti. V tistem času so se alveole, skozi katere bi kasneje prodrli rastoči mlečni zobje, šele oblikovale. Dolžina opisane mandibule je znašala okoli 4 centimetre; toliko, kot pri novorojenih mladičih rjavega medveda.

Ehrenberg (1973) je dokumentiral najdbo skoraj popolnega skeleta neonata, starega približno 10 dni iz avstrijskega nahajališča Salzofenhöhle. Po različnih izmerah in rekonstrukciji, ki so jo naredili iz kosti, je ugotovil, da so bili mladiči jamskega medveda ob rojstvu morda le malenkostno večji kot pri rjavem medvedu. V leglu rjavega medveda so običajno dva do trije kot podgane veliki mladiči, ki tehtajo le 350–400 gramov. So goli, slepi in popolnoma nemočni. Sami še ne morejo vzdrževati svoje telesne temperature. Preživijo lahko le ob skrbni materi, v pred mrazom zavarovanem okolju brloga.

Drugi in tretji mesec življenja so tudi mladiči jamskega medveda zagotovo preživeli v brlogu oziroma jami. Samica jih ni zapuščala. V dolgih mesecih do nastopa pomladi je živela le od maščobne zaloge, ki si jo je nabrala pozno poleti in jeseni. Za njene mladiče je bil to čas dojenja; izključno mlečne prehrane. Medtem so vsi mlečni zobje postopoma izrasli iz dlesni. Pod njimi, skrite v kosti, pa so se oblikovale in krepile krone stalnih zob. Zaporedje izraščanja posameznih mlečnih zob lahko rekonstruiramo s pomočjo podatkov za rjavega medveda (sl. 1). To obdobje ontogenetskega razvoja predstavljata naslednja dva primera:

2. (Tab. 2, sl. 1–3) – Mandibula mladiča, starega okoli 2 do 2,5 meseca: Krona prvega stalnega molarja  $M_1$  je že izoblikovana; na rentgenskem posnetku (tab. 2, sl. 2, 3) se lepo vidi kot tanka, votla lupina, ki je zaprta v čeljustnici. Rasti so začeli tudi prvi milimetri stene korenine. V notranjosti mandibule tičita vršička oziroma zametka kron  $P_4$  in  $C$ . Stalni zobje so se razvijali v votlih delih mandibule, med katerimi so tanki prekatni. Na zgornji strani čeljustnice, na mestu, kjer bi kasneje izrastel  $M_1$ , zeva

ozka reža. Pred njo so luknjice; to so alveole, v katerih so tičale korenine mlečnih premolarjev  $d_4$  in  $d_3$ . Dokazujejo nam, da sta omenjena mlečna zoba že izrastla iz čeljustnice, torej mladič po vsej verjetnosti ni bil mlajši od dveh mesecev. Mandibula je bila približno tako dolga kot pri približno štiri mesece starem rjavem medvedu (sl. 2a), vendar precej bolj robustna.

3. (Tab. 3, sl. 1–3) – Obe polovici mandibule mladiča, starega okoli 2,5 do 3 mesece: Brazda na mestu, kjer bi čez mesec ali dva začel izraščati  $M_1$ , se je že razširila. Z zgornje strani se skožnjo vidi temna, kot jajčna lupina krhka krona  $M_1$ . Oblikovala se je že zgornja četrtna korenine  $M_1$  (tab. 3, sl. 2, 3), ki pa je tanka kot papir. Tudi krone stalnih incizivov in zametki C in  $P_4$  so zaprti v čeljustnici. Na zgornji strani mandibule se lepo razločijo alveole mlečnih zob. Pri tej starosti so ravnokar izrastli skorajda vsi mlečni zobje, vendar se tu niso ohranili. (Proces izraščanja mlečnih zob lahko ponazorimo s primerom  $d_4$ : Pri starosti 1 do 2 meseca je bila v čeljusti zaprta krona  $d_4$  temno rjave barve, motna in zelo krhka. Kasneje se je svetleje obarvala najprej konica protokonida, to je konica, ki prva prodre skozi dlesen, in potem postopoma še preostali del krone. Pri 2- do 3-mesečnih mladičih je bila krona izraščenega  $d_4$  že okrepljena, normalno svetla in sklenina je dobila značilen sijaj. Korenina pa je bila še vedno votla, in zato precej krhka.)

Zgoraj opisana mandibula je tako velika kot pri polletnem rjavem medvedu. Za primerjavo nam lahko služi skica bistveno manjše mandibule trimesečnega recentnega rjavega medveda, ki jo je objavil Pohl, 1923.

#### *Četrty do šesti mesec življenja*

V četrtem mesecu imajo medvedje že vse mlečne zobe. Bolj ali manj formirane krone stalnih zob pa so medtem zaprte v čeljustnicah in se postopoma krepijo. Tako je na primer pri štirimesečnem mladiču pod mlečnim zobom  $d_4$  že oblikovana krona stalnega  $P_4$  (sl. 2a, 2b). Z nadaljnjo rastjo korenine začne stalni zob izpodrivati mlečnega. Močan protokonid krone  $P_4$  se pri tem zagozdi med oba kraka korenine  $d_4$  in sčasoma inducira kontaktno resorbcijo le-te. Podobno se zgodi tudi pri zgornjem paru mlečnega  $d^4$  in stalnega  $P^4$ .

V petem mesecu začnejo pri medvedih izraščati prvi stalni kočniki ( $M1$ ). Najprej pokuka iz dlesni sprednji del zoba  $M_1$  s protokonidom in parakonidom, kmalu zatem pa še zadnji del krone z metakonidom in talonidom (Dittrich, 1960, 80–81). Na pravkar opisani razvojni stopnji je zobovje mladiča rjavega medveda na sliki 2a. Couturier (1954, 142–143) je objavil to rentgensko sliko ujetega mladiča in mu prisodil starost treh mesecev. Po Dittrichovih (1960) podatkih pa je očitno, da je bil mladič v resnici starejši; imel je vsaj 4 mesece.

Rădulescu in Samson (1959, 211, sl. 11) sta objavila fotografijo mandibule približno 4-mesečnega jamskega medveda. Musil (1965, 72, tab. 3, sl. 10) je predstavil primerek mandibule, ki je morda nekoliko mlajši. Slike čeljustnice jamskega medveda, ki bi bila tipična za petmesečnega mladiča ( $M_1$  ali  $M^1$  v fazi izraščanja) pa v strokovni literaturi še nisem zasledila.

V osteološki zbirki iz najdišča Divje babe I nimamo nobene za objavo primerne čeljustnice 4 do 5 mesecev starega mladiča. To pravzaprav ni naključje, saj tudi med sicer izredno številnimi izoliranimi mlečnimi zobmi najdemo le redke primerke, ki bi jih lahko uvrstili v to starostno skupino. (Takšni so na primer zgornji ali spodnji  $d_4$  z okrepljeno korenino, ki je na konceh že nekoliko resorbirana. Posamezne konice na

kroni so zaobljene in pogosto nosijo drobne obrabne fasete. Debeljak, 1996 a, 1997). Očitno je bila smrtnost štiri- do petmesečnih mladičev v jami Divje babe precej nižja kot v mlajših starostnih razredih.

Namen tokratnega prispevka ni razpravljati o možnih vzrokih različne stopnje smrtnosti med letom. Omenim naj le, da je bil četrti do šesti mesec življenja čas nastopa pomladi. Pri rjavem medvedu mladiči s samico zapustijo brlog po dopolnjenem tretjem mesecu; aprila ali maja, včasih šele v začetku junija. Verjetno je bilo tako tudi pri jamskem medvedu.

Poleg mleka, ki ga sesajo pri materi, začnejo medvedje v petem ali šestem mesecu gristi trdno hrano. To je mogoče šele takrat, ko zraste prvi par stalnih molarjev (Dittrich, 1960, 14–15). Zgolj z majhnimi, koničastimi mlečnimi zobki si pri zvečenju ne bi mogli kaj prida pomagati. Šele z novimi kočniki pridobijo potrebno žvekalno površino.

### *Sedmi in osmi mesec življenja*

Mladiči so dočakali poletje. Za vso medvedjo družino je prišel čas intenzivnega prehranjevanja. V naslednjih mesecih so morali pridobiti zadostno plast maščevja, če so hoteli preživeti stradanje med naslednjo zimo. Zobje 6- do 8-mesečnih mladičev so bili takrat v naslednjem stanju:

4. (Tab. 4, sl. 1–5) – Mandibula samice, stare okoli 6–7 mesecev: Razvoj je v primerjavi s prejšnjim primerkom (tab. 3) precej napredoval. Krone vseh stalnih zob so že oblikovane. Kasneje ne bi več rastle, ampak bi se le še okrepile, s tem da bi se notranjost postopoma zapolnila z zobovino oz. dentinom.  $M_1$  je bil pri tem mladiču že kak mesec na "svojem mestu" v čeljusti in ima razvite več kot 4/5 korenine. Krona se je nekoliko okrepila, korenina pa je še povsem votla in odprta na apeksih (tab. 4, sl. 5). Na  $M_1$  so očitni prvi znaki obrabe, kar kaže, da je medvedek že nekaj časa grizel trdo hrano. Pri zvečenju so nastale številne drobne obrabne fasete z značilno svetlečo, zglajeno površino. Na fotografijah in rentgenskem posnetku se lepo vidi, kako ontogenetski razvoj pri posameznih zobeh različno napreduje; v skladu s podatki za rjavega medveda, podanimi na sl. 1.  $M_1$  v razvoju prehiteva druge stalne zobe. Sledi mu  $I_1$ , ki je bil v tem času že izraščan, vendar se ni ohranil.  $I_2$  je prodril skozi dlesen malo preden je mladič poginil,  $P_4$  in  $M_2$  pa sta bila tik na tem. Vršička njunih kron sta se že svetleje obarvala. Zadnji sekalec  $I_3$  je še vedno zaprt v mandibuli in ga vidimo le na rentgenski sliki. Prav tako podočnik, ki ima oblikovano samo krono, korenine pa še ne.  $P_4$  je v tem starostnem obdobju izpodrival mlečna zoba  $d_4$  in  $d_3$  iz čeljusti. Njuna korenina je bila takrat že močno resorbirana. Najkasneje čez kakšen mesec bi  $d_4$  (pri našem primerku se ni ohranil) s popolnoma resorbirano korenino po naravni poti izpadel iz dlesni. (Zadnji mlečni premolar  $d_4$  je pri medvedih v rabi zelo kratek čas; pri zvečenju trdne hrane sodeluje le okoli 3 mesece, zato njegova žvekalna površina praviloma nikoli ni močno obrušena.) Velikost zgoraj opisane mandibule ustreza leto dni staremu mladiču rjavega medveda (tab. 9, sl. 1; tab. 10, sl. 2).

**Ali so naše ocene starosti pravilne?** Je bil razvoj zobovja pri jamskem medvedu hitrejši, ali pa je morda zaostajal v primerjavi z rjavim medvedom? Razmislimo o tej možnosti na primeru pravkar opisane čeljustnice:

Fiziološko nujno je, da je v šestem ali vsaj sedmem mesecu ontogenetski razvoj tako napredoval, da je v denticijo že vključen prvi par stalnih molarjev. To velja za današnje rjave medvede in prav nič drugače ni moglo biti pri jamskih medvedih. Kot

smo že omenili: pri začetnem prehodu na rastlinsko hrano največjo vlogo odigrajo prav prvi stalni molarji  $M_1$ , kasneje pa so se jim pridružijo tudi nekateri drugi stalni zobje (sl. 1). Takrat materino mleko za rast postopoma ne zadostuje več in mladiči se morajo začeti prehranjevati tudi s trdno hrano. Mlečni zobje z izjemo zadnjih kočnikov  $d_4$  so tako majhni, da pri žvečenju trde rastlinske hrane nimajo praktično nobenega funkcionalnega pomena (Dittrich, 1960, 14–15, 50, 81–82).

Starost opisane čeljustnice jamskega medveda torej ne more bistveno odstopati od naše ocene. Če bi bila starost precej višja,  $M_1$  s svojo žvekalno površino ne bi bil dovolj zgodaj "na mestu", da bi se rastoči mladič lahko primerno hranil in tako kar najbolj izkoristil poletno in jesensko vegetacijsko obdobje oz. hrano, ki je bila takrat na voljo. Proti nižji starosti pa pričata velikost mandibule in obraba  $M_1$ , ki ni mogla nastati ob zgolj mlečni prehrani. To bi morda lahko dokazali tudi z izotopskimi analizami zobnih tkiv.

Menim torej, da pri ocenah starosti niso nastale velike ali celo bistvene napake in da je pri ontogenetskem razvoju zobovja jamskega medveda primerjava z rjavim medvedom umestna.

5. (Tab. 5, sl. 1, 2) – Mandibula samca, starega okoli 6,5–7,5 mesecev: Velikost te čeljustnice je že skoraj tolikšna kot pri poldrugo leto starem rjavem medvedu (tab. 16, sl. 1, 2; tab. 18, sl. 1).  $M_2$  s sprednjim delom prodira iz mandibule. Sklenina pri tem postopoma postaja vse svetlejša. Pri podočniku se je ravnokar pričela oblikovati stena korenine. Krona  $M_3$  je zaprta v dvigajoči se spodnječeljustnični veji in je zato značilno temno rjave barve, brez sijaja. Tanka koščena stena nad  $M_3$  je polomljena, zato se lepo vidi, da je žvekalna površina obrnjena lingvalno (proti jeziku) in s sprednjim delom usmerjena navpično navzdol. Šele z nadaljnjo rastjo čeljustnice bi nastal prostor za zadnja dva molarja. ( $M_3$  se mora pri medvedih zavrteti za  $90^\circ$  v dveh smereh, da se vključi v zobno vrsto.)

6. (Tab. 6, sl. 1–4) – Mandibula samice, stare okoli 6,5–7,5 mesecev: Ta čeljustnica je pripadala mladiču podobne starosti kot v prejšnjem primeru, morda je le za malenkost starejša.  $M_1$  je bil že nekaj časa "na mestu" in v rabi, zato njegova krona nosi približno 3 milimetre velike plitve obrabne fasete. Stena korenine je skoraj v celoti oblikovana, vendar na koncih še vedno odprta (tab. 6, sl. 4). Več kot pol krone  $M_2$  že gleda iz mandibule; oblikovala se je približno polovica korenine. Njena stena je zelo tanka, notranjost pa votla (tab. 6, sl. 4). Korenina  $M_1$  je bolj razvita in trdna; stena je debela približno 1 milimeter. V isti etapi ontogenetskega razvoja oziroma pri isti starosti zadnji spodnji molar  $M_3$  sploh še nima korenine, tanka ploska krona tega zoba pa se zlahka razlomi (tab. 5).

Zelo očitno je, da so bili posamezni zobje istega mladiča različno razviti, različno mehansko odporni, in zato niso imeli enakih možnosti, da se fosilno ohranijo. Pri analizah izoliranih zob moramo računati z različnimi tafonomskimi izgubami. Do teh razlik je prišlo tako zaradi specifične oblike in velikosti posameznih zob kot tudi zaradi različne razvitosti oziroma trdnosti pri določeni starosti.

Zanimivo je primerjati velikosti mandibul na tablah 4–6 (in tudi 11–15). Normalno je, da je velikost kosti odvisna od starosti osebka. Opazimo pa, da je velikost čeljustnic tudi pri podobni starosti lahko precej različna, sorazmerno z velikostjo stalnih zob. Ti praktično v celoti zapolnjujejo čeljustnico, kar se lepo vidi na rentgenskih posnetkih. Večji zobje zahtevajo tudi več prostora. Ugotovimo lahko:

1. Jamski medved je imel izrazito večje zobe kakor današnji rjavi medved. Razumljivo je, da so morale biti njegove čeljusti pri isti ontogenetski stopnji in starosti precej večje in bolj robustne. Čeprav so bili mladiči jamskega medveda ob rojstvu



komajda kaj večji kakor pri rjavem medvedu, je bila rast njihovih čeljusti v naslednjih mesecih bistveno hitrejša. Tako smo na primer ugotovili, da mandibula dobre pol leta starega jamskega medveda (tab. 5) lahko meri toliko kot pri poldrugo leto starem rjavem medvedu. Ali je bilo toliko večje tudi preostalo telo? S tako hitrim naraščanjem telesne mase pri mladičih jamskega medveda skorajda ne moremo računati. Samica bi težko vzredila dva ali celo tri tako velike mladiče že v prvem polletju, ko je bila prehrana pretežno mlečna. Bolj verjetno je, da so imeli mladiči izrazito velike čeljusti oz. gobec. Razmerje čeljusti/telo bi torej moralo biti bistveno večje kot pri odraslih jamskih medvedih in večje kot pri mladičih rjavega medveda. Pri edinem natančno opisanem in izmerjenem skeletu približno sedemmesečnega mladiča jamskega medveda (tovrstne najdbe so namreč izjemno redke!) najdemo potrditev te domneve. Avtor tega članka Ehrenberg (1964, 243–244) je bil presenečen nad odkritjem, da je obrazni del lobanje izrazito večji, kakor bi bilo pričakovati glede na možganski del lobanje, kratek trup in šibek toraks. Rekonstrukcija je pokazala, da je pri skupni dolžini 60 cm in višini 30 cm več kot eno tretjino zavzemala glava (Ehrenberg, 1964, 223). Menim, da takšnemu "nesorazmerju" botruje prav funkcionalni razvoj zobovja, ki je moral biti tako hiter kot pri današnjem rjavem medvedu. Čeljust pa se je pri tem ustrezno prilagodila rastočim zobem.

2. Samci jamskega medveda imajo v povprečju večje zobe kakor samice. Predvsem velja to za kanine, po katerih lahko glede na velikost določamo spol (Koby, 1949; Kurtén, 1955). Široka baza krone kanina in njegova rastoča korenina zasedata pri mladičih zelo velik del čeljustnic. Na rentgenskih posnetkih se lepo vidi, da sta višina in debelina telesa mandibule pri določeni starosti odvisni prav od velikosti kanina. Številni primerki iz Divjih bab kažejo, da so bile na isti razvojni (ontogenetski) stopnji mandibule samic manjše in bolj gracilne kakor pri samcih. Po tem bi lahko sklepali, da je bil spolni dimorfizem na čeljustnicah jamskega medveda izražen že v prvem letu življenja. Pomisliti pa moramo še na eno možnost: da je razvoj stalnega zobovja pri samcih zaostajal v primerjavi samicami. Vendar, če so takšne razlike v razvoju sploh obstajale, niso mogle biti bistvene zaradi že večkrat omenjenega razloga: Mladiču so pri določeni starosti morali izrasti prvi stalni zobje, da se je lahko ustrezno prehranjeval. Tudi pri danes živečih medvedih v procesu izraščanja zob niso ugotovili pomembnih razlik med spoloma (Dittrich, 1960; Marks & Erickson, 1966, 393).

Vsaj na enem primerku si oglejmo še stanje v zgornji čeljusti:

7. (Tab. 7, sl. 1–3) – Medčeljustnica in maksila samca, starega okoli 6,5–7,5 mesecev: Obe kosti pri tej starosti nista neločljivo spojeni. Pri današnjih medvedih se dokončno zrasteta šele pri odraslih živalih, po 4. letu (Marks & Erickson, 1966, 398–400). Na kroni  $M^1$  najdemo prve znake obrabe. Po obliki alveole sodeč, je bil  $P^4$  ravno v fazi izraščanja; večina njegove krone je zagotovo že prodrla iz čeljustnice. Od sekalcev se je ohranil le  $I^2$ , ki je malo pred poginom tega mladiča z vršičkom krone morda že prodrl skozi dlesen. Ležišče korenine  $I^1$  je nepoškodovano, tako da lahko ugotovimo, da je bil zob že dokončno izraščen. Nasprotno pa ozka odprtina alveole  $I^3$  dokazuje, da se izraščanje tega inciziva sploh še ni začelo. Nad pravkar omenjeno alveolo je ohranjena tudi plitva alveola mlečnega  $di^3$ , ki je pri tej starosti že tičal v čeljusti, čez kak mesec pa bi po naravni poti izpadel iz dlesni. Zgornji podočnik je skrit v maksili. Na rentgenskem posnetku (tab. 7, sl. 3) vidimo, da se njegova korenina še ni začela formirati. Krona je votla in še precej pod, ali bolje rečeno nad robom zgornje čeljustnice. Globoko ležišče korenine mlečnega podočnika je v celoti ohranjeno in s trdno koščeno steno popolnoma ločeno od razvijajoče krone stalnega kanina, zato

sklepamo, da korenina mlečnega kanina na tej stopnji ontogenetskega razvoja še ni bila prizadeta zaradi kontaktne resorpcije.

Preden končamo z opisom ontogenetskega razvoja zobovja v sedmem in osmem mesecu življenja, naj omenim še eno zanimivost: Med juvenilnimi čeljustnicami iz Divjih bab I imamo največ primerkov ravno iz pravkar obravnavanega starostnega obdobja, čeprav bi po ugotovitvah drugih raziskovalcev (Ehrenberg, 1931, 1964; Kurtén, 1958, 1976) ostanki 7-mesečnih mladičev, ki so poginili sredi poletja, morali biti prava redkost. Splošno uveljavljeno prepričanje, ki je obveljalo v zadnjih desetletjih, je, da množični ostanki jamskega medveda v jamah izvirajo od živali, ki so poginile zaradi izčrpanosti med dolgo hibernacijo, pozimi in predvsem tik pred nastopom pomladi. Vendar, tudi analiza izoliranih zob  $d_4$  in  $M_1$  je pokazala, da izredno velik delež v fosilni populaciji zavzemajo prav mladiči, ki so poginili pri domnevni starosti 6–8 mesecev, od julija do septembra (Debeljak, 1996a, 1997). Divje babe I kot tipično najdišče jamskega medveda gotovo ne predstavljajo nobene izjeme, zato so takšni rezultati o sestavi fosilne populacije presenetljivi in nepričakovani. Razložimo jih lahko na dva različna načina:

a) Naše ocene individualne starosti (in s tem tudi izoliranih juvenilnih zob) niso pravilne, in tako najpogostejša starostna skupina domnevno 7-mesečnih živali dejansko predstavlja tiste mladiče, ki so poginili med drugo hibernacijo. V tem primeru bi moral ontogenetski razvoj zobovja jamskega medveda kar za 6 mesecev zaostajati za ontogenetskim razvojem, ki so ga ugotovili pri današnjih medvedih. Glede na že omenjene prehranjevalne navade in potrebe v prvem letu se to zdi skoraj nemogoče. Po drugi strani pa bi lahko v podporo zgornji domnevi navedli videz prve tanke cementne obloge na korenini  $M_1$ . To cementno plast sicer razlagamo kot "neonatno linijo" (Debeljak, 1996a, 29–30, tab. 26–28), vendar je precej podobna "zimskim" prirasticam.

b) Druga možna interpretacija očitnega razhajanja med pričakovanim in ugotovljenim mortalitetnim profilom: Ocene starosti so pravilne. Življenjske navade in smrtnost jamskega medveda so potemtakem bistveno drugačne, kot smo domnevali do zdaj. (Podobno je že Musil (1965, 74–76) na podlagi merjenja dolgih kosti okončin prišel do sklepa, da so jamski medvedi zahajali v jamo Pod hradem in tam umirali tudi v poletnih mesecih.)

Dokončen odgovor na zastavljena vprašanja bodo morda omogočile nadaljnje raziskave ontogenetskega razvoja pri današnjih, v različnih okoljih živečih medvedih, pa tudi natančne analize zobnega cementa pri mladičih.

#### *Od devetega meseca do dopolnjenega prvega leta*

V 9. ali 10. mesecu življenja pri medvedih dokončno izrastejo drugi spodnji molarji  $M_2$ . Zadnji zgornji molarji  $M_2^2$  začnejo izraščati v devetem mesecu. Po desetem mesecu že lahko začnejo prodirati skozi čeljustnico stalni kanini. Malo pred dopolnjenim prvim letom (11. ali 12. mesec) pa predrejo dlesen tudi zadnji spodnji molarji  $M_3$ . Zaradi poševne lege in izrazito ploske krone mine še precej časa, preden v celoti izrastejo.

Ehrenberg (1931, tab. 120, sl. 6) je objavil fotografijo mandibule mladiča jamskega medveda, ki bi mu lahko pripisali starost približno 8–9 mesecev.

Na tabli 8, sl. 1 in tabli 10, sl. 1 je spodnja čeljustnica recentnega, okoli 10 mesecev starega rjavega medveda iz Slovenije. Sprednji del  $M_3$  je "zunaj". Vršički stalnih ka-

ninov so ravnokar pogledali iz alveole, vendar skozi dlesen še niso prodrli. Latero-distalno od njih so mlečni kanini. Vsi drugi mlečni zobje so do te starosti že izpadli.

Mandibula na tabli 9, sl. 1 in tabli 10, sl. 2 je pripadala okoli eno leto staremu kočevskemu rjavemu medvedu. Nekaj več kot 1 cm kanina sega čez rob alveole. Ob njem še vedno tiči mlečni kanin z obrabljeno krono in močno resorbirano korenino. V času zamenjave podočnikov imajo medvedje kar nekaj časa v dlesnih stalne in mlečne kanine hkrati. Mlečni kanini izpadejo šele pri starosti 12–15 mesecev, med zimovanjem v brlogu.

Zgornja primera mandibul rjavega medveda predstavljamo zato, ker za obravnava starostno obdobje v zbirki iz Divjih bab nimamo nobene primerne čeljustnice. Tudi pri izoliranih zobeh smo opazili zelo izrazito vrzel, ki kaže, da v Divjih babah skorajda ni ostankov jamskih medvedov, ki bi poginili med 10. mesecem in dopolnjem prvim letom življenja, to je v prvi polovici zimovanja v brlogu (Debeljak, 1996 a, 1997).

Vendar, glede na zgornjo razpravo je možno tudi to, da manjkajoča starostna skupina predstavlja mladiče iz naslednjega poletja.

### *Od enega leta do poldruega leta*

V času od enega leta do poldruega leta se pri medvedih končuje proces izraščanja stalnega zobovja. Individualne razlike pri tem postajajo vse bolj izrazite (Dittrich, 1960), zato starosti ne moremo določiti tako natančno kot prej. Zadnji stalni zobje ( $M^2$ ,  $M_3$  in kanini) so pri poldrugo leto starih recentnih medvedih praviloma dokončno izraščeni. To obdobje ontogenetskega razvoja pri jamskem medvedu nam predstavljajo naslednji trije primerki. Njihovo individualno starost sem ocenila na podlagi podatkov za današnje rjave medvede. Morali pa bi upoštevati tudi možnost, da je bil ontogenetski razvoj zobovja pri jamskem medvedu počasnejši. V tem primeru bi lahko naslednje tri mandibule pripadale dveletnim ali celo nekoliko starejšim mladičem, ki so poginili v svoji tretji zimi.

8. (Tab. 11, sl. 1, 2; tab. 13, sl. 1) – Mandibula samca, starega 12–15 mesecev: Velikost te mandibule je bila tolikšna kot pri odraslem recentnem rjavemu medvedu. Simfizični del, kjer sta bili leva in desna mandibula povezani, je najbrž patološko spremenjen. Vnetna sprememba je morda nastala ob kakšni travmatski poškodbi čeljusti. Kanin je že precej razvit. Dober centimeter in pol krone gleda iz alveole in oblikovana je že več kot polovica stene korenine. Sprednja polovica žvekalne površine  $M_2$  je rahlo obrabljena. Velik del krone  $M_3$  še ni prodrli skozi dlesen. Njegova lega je glede na preostale zobe še vedno poševna.

Pri izraščanju zadnjega kočnika  $M_3$  se je včasih zgodilo, da se je njegova krona zagzodila ob krono sosednega  $M_2$ . Na nekaterih mandibulah jamskega medveda lahko opazimo s tem povezane patološke spremembe, ki so živalim prav gotovo povzročale hude težave. Po nekaterih avtorjih so bile nepravilnosti pri izraščanju zadnji kočnikov glavni ali pa vsaj zelo velik vzrok smrtnosti pri mladičih v drugi zimi (Ehrenberg, 1931; Abel, 1931.) Z raziskavami v Divjih babah tega nismo mogli potrditi. Menim, da bi omenjene težave jamske medvede resno ogrožale kvečjemu kasneje v življenju. Čeprav je seveda mogoče, da se je morebitna okužba pri oslabelem enoletnem mladiču lahko končala tudi s smrtnim izidom.

9. (Tab. 12, sl. 1, 2; tab. 13, sl. 2) – Mandibula samice, stare okoli 15 mesecev: Oblikovani sta že dve tretjini korenine podočnika. Krona še ni v celoti izrastla; za

dobra dva centimetra sega čez rob alveole.  $M_3$  še ni čisto "na mestu" oz. v okluzalni ravnini. Korenina  $P_4$  in  $M_2$  je na konceh še vedno odprta.  $M_1$  ima zaprto korenino in "ogljajeno" krono s posameznimi, 2–3 mm širokimi obrabnimi fasetami. Tudi na sprednjem delu  $M_2$  je obraba že očitna. Na žvekalni površini  $M_3$  še ni sledov obrabe. Zaradi gneče v zobni vrsti posamezni zobje pritiskajo eden na drugega. (Po prvem letu so se ob stiku nekaterih zob začele nakazovati značilne fasete ter se sčasoma še povečale in poglobile. Še posebej je to izrazito na anteriorni steni krone  $M_2$  in posteriorni steni krone  $M_1$ . Takšen tip obrabe imenujemo aproksimalna obraba; za razliko od okluzalne obrabe na žvekalni površini.)

Za primerjavo lahko vzamemo spodnjo čeljustnico slabo leto in pol starega rjavega medveda iz okolice Kočevja (tab. 16, sl. 1, 2.; tab. 18, sl. 1): Tudi pri njem kanini še niso docela izrastli. Korenine zob pa so z izjemo  $M_3$  in kanina že zaprte. Krona  $M_3$  še ni v celoti pogledala iz dlesni. Na podobni ontogenetski stopnji je naslednji primerek:

**10.** (Tab. 14, sl. 1, 2; tab. 15, sl. 1–3) – Mandibula samice jamskega medveda, stare okoli eno leto in pol: Kanin je nekoliko bolj razvit kakor pri ravnokar omenjenem rjavem medvedu. Krona je praktično v celoti izrastla, manjka samo še kakšen centimeter korenine.  $M_3$  je že na svojem mestu v zobni vrsti.  $M_1$  je še nekoliko bolj obrabljen kakor pri prejšnjih primerkih. Površina je zglijana in posuta z majhnimi obrabnimi fasetami. Ob stiku  $M_1$  in  $M_2$  je na obeh zobeh nastala izrazita faseta (aproksimalna obraba). Na posteriorni steni krone  $M_1$  je ta faseta široka kar 4 mm. Korenina  $M_1$  se je zaprla že v prvem letu. Pri starosti okoli poldruega leta je njena stena debela približno 2,5–2,75 milimetra. Pri  $M_2$  sta konici korenine le še nekoliko perforirani. Korenina  $M_3$  pa še vedno široko zeva in ima zelo krhko steno (tab. 15, sl. 3).

Izolirane zobe ponavadi opredelijo kot juvenilne, če je korenina odprta, oziroma adultne, ko je korenina zaprta. Pri tem so nekateri zobje istega osebka označeni kot adultni, drugi, ki v razvoju zaostajajo, pa kot juvenilni. Problem pa ni samo v dvoičnosti podatkov. Omenjena klasifikacija ni ustrezna predvsem zato, ker se na ta način velik delež zob mladičev napačno prišteje med odrasle (na to je bilo opozorjeno tudi v: Turk et al., 1992). Medved odraste šele okoli 4. leta. Korenina  $M_1$  se zapre že pred dopolnjenim prvim letom starosti,  $M_2$  in  $P_4$  pa pri poldrugem letu. Zaprtost korenine je lahko kvečjemu kriterij za ugotavljanje odraslosti po zadnjih molarjih in kaninih.

Kot soavtorica sem dolžna opozoriti na napako v članku izpred petih let (Turk et al., 1992), ko ontogenetskega razvoja zobovja pri medvedu še nismo dovolj dobro poznali. V omenjenemu prispevku so bile statistično obdelane mere "adultnih" molarjev  $M_1$ , z namenom, da bi preučili razmerje obeh spolov med odraslimi jamskimi medvedmi. V resnici gre za zobe, ki bi jih morali pripisati starejšim mladičem (dveletniki, triletniki, morda še štiriletniki). Njihova korenina je bila zaprta, in na podlagi tega kriterija smo jih napačno prišteli med odrasle.

### *Nadaljnji razvoj zob in čeljusti*

Domnevno na polovici ali proti koncu drugega leta življenja so imeli jamski medvedi že izraščeno celotno stalno zobovje. Zobje pa so se kljub temu razvijali še naprej. Prvotno votle korenine in krone so se vse bolj zapolnjevale z zobovino ali dentinom. Končno je v sredini ostal samo še ozek kanal in pulpna votlina na prehodu iz korenine v krono. Predvidevamo, da so se pri jamskem medvedu okoli 4. leta zaprle še zadnje zobne korenine:  $M^2$ ,  $M_3$  in kaninov. V začetku eksplozivna rast čeljusti se je v naslednjih letih vse bolj umirjala.

11. (Tab. 17, sl. 1, 2; tab. 18, sl. 2) – Mandibula subadultnega samca, starega okoli 4 leta: Starost tega primerka je bila določena s štejetjem prirastnic na zobnem cementu. Ta metoda velja za najbolj objektivno in se vsesplošno uporablja za ocenjevanje individualne starosti pri divjih živalih (več v: Debeljak, 1996 a, b). Zgoraj omenjeni proces odlaganja dentina v notranjosti zob je že precej napredoval, kar se lepo vidi na rentgenskem posnetku (tab. 18, sl. 2). Krona  $M_1$  je najbolj obrabljena (predvsem protokonid in hipokonid),  $M_2$  manj in  $M_3$  zelo malo (tab. 17, sl. 2). Ob stiku posameznih molarjev so nastale precej globoke fasete. Na posteriorni steni krone  $M_1$  je takšna faseta široka že več kot 6 mm. Dolžine krone tako ne bi bilo več mogoče res natančno izmeriti. Po rentgenski sliki sodeč, se korenini kanina in  $M_3$  še nista docela zaprli, vendar ne manjka dosti. Pri recentnih medvedih se korenina kanina zapre okoli 4. leta (Marks & Erickson, 1966, 395, 397), to je v času, ko dosežejo spolno zrelost.

Pravkar opisana mandibula še ni dosegla svoje končne velikosti. Mandibule dorašlih samcev merijo v dolžino 5–10 centimetrov več. Rast čeljusti je torej napredovala tudi po četrtem letu. Pri recentnem črnem medvedu glava samcev raste prvih 8 let, pri samicah pa se ta rast ustavi nekoliko prej, kmalu po spolni zrelosti (Marks & Erickson, 1966, 400–402). Najbrž je bilo podobno tudi pri jamskih medvedih.

### Sklep

V prispevku je bil predstavljen ontogenetski razvoj zobovja pri jamskem medvedu oziroma pri medvedih nasploh. Proces zamenjave mlečnega zobovja in izraščanja stalnih zob se večinoma konča do poldruega leta življenja. Do takrat so posamezne ontogenetske faze dober indikator individualne starosti.

S pomočjo opisanih primerov in zbranih podatkov bomo lahko ocenili starost juvenilnih čeljustnic jamskega medveda in za silo tudi izoliranih juvenilnih zob. V bodoče bo treba natančno predstaviti tudi ontogenetski razvoj in kriterije za določanje individualne starosti pri posameznih (izoliranih) zobeh, ki so najpogosteje ohranjeni in najbolj informativni fosilni ostanki jamskega medveda.

V sklepu naj še enkrat povzamem glavne ugotovitve:

– Proces rasti zob in zamenjave mlečnega zobovja s stalnim je pri jamskem medvedu potekal na enak način, prek enakih in verjetno tudi sinhronih razvojnih faz kot pri sorodnih, danes živečih medvedih.

– Sklepamo lahko, da določena ontogenetska stopnja razvitosti zobovja jamskega medveda ustreza približno isti starosti osebkov kot pri rjavem medvedu. Razvoj zobovja pri jamskem medvedu ni smel bistveno zaostajati, saj so mladiči pri določeni starosti (6. ali vsaj 7. mesec življenja) potrebovali prvi par stalnih molarjev ( $M_1$  &  $M^1$ ), da so lahko pričeli žvečiti trdno rastlinsko hrano.

– Ta argument govori proti drugi možnosti, da je bil ontogenetski razvoj zobovja pri jamskem medvedu dejansko precej počasnejši kot pri današnjih medvedih. Takšna posebnost bi (v določenih okoliščinah) lahko ogrozila obstoj vrste. Omenjene domneve pa zaenkrat vendarle ne moremo in ne smemo povsem ovreči.

– Velikost čeljustnic je bila v prvem letu življenja (pa tudi kasneje) odvisna od velikosti stalnih zob, ki so se v temu času v njej razvijali in jo skoraj v celoti zapolnjevali.

– Rast čeljusti je bila pri mladičih jamskega medveda bistveno hitrejša kakor pri današnjem rjavem medvedu. Že pri enem letu je bila njihova mandibula tako velika kot pri odraslem rjavem medvedu. To seveda ne pomeni, da je bilo toliko večje tudi preostalo telo.

– Domnevamo, da je bil pri jamskih medvedih sekundarni spolni dimorfizem izražen že v prvem letu življenja; samci so imeli večje čeljusti od samic.

– Splošno uveljavljena metoda ločevanja zob na juvenilne, z odprto korenino in adultne, če je korenina zaprta, za večino zob pri jamskem medvedu ni ustrezna. Medved odraste okoli 4. leta. Korenina  $M_1$ , pa se na primer zapre že v prvem letu življenja (po 8. mesecu), večina drugih stalnih zob do poldruga leta in samo korenine  $M^2$ ,  $M_3$  in kaninov šele pri približno štirih letih.

– Pri študiju juvenilnih čeljustnic iz paleolitskega najdišča Divje babe I nismo mogli spregledati dejstva, da je večina primerkov nekoč verjetno pripadala približno sedemmesečnim mladičem, ki so torej poginili sredi poletja. To je v nasprotju z dosedanjim mnenjem, da množični ostanki v tipičnih nahajališčih jamskega medveda izvirajo od živali, ki so zaradi izčrpanosti poginile med hibernacijo, pred nastopom pomladi.

– Zanimiv problem in naloga v prihodnosti bo: z nadaljnjimi raziskavami in dodatnimi podatki dokazati to trditev in jo smiselno obrazložiti.

### Zahvala

Ivanu Turku, vodji izkopavanj v Divjih babah I, se zahvaljujem za material, ki mi ga je prepustil v obdelavo. Izkopavanja izvaja Inštitut za arheologijo Znanstvenoraziskovalnega centra SAZU. Na Kliniki za kirurgijo in male živali Veterinarske fakultete v Ljubljani so prijazno omogočili rentgensko slikanje čeljustnic jamskega in rjavega medveda, ki je lepo uspelo po strokovni zaslugi veterinarjev Teodore Ivanuša, Janeza Štublja in Gregorja Freliha. Andrej Bidovec (Veterinarska fakulteta, Ljubljana) in Ciril Štrumbelj (Gojitveno lovišče Medved, Kočevje) sta posredovala za primerjavo potrebne lobanje mladičev recentnega rjavega medveda iz Slovenije. Vida Pohar je pregledala manuskript. Iskreno se zahvaljujem tudi vsem drugim, ki so kakorkoli pomagali pri nastanku tega prispevka.

### References

- Abel, O., 1931: Die Degeneration des Höhlenbären von Mixnitz und deren wahrscheinliche Ursachen. In: O. Abel & G. Kyrle (eds.), Die Drachenhöhle bei Mixnitz. – Speläolog. Monogr. 7–9, 719–744, Wien.
- Bocherens, H., Fizet, M. & Mariotti, A., 1994: Diet, physiology and ecology of fossil mammals as inferred from stable carbon and nitrogen isotope biogeochemistry: implications for Pleistocene bears. – *Paleogeogr. Paleoclim. Palaeoecol.* 107, 213–225, Amsterdam.
- Couturier, M. A. J., 1954: L'ours brun (*Ursus arctos* L.). – 904 pp., Grenoble.
- Debeljak, I., 1996a: Starostna sestava populacije jamskega medveda iz Divjih bab. (Age structure of cave bear population from the Divje babe Cave.) – Magistrska naloga. Manuscript, 70 pp., 36 tab. Naravoslovnotehniška fakulteta, Oddelek za geologijo, Ljubljana.
- Debeljak, I., 1996b: A simple preparation technique of cave bear teeth for age determination by cementum increments. – *Rev. Paléobiol.* 15/1, 105–108, Genève.
- Debeljak, I., 1997: Age composition of the cave bear population from the Divje babe I Cave. – Int. Meeting on Man and Bear, Auberives-Pont en Royans (Vercors – Isère). (In press.)
- Dittrich, L., 1960: Milchgebissentwicklung und Zahnwechsel beim Braunbären (*Ursus arctos* L.) und anderen Ursiden. – *Morph. Jb.* 101/1, 1–141, Leipzig.

- Ehrenberg, K., 1931: Über die ontogenetische Entwicklung des Höhlenbären. In: O. Abel & G. Kyrle (eds.), Die Drachenhöhle bei Mixnitz. - Speläolog. Monogr. 7-9, 624-710, Wien.
- Ehrenberg, K., 1964: Ein Jungbärenskelett und andere Höhlenbärenreste aus der Bärenhöhle im Hartlesgraben bei Hieflau (Steiermark). - Ann. Naturhist. Mus. Wien 67, 189-252, Wien.
- Ehrenberg, K., 1973: Ein fast vollständiges Höhlenbärenneonatusskelett aus der Salzofenhöhle im Toten Gebirge. - Ann. Naturhist. Mus. Wien 77, 69-113, Wien.
- Koby, F.-Ed., 1949: Le dimorphisme sexuel des canines d'*Ursus arctos* et d'*U. spelaeus*. - Rev. Suisse Zool. 56, 675-687, Genève.
- Koby, F.-Ed., 1952: La dentition lactéale d'*Ursus spelaeus*. - Rev. Suisse Zool. 59, 511-541, Genève.
- Kryštufek, B., 1991: Sesalci Slovenije. - Prirodoslovni muzej Slovenije, 294 pp., Ljubljana.
- Kurtén, B., 1955: Sex dimorphism and size trends in the cave bear, *Ursus spelaeus* Rosenmüller & Heinroth. - Acta Zool. Fennica 90, 1-48, Helsinki.
- Kurtén, B., 1958: Life and death of the Pleistocene cave bear. A study in paleoecology. - Acta Zool. Fennica 95, 1-59, Helsinki.
- Kurtén, B., 1976: The cave bear story. Life and death of a vanished animal. - Columbia Univ. Press, 163 pp., New York.
- Macdonald, D. (ed.), 1985: The Encyclopedia of Mammals. Vol. 1. - Equinox (Oxford) Ltd., London.
- Macdonald, D. (ed.), 1996: Velika enciklopedija. Sesalci. - Založba Mladinska knjiga, 980 pp., Ljubljana.
- Marks, S. A. & Erickson, A. W., 1966: Age determination in the black bear. - J. Wildl. Manage. 30/2, 389-410, Washington.
- Musil, R., 1965: Die Bärenhöhle Pod hradem. Die Entwicklung der Höhlenbären im letzten Glazial. - Anthropos 18, 7-92, Brno.
- Nelson, D. E. & Ku, T.-L., 1997: Radiokarbonsko datiranje kosti in oglja iz Divjih bab I. Radiocarbon dating of bone and charcoal from Divje babe I cave. In: I. Turk (ed.). - Opera Instituti Archaeologici Sloveniae 2, 51-65, Založba ZRC, Ljubljana.
- Pohle, H., 1923: Über den Zahnwechsel der Bären. - Zool. Anz. 55, 266-277, Leipzig.
- Rădulescu, C. & Samson, P., 1959: Contribution à la Connaissance de la Dentition lactéale d'*Ursus spelaeus*. - Eiszeitalter u. Gegenwart 10, 205-216, Öhringen.
- Rausch, R. L., 1961: Notes on the black bear (*Ursus americanus* Pallas) in Alaska, with particular reference to dentition and growth. - Z. Säugetierk. 26/2, 77-107, Berlin.
- Rode, K., 1935: Untersuchungen über das Gebiß der Bären. - Monogr. Geol. Palaeont. Ser. II, H. 7, 162 pp., Leipzig.
- Turk, I. (ed.), 1997: Moustérienska "koščena piščal" in druge najdbe iz Divjih bab I v Sloveniji. Mousterian "bone flute" and other finds from Divje babe I cave site in Slovenia. - Opera Instituti Archaeologici Sloveniae 2, 223 pp, Založba ZRC, Ljubljana.
- Turk, I., Dirjec, J., Strmole, D., Kranjc, A. & Čar, J., 1989a: Stratigrafija Divjih bab I. Izsledki izkopavanj 1980-1986. (Stratigraphy of Divje babe I. Results of excavations 1980-1986.) - Razpr. IV. razr. SAZU 30, 161-207, Ljubljana.
- Turk, I., Dirjec, J. & Culiberg, M., 1989b: Divje babe I - novo paleolitsko najdišče in skupinsko grobišče jamskega medveda. Poskus tafonomske analize na podlagi vzorcev iz dveh sedimentnih in arheoloških kompleksov. (Divje babe I - a new palaeolithic site and a common grave of the cave bear. An attempt at a taphonomic analysis based on samples from a pair of sedimentary and cultural units.) - Arh. vest. 39-40, 13-60, Ljubljana.
- Turk, I., Dirjec, J., Debeljak, I. & Huber, Đ., 1992: Divje babe I - poskus uporabe statistične analize množičnih živalskih ostankov v paleolitski arheologiji. IV. Posamično najdeni zobje jamskega medveda. (Divje babe I - an attempt to apply statistical analysis to the mass animal remains in the palaeolithic archaeology. IV. Isolated teeth of cave bear.) - Arh. vest. 43, 7-22, Ljubljana.

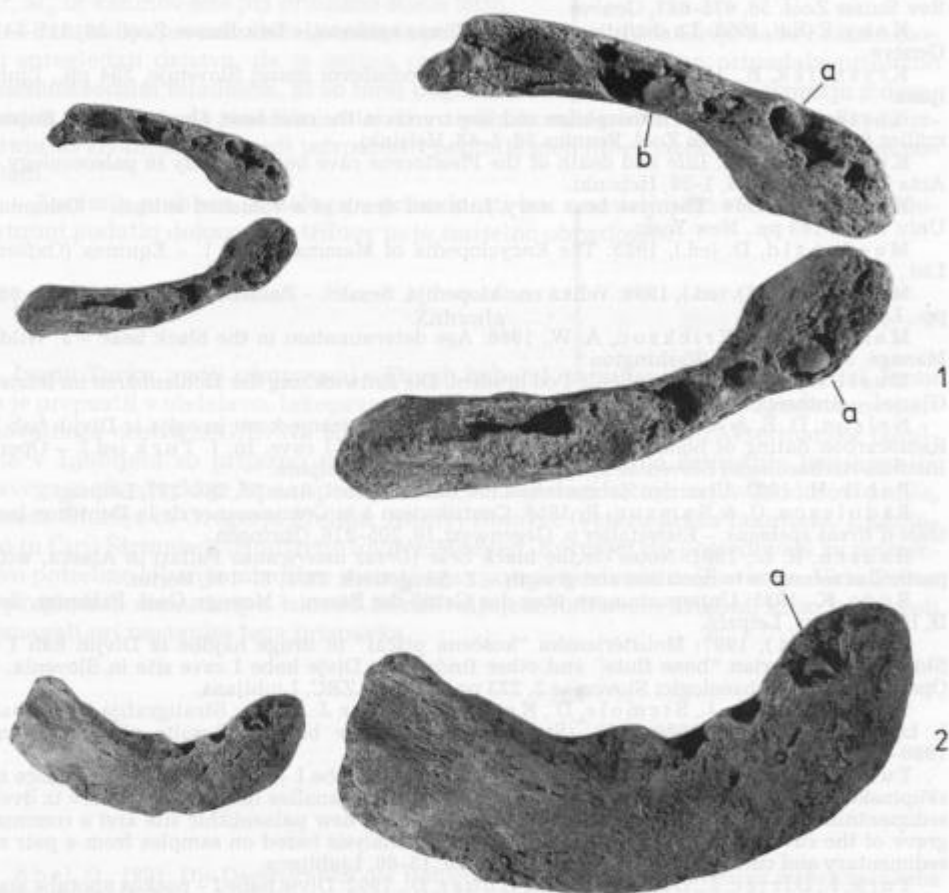


Plate 1 - Tabla 1

Cave bear; left and right mandible of two *neonates* (from Quad. 86, spit XV, and Quad. 24, spit XVII). Divje babe I

1 From above. Natural size (left) and magnification two times (right)

a = germ of deciduous canine, b = germ of deciduous premolar  $d_4$

2 Buccal side of right mandible. Natural size (left) and magnification two times (right)

Jamski medved; leva in desna mandibula dveh *neonatov* (iz Kv. 86, izkop XV in Kv. 24, izkop XVII). Divje babe I

1 Od zgoraj. Naravna velikost (levo) in dvakrat povečano (desno)

a = zametek mlečnega kanina, b = zametek mlečnega premolarja  $d_4$

2 Bukalna stran desne mandibule. Naravna velikost (levo) in dvakrat povečano (desno)



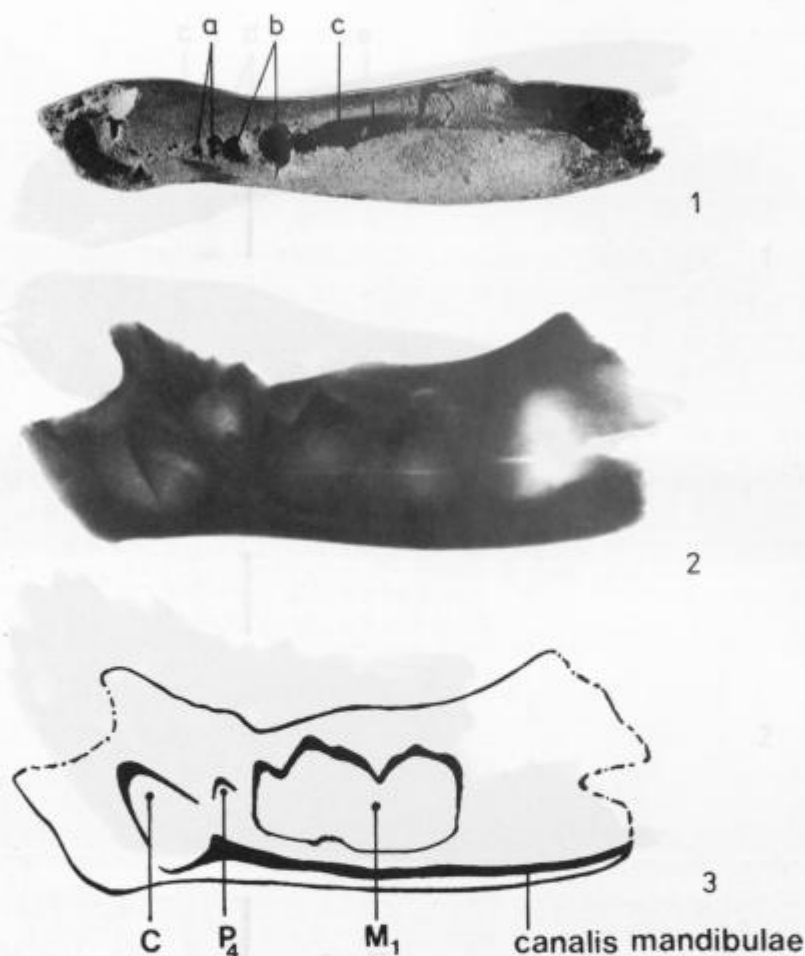


Plate 2 - Tabla 2

Cave bear; left mandible (inv. num. 1357) of a cub approx. 2-2.5 months old. Divje babe I. Natural size

- 1 From above  
a = alveolus for  $d_3$ , b = alveolus for  $d_4$ , c = fissure above  $M_1$
- 2 Lateral x-ray photograph (made at the Clinic for surgery and small animals of the Veterinary Faculty in Ljubljana)
- 3 Schematic illustration of germs of permanent teeth

Jamski medved; leva mandibula (inv. št. 1357) mladiča, starega okoli 2-2,5 meseca. Divje babe I. Naravna velikost

- 1 Od zgoraj  
a = alveola za  $d_3$ , b = alveola za  $d_4$ , c = reža nad  $M_1$
- 2 Rentgenski posnetek od strani (izdelan na Kliniki za kirurgijo in male živali Veterinarske fakultete v Ljubljani)
- 3 Shematska ponazoritev zametkov stalnih zob



**Plate 3**

Cave bear; left and right mandible (inv. num. 1375 and 1380) of a cub 2.5–3 months old. Divje babe I. Natural size

1 From above

a = alveolae for  $di_{1-3}$ , b = alveolus for  $dc$ , c = alveolus for  $d_3$ , d = alveolus for  $d_4$ , e =  $M_1$

2 Lateral x-ray photograph (made at the Clinic for surgery and small animals of the Veterinary Faculty in Ljubljana)

3 Schematic illustration of germs of permanent teeth

**Tabla 3**

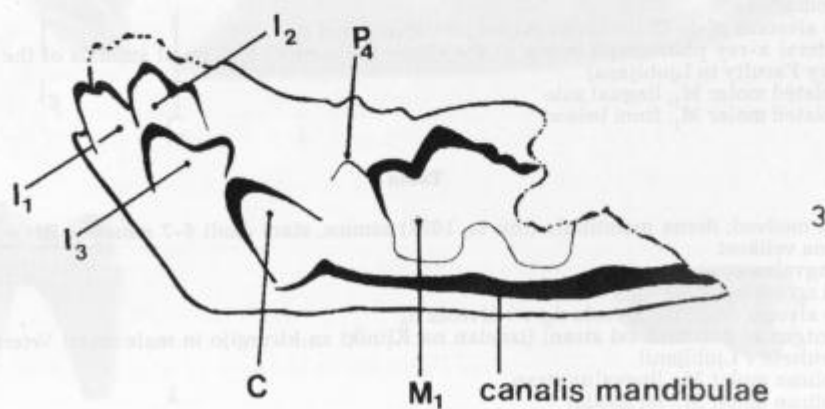
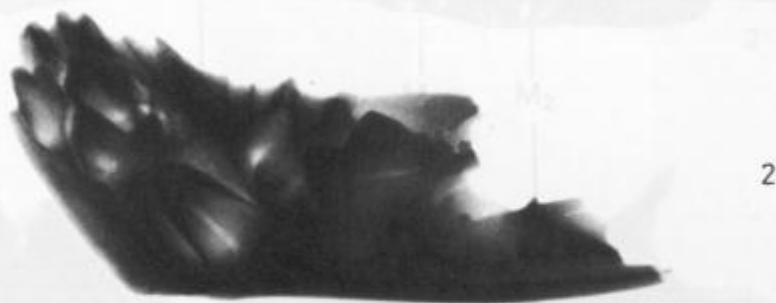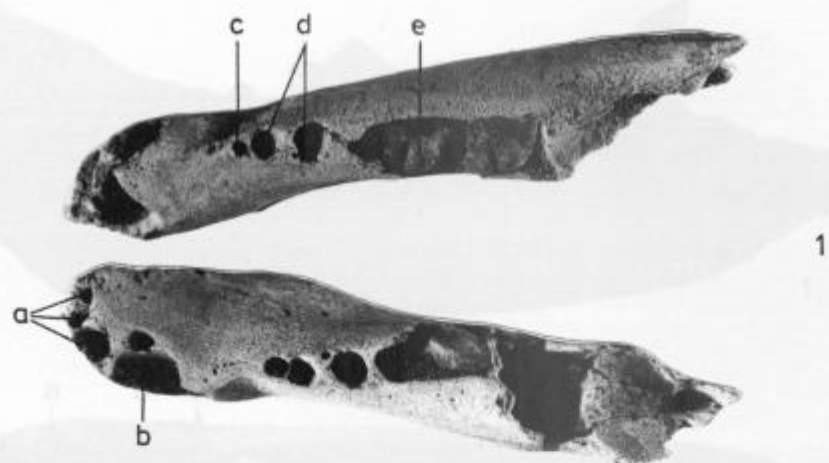
Jamski medved; leva in desna mandibula (inv. št. 1375 in 1380) mladiča, starega okoli 2,5–3 mesece. Divje babe I. Naravna velikost

1 Od zgoraj

a = alveole za  $di_{1-3}$ , b = alveola za  $dc$ , c = alveola za  $d_3$ , d = alveola za  $d_4$ , e =  $M_1$

2 Rentgenski posnetek leve mandibule od strani (izdelan na Kliniki za kirurgijo in male živali Veterinarske fakultete v Ljubljani)

3 Shematska ponazoritev zametkov stalnih zob





**Plate 4**

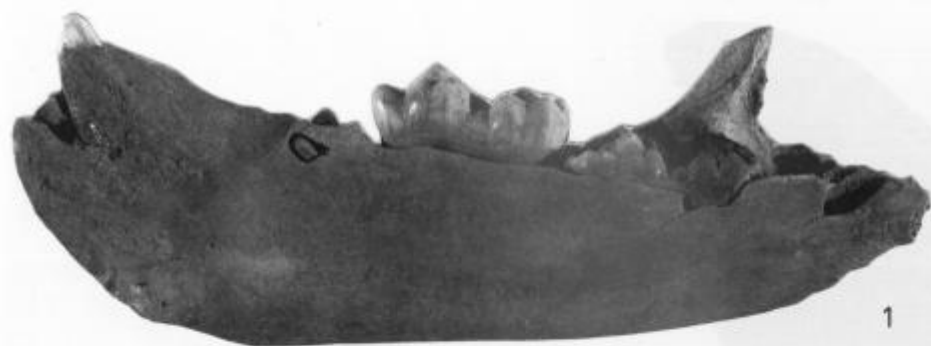Cave bear, right mandible (inv. num. 1033) of a female approx. 6-7 months old. Divje babe I. Natural size

- 1 Lingual side
- 2 From above
- 3 Lateral x-ray photograph (made at the Clinic for surgery and small animals of the Veterinary Faculty in Ljubljana)
- 4 Isolated molar  $M_1$ ; lingual side
- 5 Isolated molar  $M_1$ ; from below

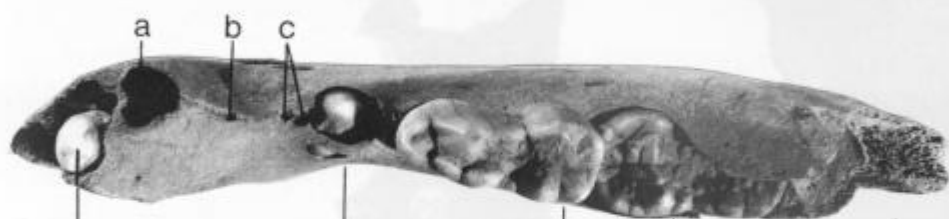**Tabla 4**

Jamski medved; desna mandibula (inv. št. 1033) samice, stare okoli 6-7 mesecev. Divje babe I. Naravna velikost

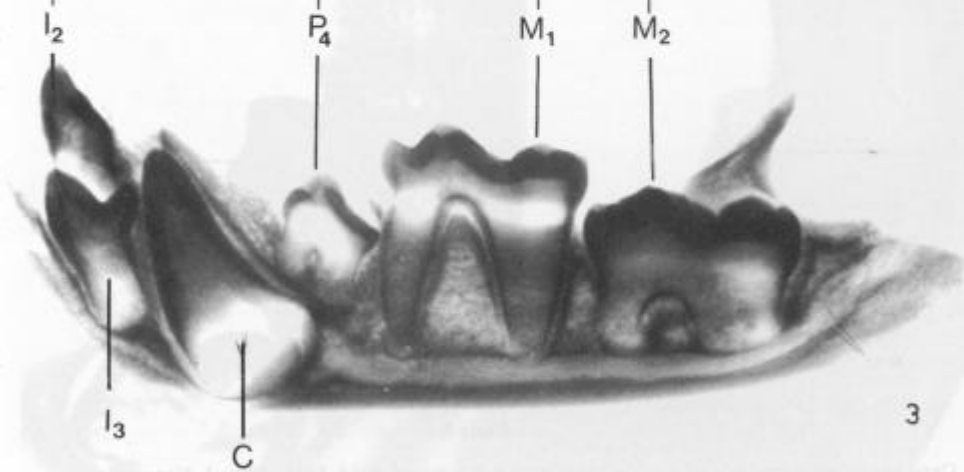
- 1 Lingvalna stran
- 2 Od zgoraj
- 3 Rentgenski posnetek od strani (izdelan na Kliniki za kirurgijo in male živali Veterinarske fakultete v Ljubljani)
- 4 Izoliran molar  $M_1$ ; lingvalna stran
- 5 Izoliran molar  $M_1$ ; od spoda



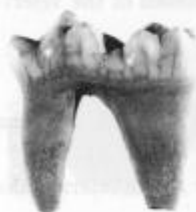1



2



3



4



5



**Plate 5**

Cave bear; left mandible of a male approx. 6.5–7.5 months old. Divje babe I. Natural size

1 Lingual side

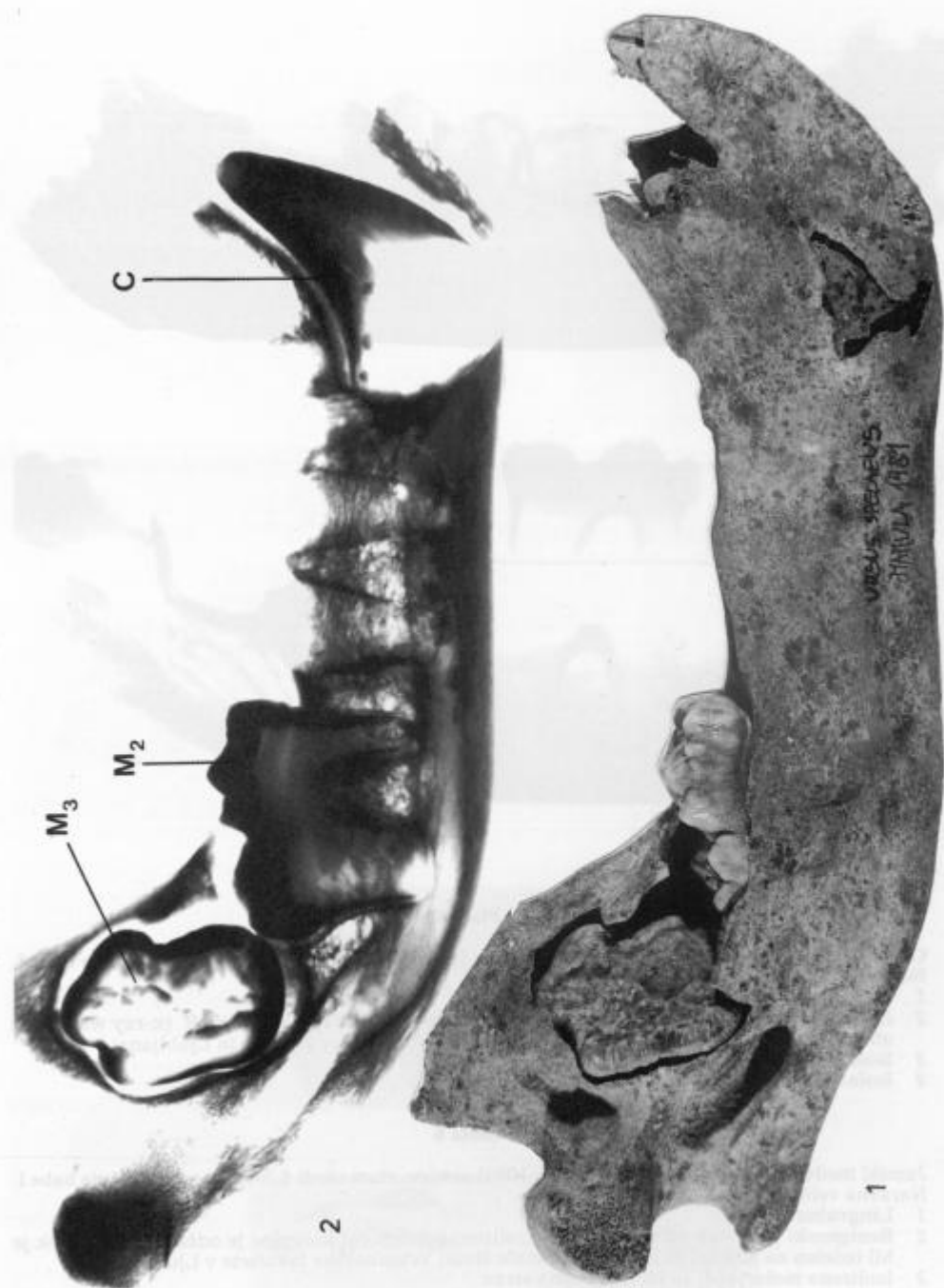
2 Lateral x-ray photograph (made at the Clinic for surgery and small animals of the Veterinary Faculty in Ljubljana)

**Tabla 5**

Jamski medved; leva mandibula samca, starega okoli 6,5–7,5 mesecev. Divje babe I. Naravna velikost

1 Lingvalna stran

2 Rentgenski posnetek od strani (izdelan na Kliniki za kirurgijo in male živali Veterinarske fakultete v Ljubljani)





**Plate 6**

Cave bear; right mandible (inv. num. 1095) of a female approx. 6.5–7.5 months old. Divje babe I. Natural size

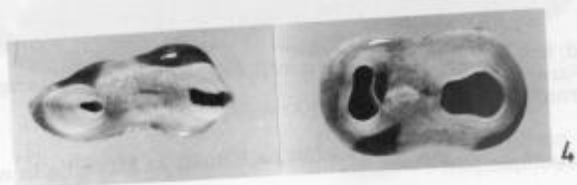
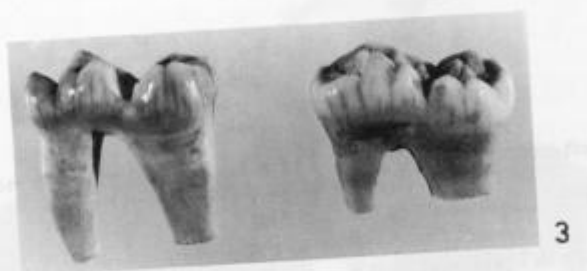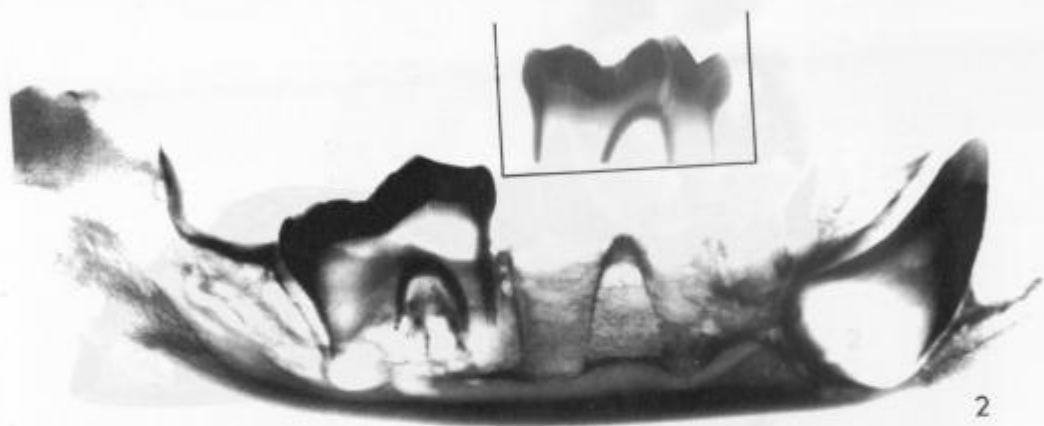
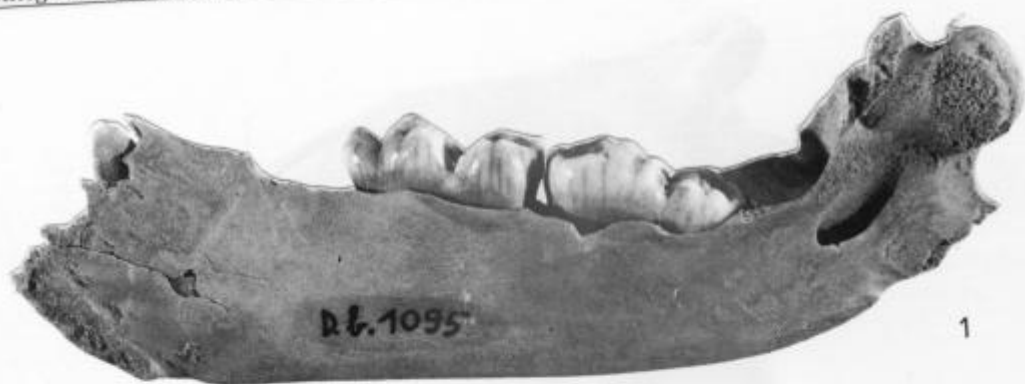- 1 Lingual side
- 2 Lateral x-ray photograph.  $M_1$  is isolated; lower part of its root is sawn off. (x-ray was made at the Clinic for surgery and small animals of the Veterinary Faculty in Ljubljana)
- 3 Isolated molars  $M_1$  and  $M_2$ ; lingual side
- 4 Isolated molars  $M_1$  and  $M_2$ ; from below

**Tabla 6**

Jamski medved; desna mandibula (inv. št. 1095) samice, stare okoli 6,5–7,5 mesecev. Divje babe I. Naravna velikost

- 1 Lingvalna stran
- 2 Rentgenski posnetek od strani.  $M_1$  je izoliran; spodnji del korenine je odžagan. (Posnetek je bil izdelan na Kliniki za kirurgijo in male živali Veterinarske fakultete v Ljubljani)
- 3 Izolirana molarja  $M_1$  in  $M_2$ ; lingvalna stran
- 4 Izolirana molarja  $M_1$  in  $M_2$ ; od spodaj







**Plate 7**

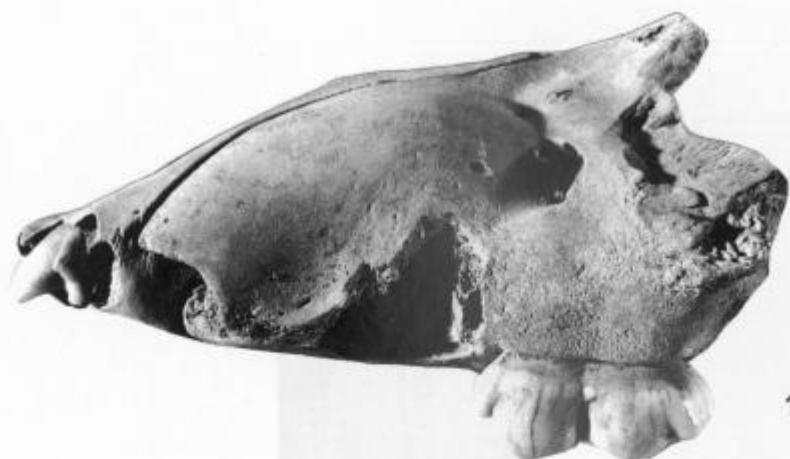Cave bear; left premaxilla and maxilla of a male approx. 6.5–7.5 months old. Divje babe I. Natural size

- 1 Buccal side
- 2 Occlusal
- 3 Lateral x-ray photograph (made at the Clinic for surgery and small animals of the Veterinary Faculty in Ljubljana)

**Tabla 7**

Jamski medved; leva medčeljustnica in zgornja čeljustnica sameca, starega okoli 6,5–7,5 mesecev. Divje babe I. Naravna velikost

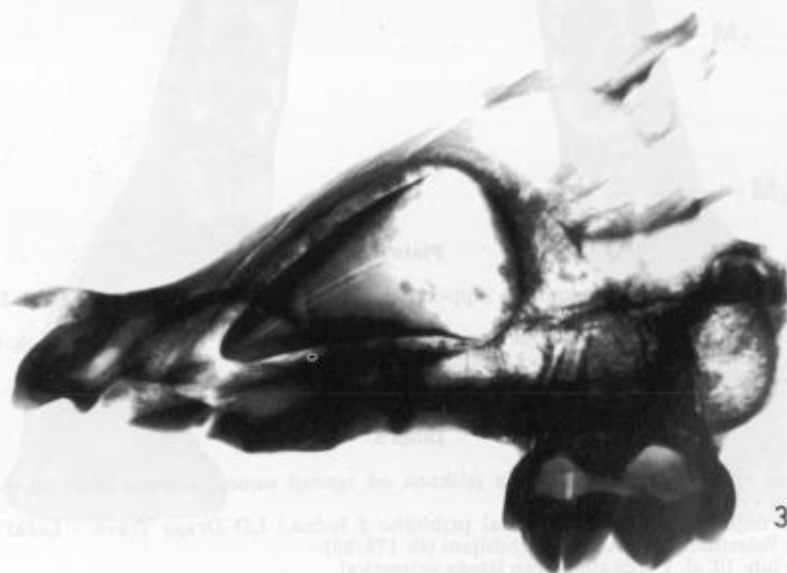- 1 Bukalna stran
- 2 Okluzalno
- 3 Rentgenski posnetek od strani (izdelan na Kliniki za kirurgijo in male živali Veterinarske fakultete v Ljubljani)



1



2



3

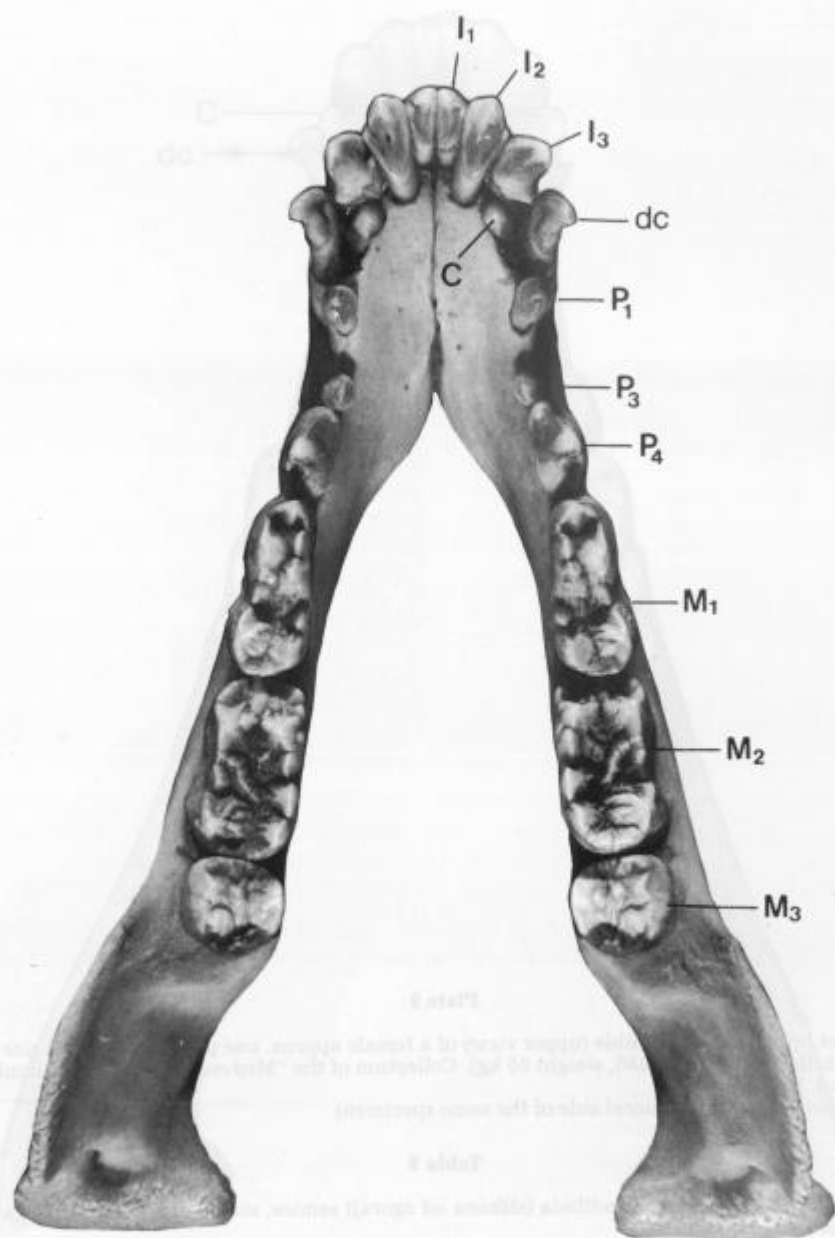


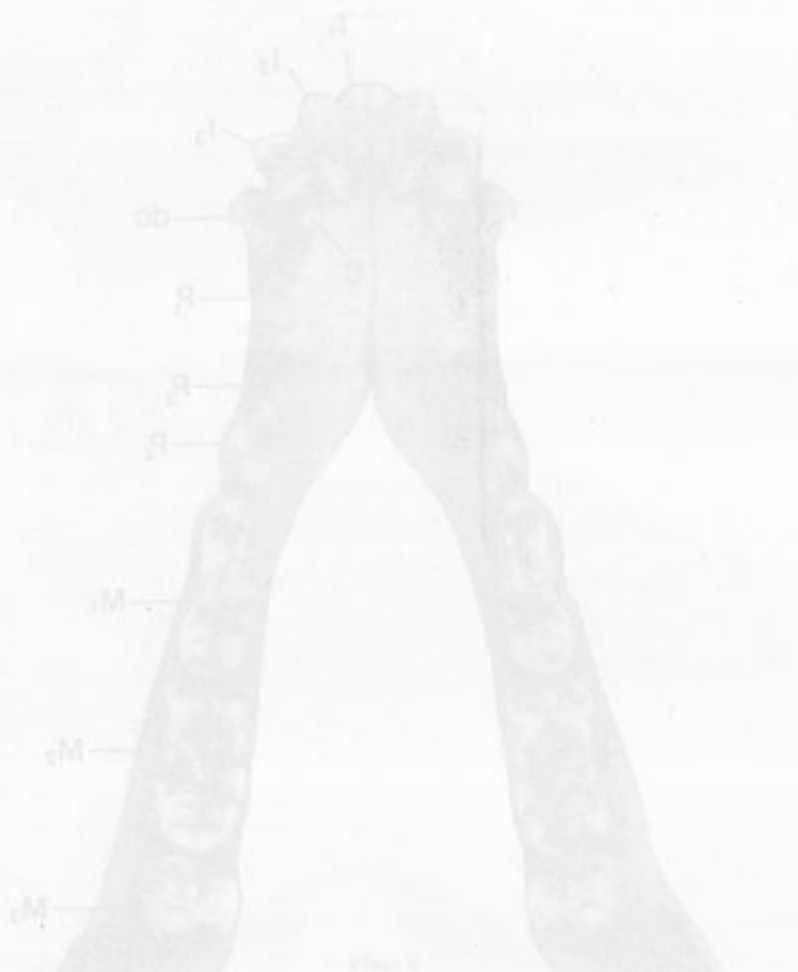
### Plate 8

- 1 Present-day brown bear; mandible (upper view) of a male approx. 10 months old. Natural size  
(Cub found on 28 Nov. 1989, about two weeks' decay.) LD Draga Trava – Loški potok. Collection of the Veterinary Faculty in Ljubljana (No. 178/89)  
See also Pl. 10, fig. 1 (buccal side of the same specimen)

### Tabla 8

- 1 Današnji rjavi medved; mandibula (slikana od zgoraj) samca, starega okoli 10 mesecev. Naravna velikost  
(Mladič najden 28. 11. 89, razpadal približno 2 tedna.) LD Draga Trava – Loški potok. Zbirka Veterinarske fakultete v Ljubljani (št. 178/89)  
Glej še tab. 10, sl. 1 (bukalna stran istega primerka)



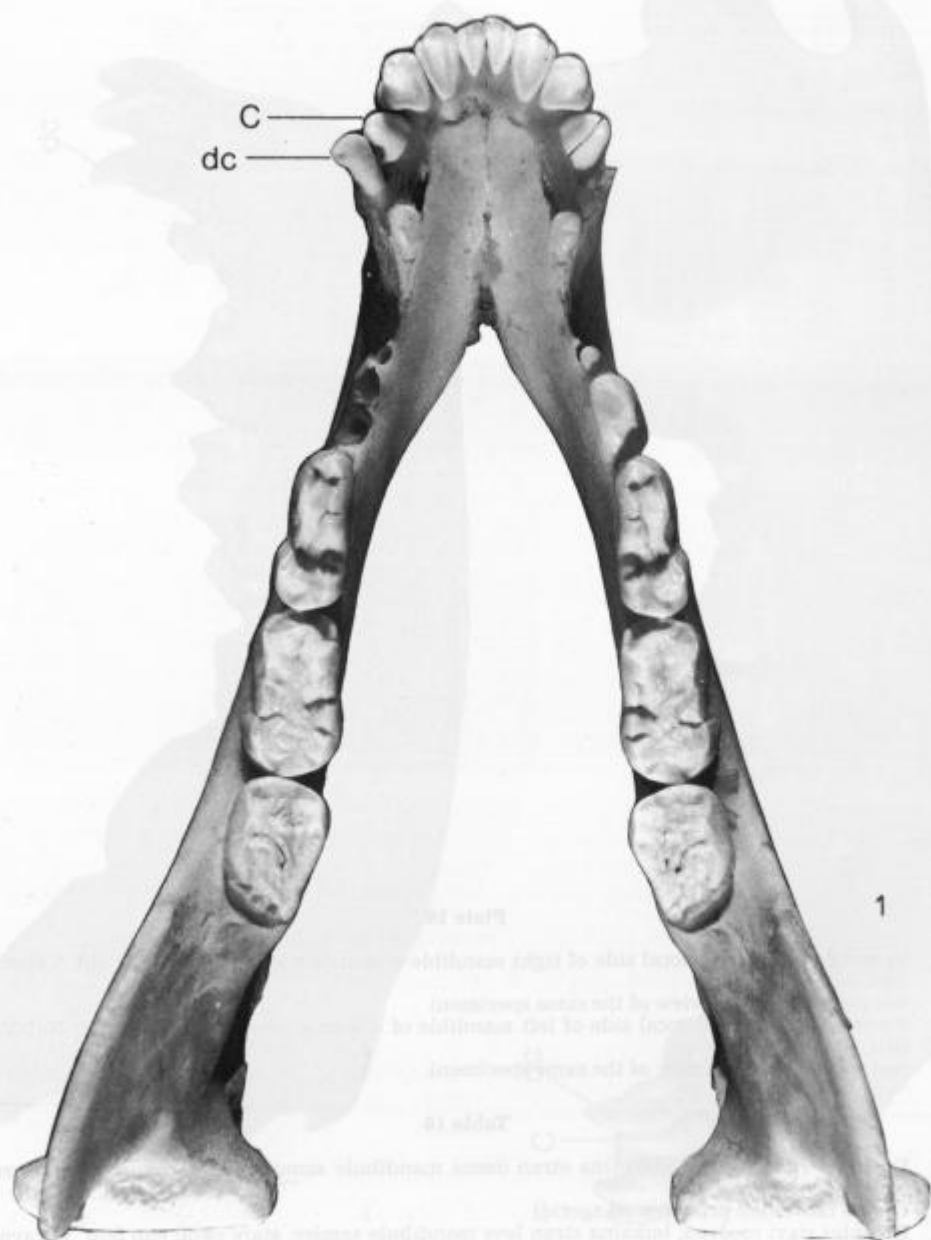

**Plate 9**

- 1 Recent brown bear; mandible (upper view) of a female approx. *one year* old. Natural size (Cub killed on 26 Dec. 1986, weight 55 kg). Collection of the "Medved" breeding and hunting ground, Kočevje  
See also PL 10, fig. 2 (buccal side of the same specimen)

**Tabla 9**

- 1 Današnji rjavi medved; mandibula (slikana od zgoraj) samice, stare okoli *eno leto*. Naravna velikost (Uplenjena 26. 12. 86, teža 55 kg.) Zbirka Gojitvenega lovišča "Medved", Kočevje  
Glej še tab. 10, sl. 2 (bukalna stran istega primerka)





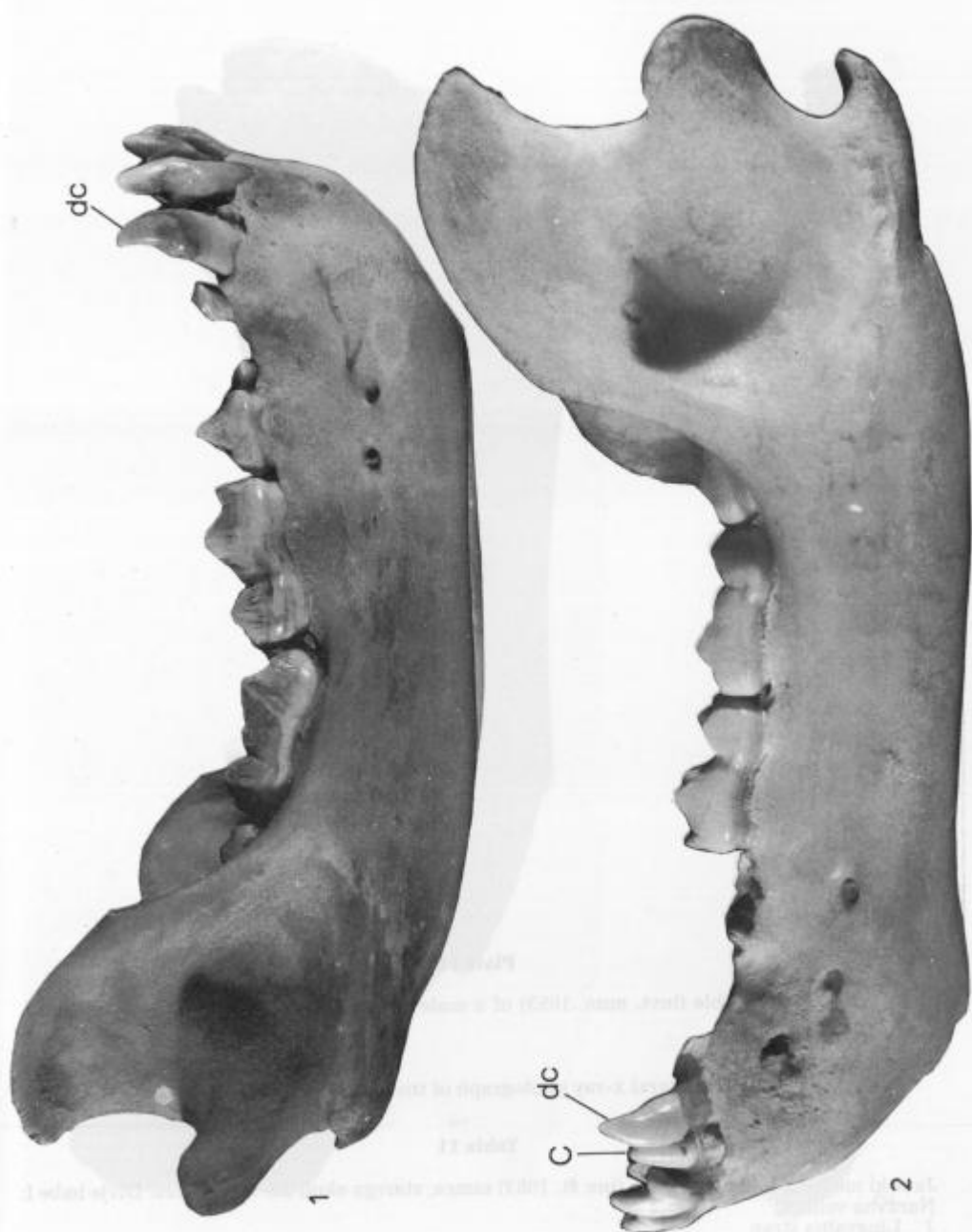
### Plate 10

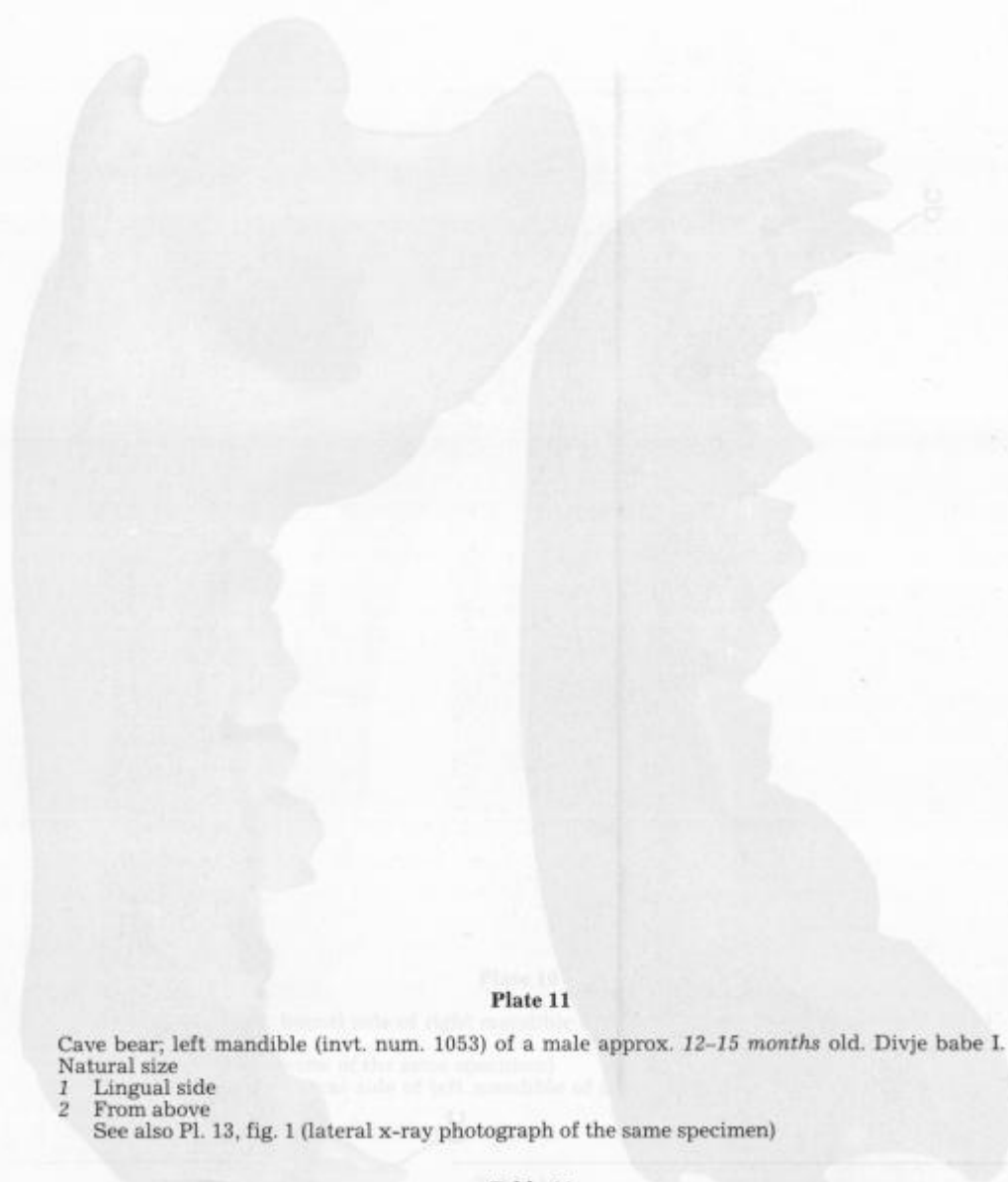
- 1 Recent brown bear; buccal side of right mandible of a male approx. *10 months* old. Natural size  
See also Pl. 8 (upper view of the same specimen)
- 2 Recent brown bear; buccal side of left mandible of a female approx. *one year* old. Natural size  
See also Pl. 9 (upper view of the same specimen)

### Tabla 10

- 1 Današnji rjavi medved; bukalna stran desne mandibule samca, starega okoli *10 mesecev*. Naravna velikost  
Glej še tab. 8 (isti primerek od zgoraj)
- 2 Recentni rjavi medved; bukalna stran leve mandibule samice, stare okoli *eno leto*. Naravna velikost  
Glej še tab. 9 (isti primerek od zgoraj)







### Plate 11

Cave bear; left mandible (inv. num. 1053) of a male approx. 12–15 months old. Divje babe I.  
Natural size

- 1 Lingual side
- 2 From above

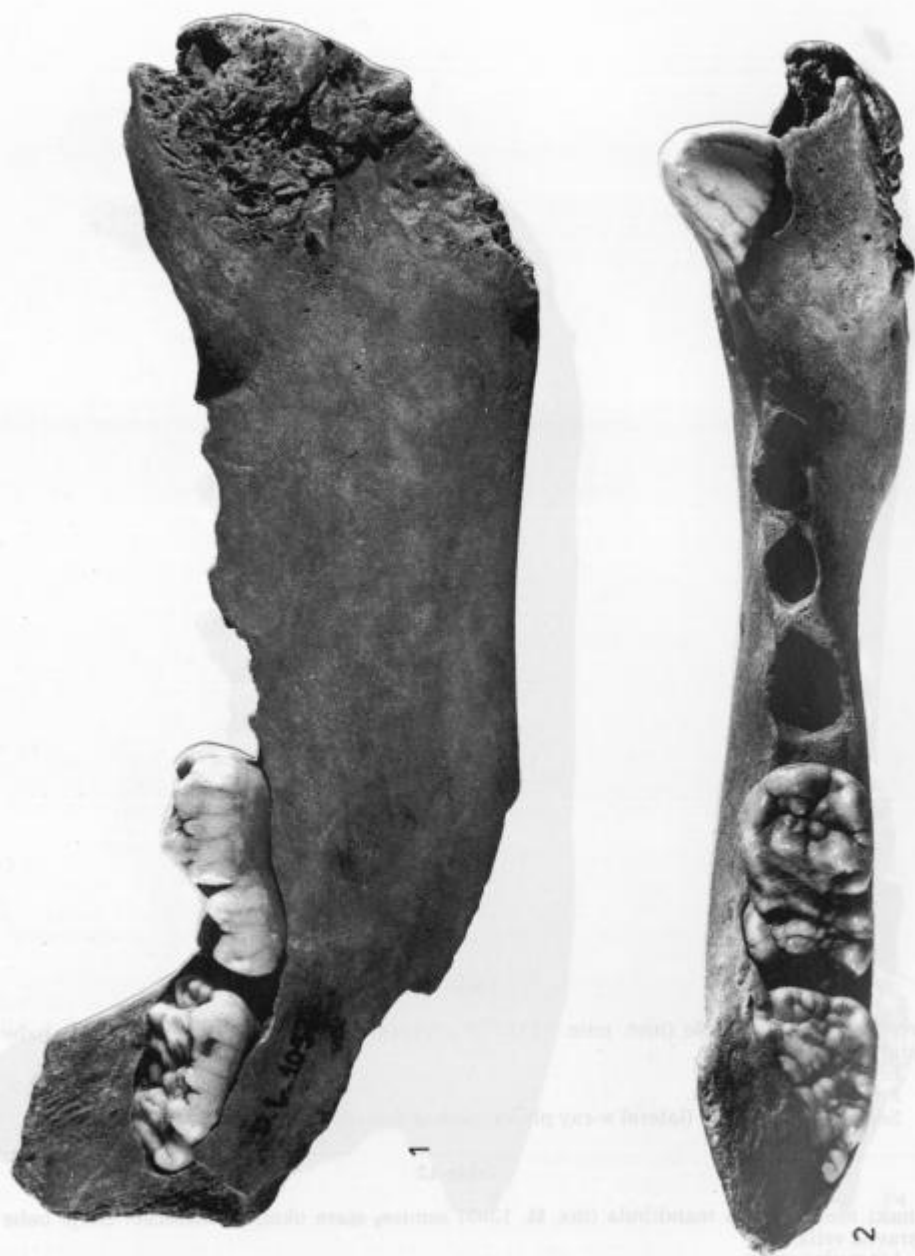See also Pl. 13, fig. 1 (lateral x-ray photograph of the same specimen)


### Tabla 11

Jamski medved; leva mandibula (inv. št. 1053) samca, starega okoli 12–15 mesecev. Divje babe I.  
Naravna velikost

- 1 Lingvalna stran
- 2 Od zgoraj

Glej še tab. 13, sl. 1 (lateralni rentgenski posnetek istega primerka)





**Plate 12**

Cave bear; left mandible (inv. num. 1385) of a female approx. 15 months old. Divje babe I. Natural size

1 Lingual side

2 From above

See also Pl. 13, fig. 2 (lateral x-ray photograph of the same specimen)

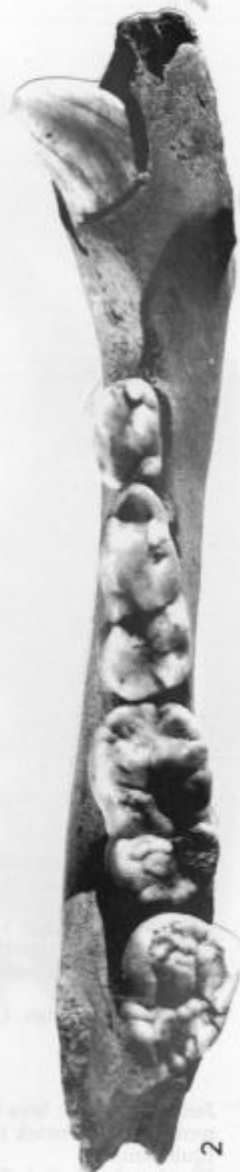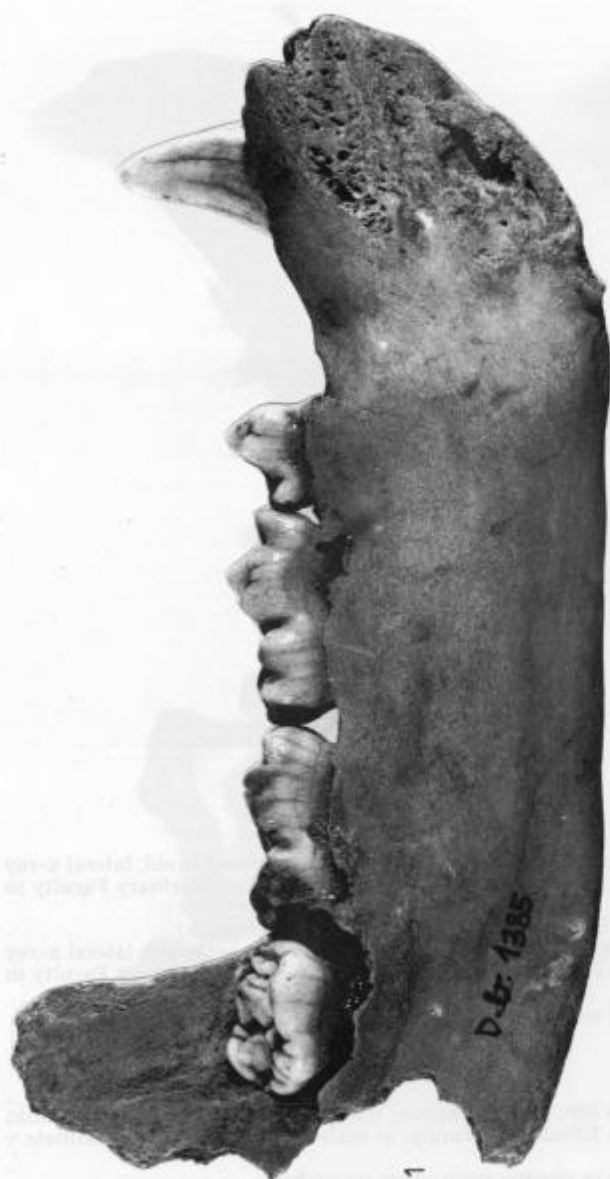**Tabla 12**

Jamski medved; leva mandibula (inv. št. 1385) samice, stare okoli 15 mesecev. Divje babe I. Naravna velikost

1 Lingvalna stran

2 Od zgoraj

Glej še tab. 13, sl. 2 (stranski rentgenski posnetek istega primerka)



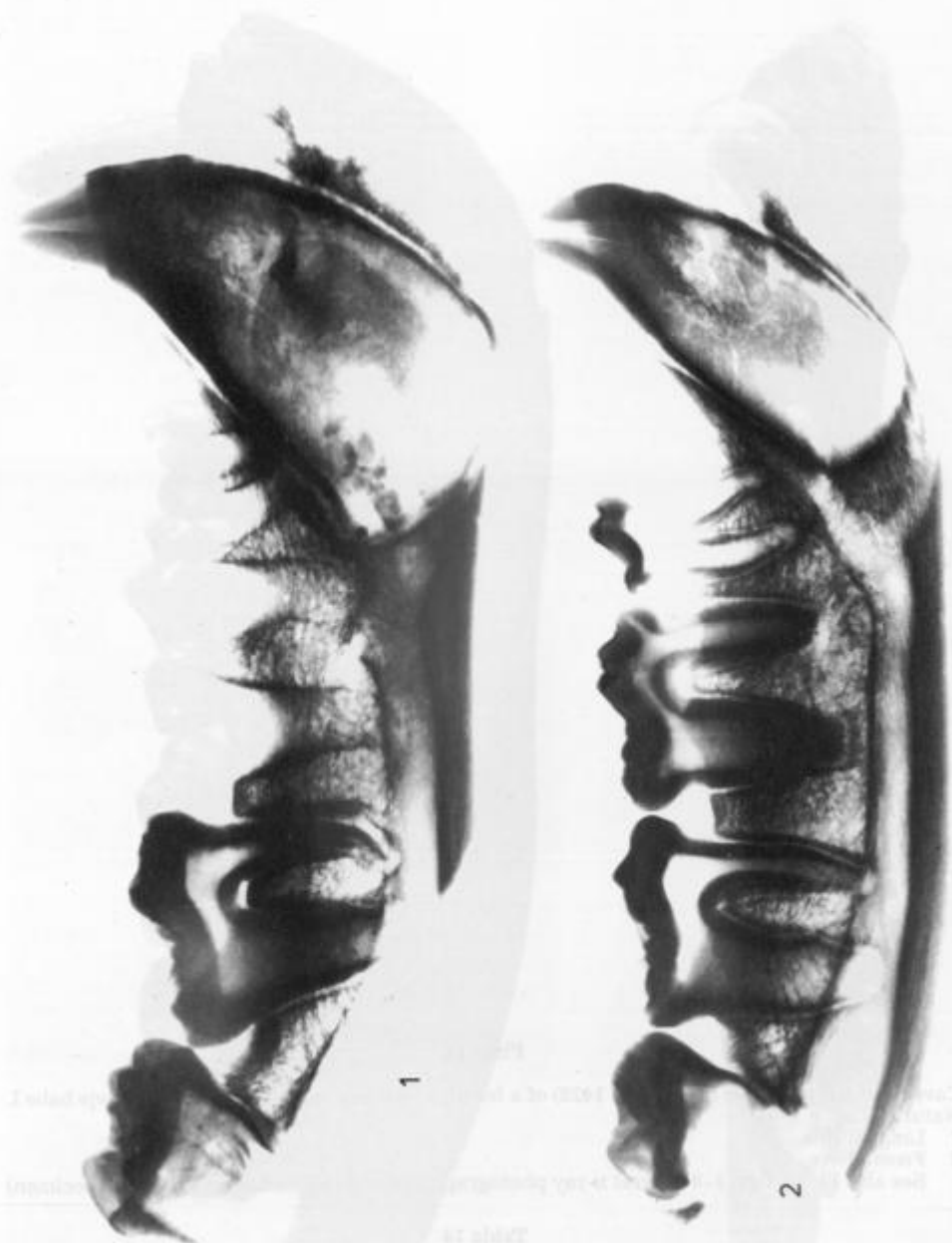


**Plate 13**

- 1 Cave bear; left mandible (inv. num. 1053) of a male approx. 12–15 months old; lateral x-ray photograph (made at the Clinic for surgery and small animals of the Veterinary Faculty in Ljubljana)  
See also Pl. 11, figs. 1, 2 (lingual side and upper view of the same specimen)
- 2 Cave bear; left mandible (inv. num. 1385) of a female approx. 15 months old; lateral x-ray photograph (made at the Clinic for surgery and small animals of the Veterinary Faculty in Ljubljana)  
See also Pl. 12, figs. 1, 2 (lingual side and upper view of the same specimen)

**Tabla 13**

- 1 Jamski medved; leva mandibula (inv. št. 1053) samca, starega okoli 12–15 mesecev; stranski rentgenski posnetek (izdelan na Kliniki za kirurgijo in male živali Veterinarske fakultete v Ljubljani)  
Glej še tab. 11, sl. 1, 2 (lingvalna in zgornja stran istega primerka)
- 2 Jamski medved; leva mandibula (inv. št. 1385) samice, stare okoli 15 mesecev; stranski rentgenski posnetek (izdelan na Kliniki za kirurgijo in male živali Veterinarske fakultete v Ljubljani)  
Glej še tab. 12, sl. 1, 2 (lingvalna in zgornja stran istega primerka)





**Plate 14**

Cave bear; left mandible (inv. num. 1428) of a female about *one and a half years* old. Divje babe I. Natural size

- 1 Lingual side
- 2 From above

See also Pl. 15, figs. 1-3 (lateral x-ray photograph and isolated molars of the same specimen)

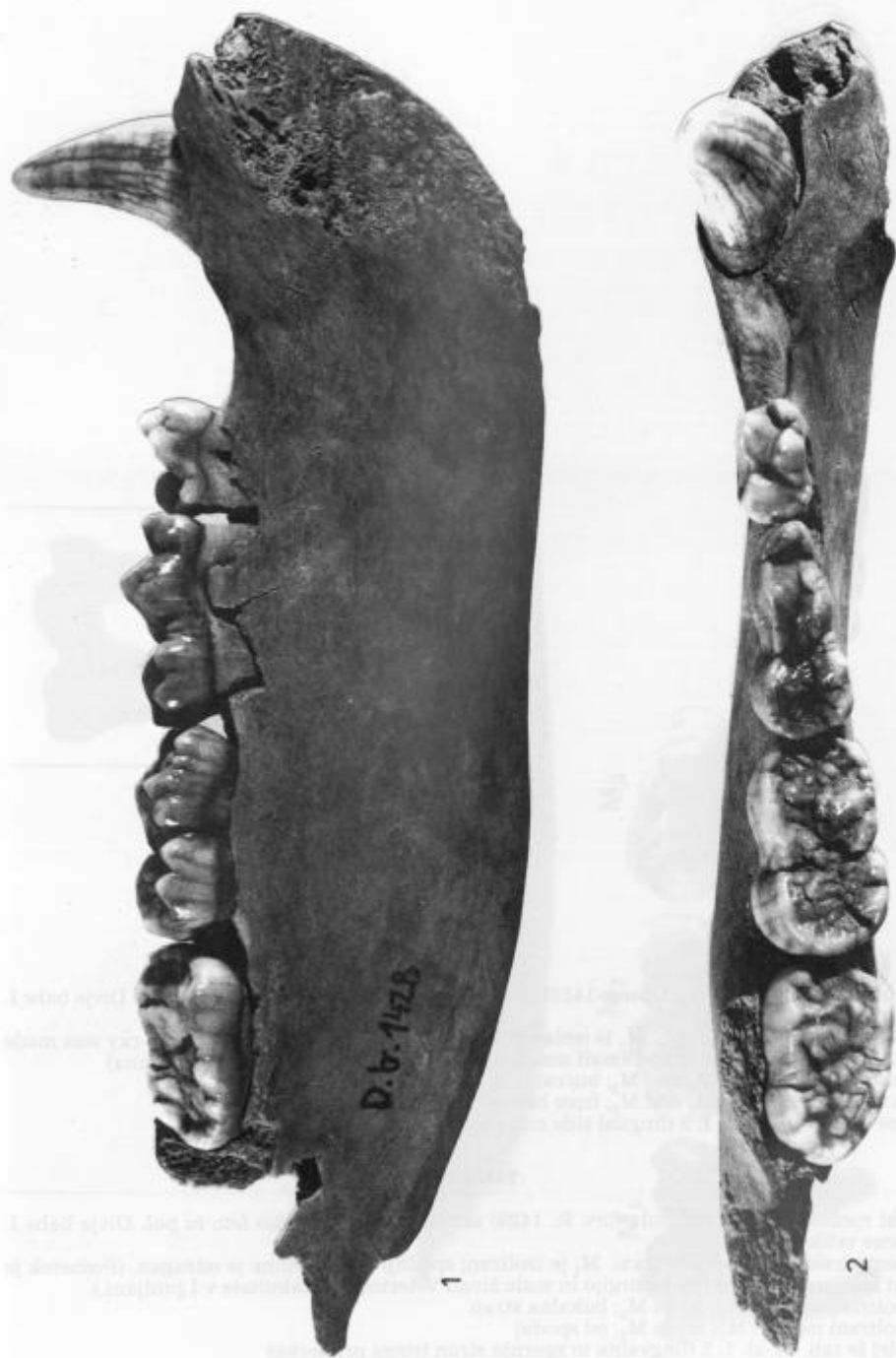
**Tabla 14**

Jamski medved; leva mandibula (inv. št. 1428) samice, stare *okoli eno leto in pol*. Divje babe I. Naravna velikost

- 1 Lingvalna stran
- 2 Od zgoraj

Glej še tab. 15, sl. 1-3 (stranski rentgenski posnetek in izolirani molarji istega primerka)







**Plate 15**

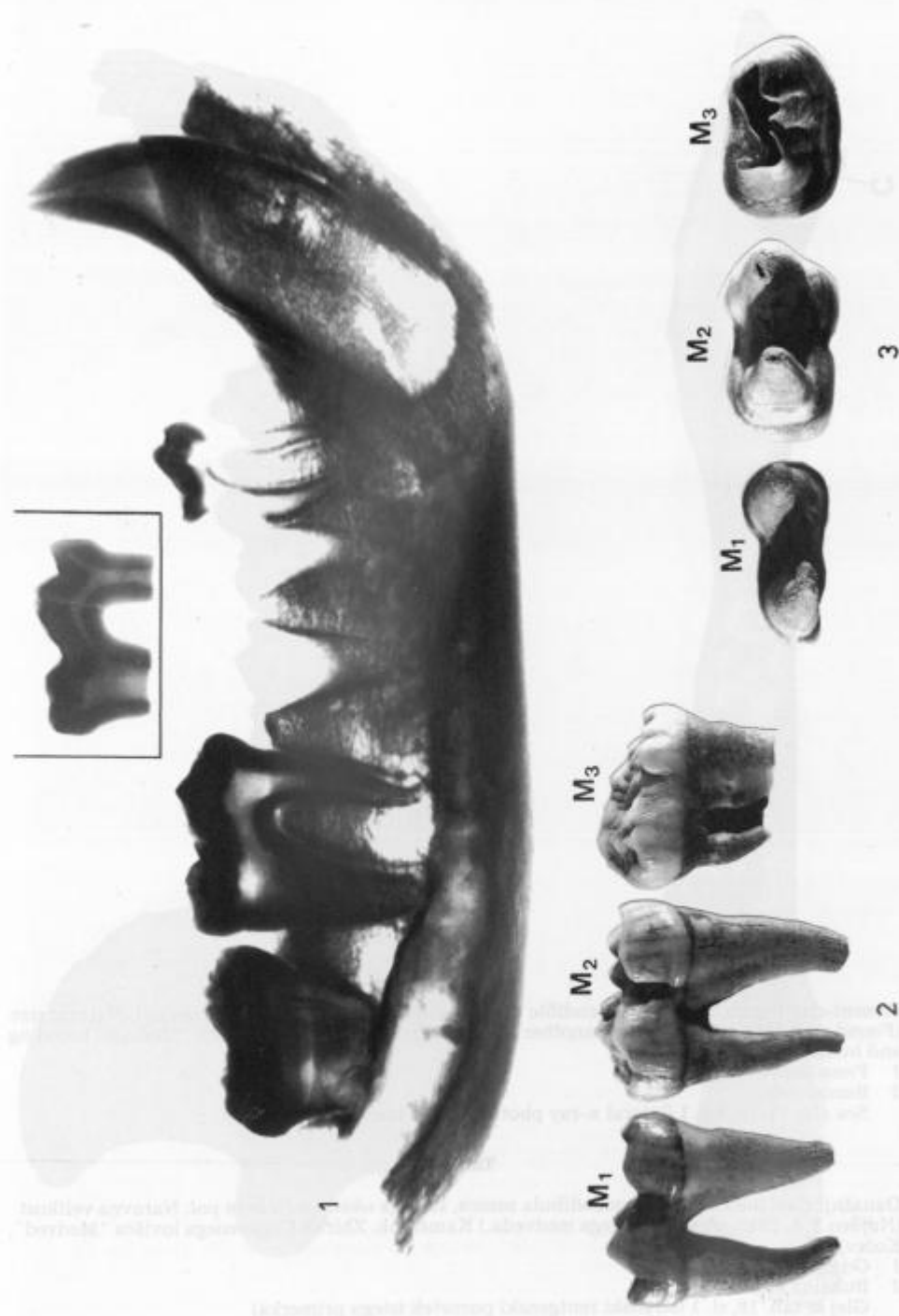
Cave bear; left mandible (inv. num. 1428) of a female about *one and a half* years old. Divje babe I. Natural size

- 1 Lateral x-ray photograph.  $M_1$  is isolated; lower part of its root is sawn off. (x-ray was made at the Clinic for surgery and small animals of the Veterinary Faculty in Ljubljana)
  - 2 Isolated molars  $M_1$ ,  $M_2$  and  $M_3$ ; buccal side
  - 3 Isolated molars  $M_1$ ,  $M_2$  and  $M_3$ ; from below
- See also Pl. 14, figs. 1, 2 (lingual side and upper view of the same specimen)

**Tabla 15**

Jamski medved; leva mandibula (inv. št. 1428) samice, stare okoli *eno leto in pol*. Divje babe I. Naravna velikost

- 1 Rentgenski posnetek od strani.  $M_1$  je izoliran; spodnji del korenine je odžagan. (Posnetek je bil izdelan na Kliniki za kirurgijo in male živali Veterinarske fakultete v Ljubljani.)
  - 2 Izolirani molarji  $M_1$ ,  $M_2$  in  $M_3$ ; bukalna stran
  - 3 Izolirani molarji  $M_1$ ,  $M_2$  in  $M_3$ ; od spodaj
- Glej še tab. 14, sl. 1, 2 (lingvalna in zgornja stran istega primerka)





**Plate 16**

Present-day brown bear; right mandible of a male approx. *one and a half years* old. Natural size (Found on 2 June 1992; killed by another bear). Kamenjak. Collection of the "Medved" breeding and hunting ground Kočevje

- 1 From above
- 2 Buccal side

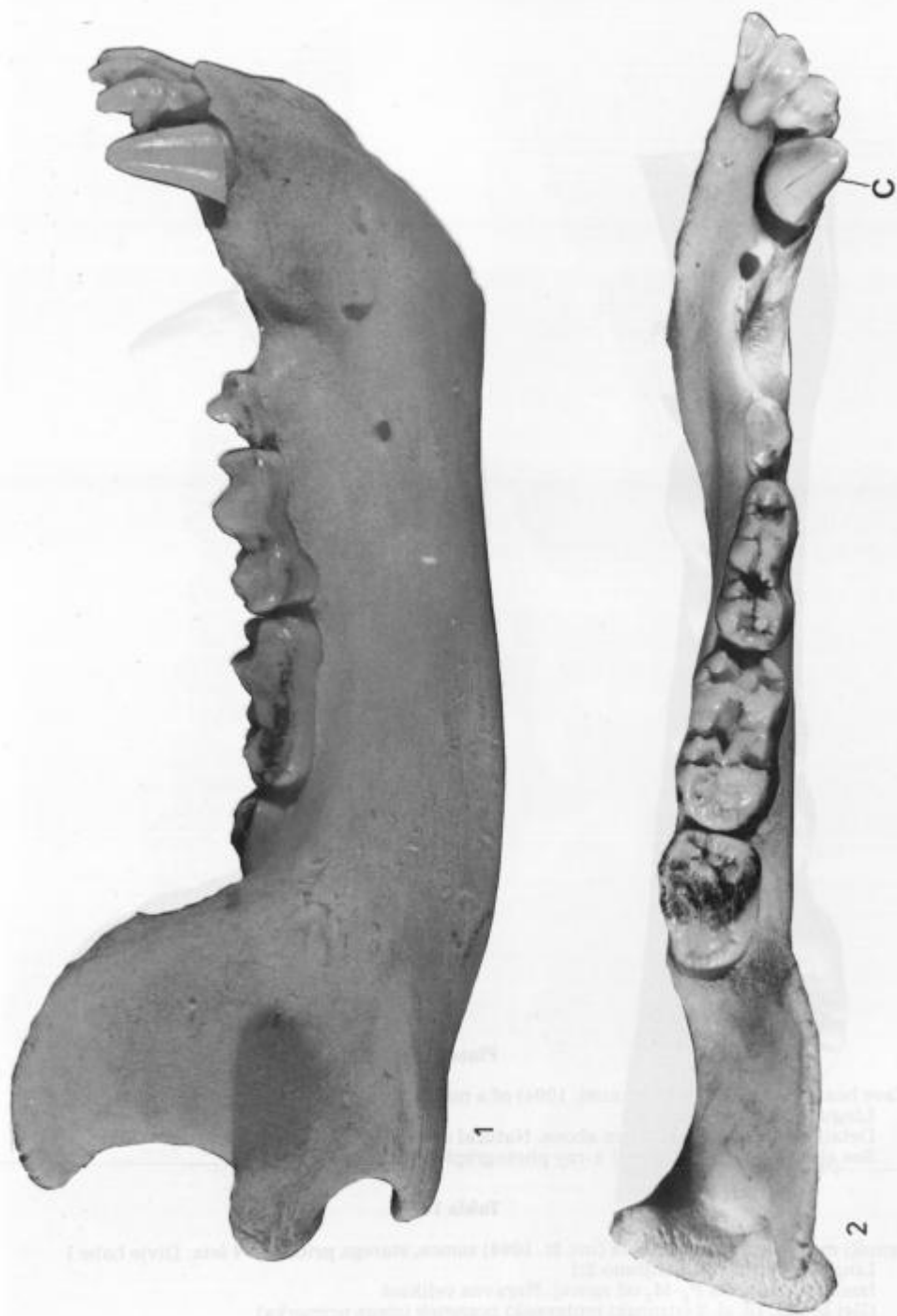
See also Pl. 18, fig. 1 (lateral x-ray photograph of the same specimen)

**Tabla 16**

Današnji rjavi medved; desna mandibula samca, starega *okoli eno leto in pol*. Naravna velikost (Najden 2. 6. 1992; ubit od drugega medveda.) Kamenjak. Zbirka Gojitvenega lovišča "Medved", Kočevje

- 1 Od zgoraj
- 2 Bukalna stran

Glej še tab. 18, sl. 1 (stranski rentgenski posnetek istega primerka)





**Plate 17**

Cave bear; left mandible (inv. num. 1094) of a male approximately 4 years old. Divje babe I

1 Lingual side. Reduction 2:1

2 Detail: tooth row  $P_4$ - $M_3$  from above. Natural size

See also Pl. 18, fig. 2 (lateral x-ray photograph of the same specimen)

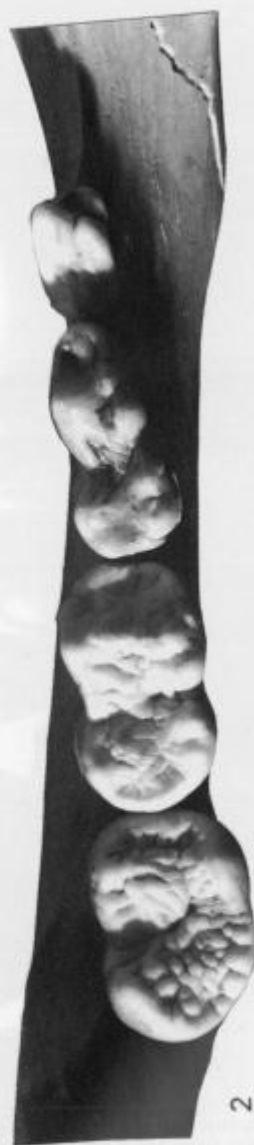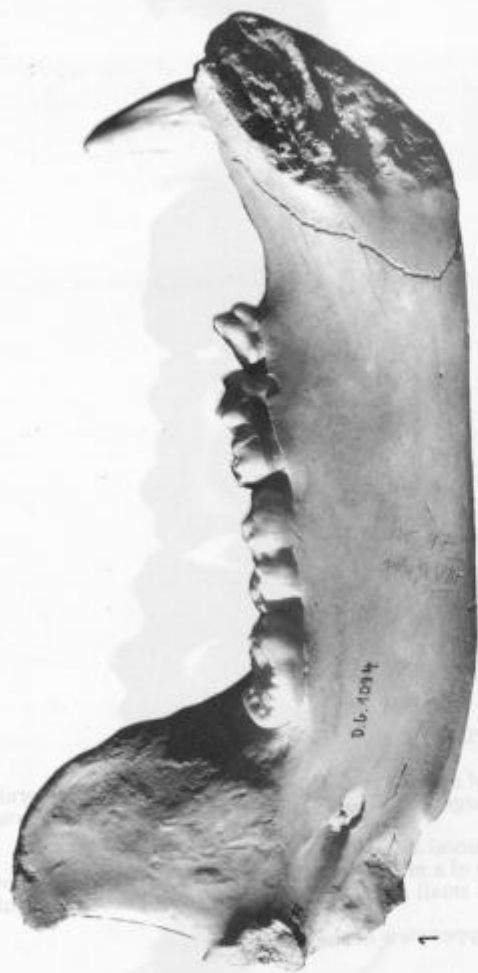**Tabla 17**

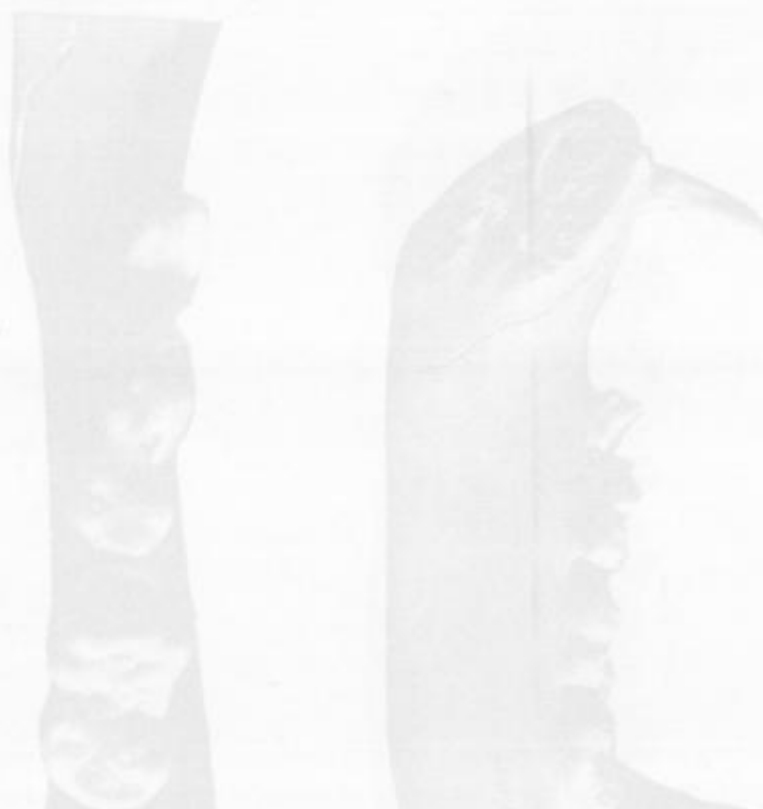Jamski medved; leva mandibula (inv. št. 1094) samca, starega približno 4 leta. Divje babe I

1 Lingvalna stran. Pomanjšano 2:1

2 Izsek: zobna vrsta  $P_4$ - $M_3$  od zgoraj. Naravna velikost

Glej še tab. 18, sl. 2 (stranski rentgenski posnetek istega primerka)





**Plate 18**

- 1 Present-day brown bear; right mandible of a male approx. *one and a half years* old; lateral x-ray photograph (made at the Clinic for surgery and small animals of the Veterinary Faculty in Ljubljana). Natural size  
See also Pl. 16, fig. 1, 2 (upper view and buccal side of the same specimen)
- 2 Cave bear; left mandible (inv. num. 1094) of a male approx. *4 years* old; lateral x-ray photograph (made at the Clinic for surgery and small animals of the Veterinary Faculty in Ljubljana). Natural size  
See also Pl. 17, fig. 1, 2 (lingual side and upper view of the same specimen)

**Tabla 18**

- 1 Današnji rjavi medved; desna mandibula samca, starega okoli *eno leto in pol*; stranski rentgenski posnetek (izdelan na Kliniki za kirurgijo in male živali Veterinarske fakultete v Ljubljani). Naravna velikost  
Glej še tab. 16, sl. 1, 2 (zgornja in bukalna stran istega primerka)
- 2 Jamski medved; leva mandibula (inv. št. 1094) samca, starega približno *4 leta*; stranski rentgenski posnetek (izdelan na Kliniki za kirurgijo in male živali Veterinarske fakultete v Ljubljani). Naravna velikost



