

Immediate two-stage tissue expander vs single-stage direct-to-implant breast reconstruction: two case reports of identical twins with BRCA 2 mutation

Takojšnja dvostopenjska rekonstrukcija dojke s tkivnim razširjevalcem v primerjavi s takojšnjo enostopenjsko rekonstrukcijo dojke z vsadkom: prikaz primerov enojajčnih dvojčic z mutacijo BRCA 2

Aleš Porčnik, Uroš Ahčan

Department of Plastic, Reconstructive and Aesthetic Surgery and Burns Unit, University Clinical Centre Ljubljana, Zaloška cesta 2, 1525 Ljubljana, Slovenia

Korespondenca/ Correspondence:

prof. dr. sc. Uroš Ahčan,
dr. med.,
e: uros.ahcan@kclj.si

Ključne besede:

mastektomija; BRCA mutacija; rekonstrukcija dojke; tkivni razširjevalec; vsadek

Key words:

mastectomy; BRCA mutation; breast reconstruction; tissue expander; implant

Citirajte kot/Cite as:

Zdrav Vestn 2015;
84: 771–79

Prispelo: 21. okt. 2014,
Sprejeto: 19. mar. 2015

Abstract

Background: After therapeutic or prophylactic mastectomy traditional immediate two-stage tissue expander breast reconstruction is the most common type of reconstruction, followed by more and more popular immediate single-stage direct-to-implant breast reconstruction. Both techniques have advantages and disadvantages. While direct-to-implant breast reconstruction is most common ly performed after prophylactic mastectomy; clear guidelines when each type of reconstruction is most appropriate still do not exist.

Case report: We present identical twin sisters, with BRCA 2 mutation, who underwent two different types of breast reconstruction. 1st twin (35 years old at first operation), underwent a therapeutic skin-sparing bilateral mastectomy and immediate two-stage tissue expander breast reconstruction. 2nd twin (42 years old at operation), underwent a prophylactic bilateral nipple-sparing mastectomy with immediate direct-to-implant breast reconstruction.

Conclusions: In order to achieve the best aesthetic result after immediate implant-based breast reconstruction, all the advantages and disadvantages of two-stage tissue expander and single-stage direct-to-implant breast reconstruction should be considered. Decision about the type of implant-based reconstruction is based

on the consultations outcomes after multidisciplinary team meeting of breast and reconstructive specialist, but patients own wishes should be prioritised.

Izvleček

Izhodišča: Po terapevtski ali profilaktični mastektomiji je najpogostejša oblika takojšnje rekonstrukcije dojke tradicionalna dvostopenjska rekonstrukcija s tkivnimi razširjevalci, kateri sledi vse bolj popularna enostopenjska rekonstrukcija z vsadki. Oba tipa rekonstrukcije imata svoje prednosti in slabosti. Čeprav je takojšnja enostopenjska rekonstrukcija dojke z vsadki najbolj pogosta po profilaktičnih mastektomijah, jasnih smernic o uporabi določenega tipa rekonstrukcije še ni.

Prikaz primera: Predstavljamo enojajčni dvojčici z mutacijo v genu BRCA 2, ki sta prestali dva različna tipa rekonstrukcije dojke. Prva dvojčica (stara 35 let ob prvi operaciji) je imela terapevtsko obojestransko mastektomijo z ohranjenim kožnim pokrovom in takojšnjo dvostopenjsko rekonstrukcijo dojke s tkivnim razširjevalcem. Druga dvojčica (ob operaciji stara 42 let), je imela profilaktično obojestransko mastektomijo z ohranitvijo bradavice in kolobarja in takojšnjo enostopenjsko rekonstrukcijo z vsadkom.

Zaključki: Če hočemo doseči najboljši končni estetski rezultat pri takojšnjih rekonstrukcijah

dojk z vsadki, moramo upoštevati vse prednosti in slabosti dvostopenjske oziroma enostopenjske rekonstrukcije dojke. O samem tipu rekonstrukcije se moramo na osnovi multidisciplinarnega

pristopa in pogovora s kirurgom onkologom in rekonstruktivnim kirurgom odločiti za vsak primer posebej, pri čemer so želje bolnice na prvem mestu.

Introduction

Breast cancer is the leading cause of cancer related mortality in women worldwide.¹ With the development of genetic counseling and patient's awareness, more women at higher risk of developing breast cancer are getting tested for BRCA 1 and/or BRCA 2 mutation.² Recent meta-analysis showed that women at the age of 70 have a 57 % and 49 % cumulative risk of developing breast cancer in BRCA 1 and BRCA 2 mutation carriers, respectively.² After prophylactic bilateral mastectomy risk reduction for developing breast cancer can reach 90 % and approximately 95 % in women with concurrent or prior bilateral prophylactic salpingo-oophorectomy, proving that the technique is oncologically a safe procedure.^{3,4}

During the last decade, number of women with breast cancer having bilateral mastectomy, doubled and more than tripled among women with higher risk for developing breast cancer (BRCA 1/2 mutation or a high family risk).⁵ After mastectomy (therapeutic or prophylactic) many options regarding breast reconstruction are available. Traditional immediate two-stage tissue expander breast reconstruction is conclusively the most common type of breast reconstruction, where tissue expander is placed in subpectoral pocket in the first stage, followed by multiple expander fillings and final expander replacement with a permanent implant in the second stage.¹ With the development of new materials, such as acellular dermal matrix (ADM) or different types of supportive meshes (titanium coated, Vicryl mesh) in the last decade, immediate single-stage direct-to-implant breast reconstruction became available and gained its popularity among carefully selected patients.⁶⁻⁹

Both methods have its advantages and disadvantages. While prophylactic mastectomy is more common and facilitates direct-to-implant breast reconstruction¹⁰,

there are still no clear guidelines when each method is preferred. We present two case reports of identical twins; each of them underwent a different type of breast reconstruction. The purpose is to compare both methods, discuss its highlights and show final result.

1st Case presentation

35 year old patient (1st twin sister), with the diagnosis of bilateral breast cancer, underwent a skin-sparing (SS) mastectomy with sentinel node biopsy and a subsequent immediate two-stage tissue expander breast reconstruction.

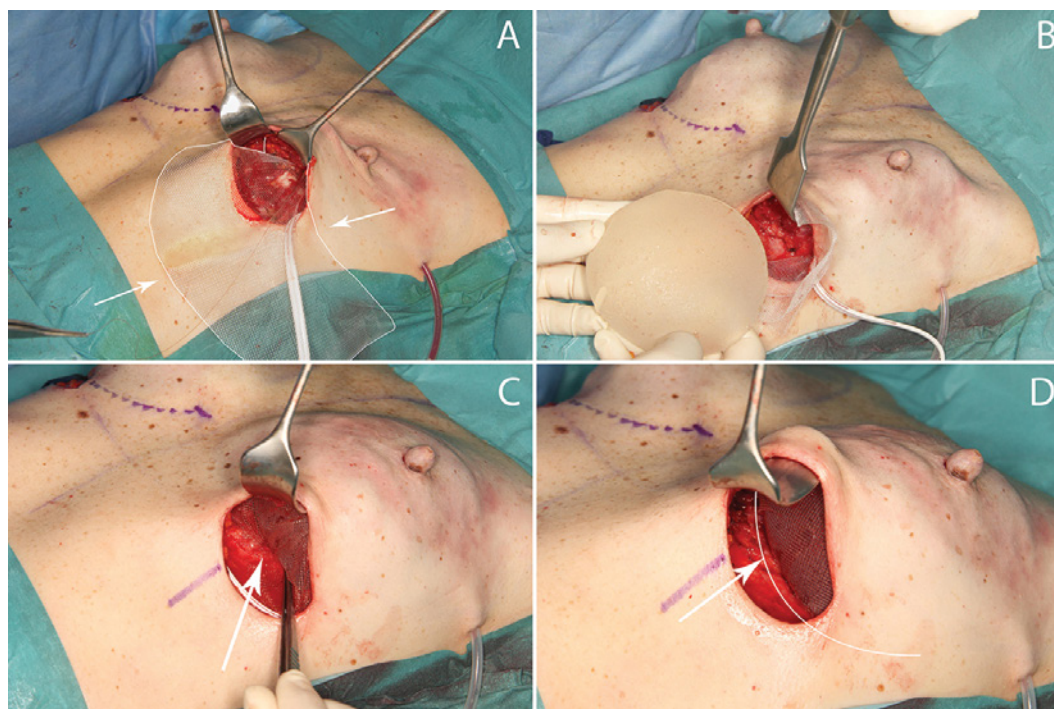
She noticed a lump in her right breast near the nipple areola complex (NAC) in June 2007. Few days later, thin needle aspiration biopsy confirmed the diagnosis of breast cancer. Her family history revealed that her grandmother had breast cancer and that her mother had ovarian cancer. At the end of the month, oncological-reconstructive MDT (multidisciplinary team) suggested therapeutic bilateral mastectomy and a two-stage tissue expander breast reconstruction. 2 weeks after her diagnosis, she underwent her 1st operation in which a surgical oncologist performed a skin-sparing mastectomy of both breasts, and then made a biopsy of sentinel node in her right axilla. A plastic surgeon continued with the operation and inserted appropriate tissue expanders (*Mc Ghan Style 133LV*), based on his previous measurements, under pectoralis major muscles. He filled the expanders with 80 ml of saline solution. The operation under general anaesthesia took two and a half hours to complete. After the procedure, patient had an uneventful hospital stay and was discharged after 4 days. Histopathological analysis of the removed breast has shown invasive ductal carcinoma (IDC) in her right breast

Table 1: Comparison of immediate two-stage tissue expander breast reconstruction with single-stage direct-to-implant breast reconstruction characteristics in identical twins with a BRCA 2 mutation.

Patient characteristic	Patient	
Patient's age at 1 st operation	35	42
Type of immediate breast reconstruction	two-stage tissue expander	single-stage direct-to-implant
Site of mastectomy	bilateral	bilateral
Type of mastectomy	therapeutic; SS, with additional SNB in RB	prophylactic; NS
Incision / excision approach	elliptical skin excision	inframammary skin incision
NAC	not preserved	preserved
Histopathological analysis	RB-IDC; LB-DCIS	no evidence of cancer
Adjuvant chemotherapy	Yes	No
Adjuvant radiotherapy	No	No
Supportive mesh used	No	Yes (titanium-coated polypropylene mesh -TiLOOP® Bra)
Type of implant and volume	anatomically shaped (Mentor CPG™ 321), 245 cm ³	anatomically shaped (Memory Gel CPG™ 323), 260 cm ³
Time to complete reconstruction	10 months	immediate
Overall operating time under general anesthesia	4 hours, 30 min	2 hours, 30 min
Overall operating time under local anesthesia	45 min	0
Overall number of operations	4	1
Operations under general anaesthesia	2	1
Operations under local anaesthesia	2	0
Number of outpatient visits	20	6
Number of visits due to expander fillings	8	0
Days spent in hospital	4 (1 st op.); 3 (2 nd op.)	7
Aesthetic result according to plastic surgeon	very good	very good
Erotic nipple arousal	not possible	possible
Breast skin sensitivity	Present (hypoesthesia)	Can still distinguish soft touch and pricks using two-point discrimination
Overall cost (€)	7140	4050
Laparoscopic-assisted bilateral prophylactic salpingo-oophorectomy	Yes (prior to mastectomy)	Yes (after mastectomy)
Picture of final aesthetic result	 	

SS – skin sparing; NS – nipple-sparing; SNB – sentinel node biopsy; RB – right breast; LB – left breast; IDC – invasive ductal carcinoma; DCIS – ductal carcinoma in situ; NAC – nipple areola complex.

Figure 1: Titanium-coated polypropylene mesh (TiLOOP® Bra) sutured to the inferior border of the pectoralis major muscle (A). Different stages of placing the implant in the definite submuscular position (B, C, D). Notice that the mesh is spreading around the implant and is fixed to the inframammary fold. White arrows indicate the position of the mesh.



with a negative sentinel node and residual ductal carcinoma in situ (DCIS) in her left breast. According to the mammary medical counsel, she received 4 cycles of chemotherapy and additional hormonal therapy for ovarian suppression. Results from the molecular genetic testing confirmed the mutation in the gene encoding BRCA 2. A month later, the surgeon began filling the expanders at the outpatient clinic for plastic surgery (10 minutes procedure without anesthesia). During the following months he repeatedly filled it with 40–60 ml of saline solution, until it reached the total volume of 245 ml in her right expander and 260 ml in her left expander. During two normal expander fillings, a complication occurred—she experienced a fracture of the 7th rib on the right side, which was treated conservatively.¹¹ Six months after her first operation and after 8 expander fillings altogether, a plastic surgeon performed second operation – exchange of both expanders with two identical permanent anatomically shaped silicone implants (*Mentor CPG™ 321, 245 cm³*). The operation under general anesthesia took two hours to complete. The patient remained in the hospital for additional three days. Two months after the operation, plastic surgeon reconstructed both nipples with “skate” flap under local anaesthesia (25 min) and a few months

later a nurse made a tattoo of the areola (20 min), thus ending the final two stages of breast reconstruction. Due to higher risk of ovarian cancer development, a gynaecologist performed laparoscopic-assisted bilateral prophylactic salpingo-oophorectomy. During the follow-up visits, two malignant melanomas and multiple dysplastic nevi were also removed.

2nd Case presentation

42 year old patient (2nd twin sister), with a mutation in BRCA 2 gene, underwent a prophylactic bilateral nipple-sparing (NS) mastectomy with an immediate direct-to-implant breast reconstruction.

At the end of the year 2007 molecular genetic testing revealed BRCA 2 mutation with a higher risk of developing breast and/or ovarian cancer. Four years later, a gynaecologist performed laparoscopic-assisted bilateral prophylactic salpingo-oophorectomy. Histological and cytological analysis showed no signs of malignancy. Oncological-reconstructive MDT presented her the possibility of bilateral prophylactic NS mastectomy, with immediate direct-to-implant breast reconstruction. Two years after the first procedure, a surgical oncologist performed NS mastectomy of both breast through an infra-

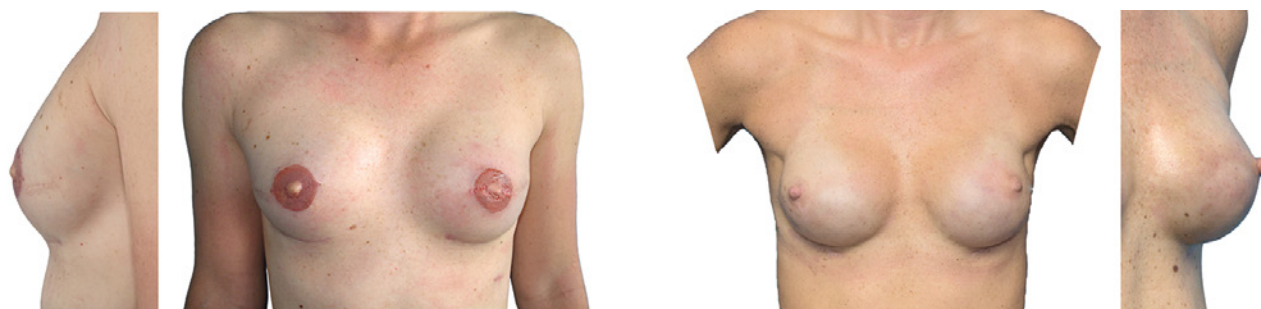

Figure 2: Final result of immediate two-stage tissue expander breast reconstruction (left-sided pictures); and of immediate single-stage direct-to-implant breast reconstruction (right-sided pictures).

mammary approach with a 7 cm long incision. Weight of each removed breast tissue was 130 g. Next, a plastic surgeon continued with a single-stage bilateral reconstruction and inserted permanent anatomically shaped silicone implants (*Memory Gel CPG™ 323*; 260 cm³). Titanized mesh implant TiLOOP® bra was used to cover and secure the position of the breast implant and to fix the pectoralis major muscle (Figure 1). The operation under general anesthesia took two hours and a half. The patient stayed in the hospital for seven days. There were no complications in postoperative recovery and wound healing.

Table 1 presents the characteristics of both patients in more detail. Because pre-operative picture of 1st identical twin that underwent immediate two-stage tissue expander breast reconstruction could not be found, only final postoperative pictures of both identical twins are shown in Figure 2. Pre and post-operative pictures of single-stage direct-to-implant breast reconstruction are shown in Figure 3.

Discussion

According to the American Society of Plastic Surgeons (ASPS) annual report from 2013 the most commonly performed breast reconstruction technique is two-stage tissue expander implant reconstruction, followed by single-stage direct-to-implant reconstruction with the ratio 10:1 among all implant-based breast reconstruction.¹² However, trends nowadays are showing increased number of immediate breast reconstruction in favour of single-stage compared to two-stage reconstruction, especially after NS mastectomy.^{5,13}

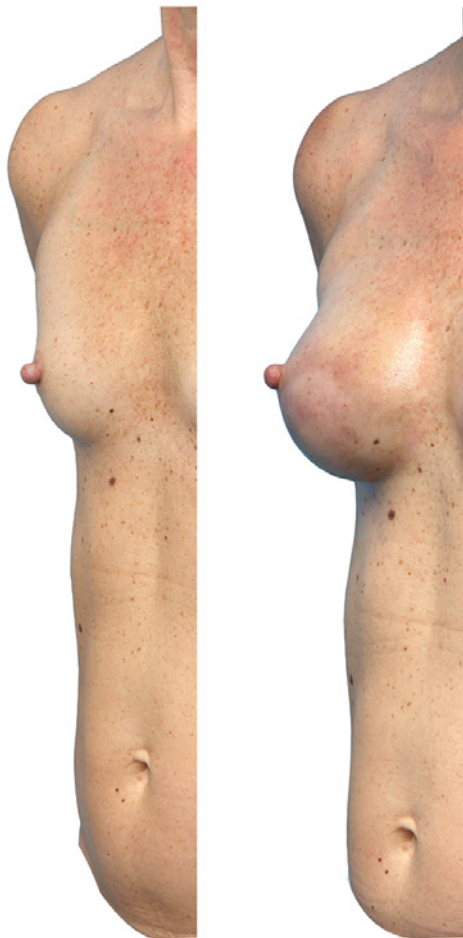Both, immediate two-stage tissue expander and single-stage direct-to-implant bre-

ast reconstruction are widely recognised surgical techniques for breast reconstruction, with its advantages and disadvantages gathered and presented in Table 2.^{6,14} It is important to emphasise that not everyone is a candidate for immediate direct-to-implant breast reconstruction, whereas immediate two-stage tissue expander breast reconstruction is more suitable for general female population. The choice of single or two-stage breast reconstruction is multi-factorial and also depends on the cup size, breast anatomy, patients desired breast volume, as well as on oncological considerations.¹³ The ideal patient for direct-to-implant reconstruction is a young woman after NS mastectomy, with small to moderate breast, grade 1 or 2 ptosis, optimal skin quality and minimal clinical or demographic co-morbidities.^{6,15}

Most common postoperative complications after implant-based breast reconstruction include skin flap necrosis, NAC necrosis, infections, seroma or hematoma formation, capsular contraction and loss of an implant.^{13,16} In the literature, complication rates vary considerably, however recently published studies show that medium-term (14–26 months) overall complication rates for immediate two-stage tissue expander (14.0–14.1 %)^{13,16} and single-stage direct-to-implant breast reconstruction (11.5–14.3 %)^{9,13,14,16} are similarly low and statistically insignificant. Independent risk factors for high complication rates include smoking, higher body mass index and preoperative radiotherapy.¹³

Recently, a large-scale, multi-institutional study showed that the rate of short-term complications (< 30 days) were significantly higher in single-stage breast reconstruction when compared to two-stage breast reconstruction.¹ Long term morbidity could

Figure 3: Pre- and post-operation pictures of single-stage direct-to-implant breast reconstruction.



not be calculated, because the data did not capture the possible complication of the 2nd operation of two-stage expander-implant breast reconstruction. They also did not mention which types of supportive mesh were included in single-stage breast reconstruction. In this study the early difference was most evident in reconstruction-related implant loss, followed by wound dehiscence at the incision site.¹ Predisposing factor for such early revision rate could be increased breast cup size compared to smaller breast cup sizes, obesity and prolonged operative time.^{8,17}

One theory suggests that the cause for high short-term complication rate in single-stage direct-to-implant breast reconstruction is increased tension on the overlying skin flap, caused by underneath pressure of permanent implant. Pressure can constrict vessels and compromise blood flow,

thus causing ischemia to surrounding and deep tissues.¹ In order to avoid such pressure, ADM and different types of supportive meshes are used. They provide extra cover to the implant and also represent additional layer to reduce implant visibility/palpability with less tension to the overlying skin envelope. Damage to the overlying skin flap can be further minimised with a proper surgical technique, which limits traction and thermal injury, thus preserving nutrition vessels in the dermis.^{18,19} Adequately thick skin flap can further minimise possibility of skin necrosis. One study showed that areola flap thickness < 5 mm is a predisposing factor for skin necrosis.¹⁹ Other predisposing factors for mastectomy flap necrosis include vascular comorbidities (diabetes, hypertension), smoking, patients age (> 65 years), obesity (BMI > 30), greater breast volume and periareolar incision involving more than a third of the NAC circumference.^{13,15} If NAC ischemia still occurs, prolonged conservative treatment measures are very successful, with low percentage of permanent depigmentation.¹⁵ In order to minimise high complication rate, proper patient selection is mandatory.

It is important to mention, that intra-operative assessment of the skin flap perfusion could influence the decision for an immediate direct-to-implant breast reconstruction.^{7,20} Intra-operatively tissue perfusion assessment can be unreliable based on clinical judgment, or on more reliable non-invasive objective methods. Flap perfusion can be measured with a tissue oxymeter on the basis of blood oxygen saturation²⁰ or with more novel SPY Imaging System, which is a laser angiography technique using a fluorescence agent.²⁰ In the setting of SS or NS mastectomies, SPY could evaluate skin and NAC perfusion and predict skin necrosis. Intraoperative detection of sub-optimal perfusion rate could change the operative planning, performing staged tissue expander breast reconstruction in order to decrease the skin tension and improve aesthetic outcome.^{7,20,21}

Major drawbacks of two-stage tissue expander breast reconstruction are multiple operations with longer overall hospitaliza-

tion. This results in a longer reconstructive time before final result is reached. In our 1st case presentation patient had 4 operations (2 under general anaesthesia, 2 under local anaesthesia) with an overall time of 10 months in between. Patients also need to have more outpatient visits, which can severely compromise their flexibility. On the other hand, single-stage direct-to-implant breast reconstruction requires only one operation, but with a slightly higher early reoperation rates. It is possible that higher reoperation rates are due to surgeon's learning curve and that this method of breast reconstruction will represent a gold standard in the future for the carefully selected patients.¹³

Since obtaining a good aesthetic result in immediate direct-to-implant breast reconstruction is more difficult to achieve, final results still show high satisfactory rate, according to patients themselves and to independent residents of plastic surgery.¹⁴ In fact, post-operative aesthetic results for both types of breast reconstructive show no significant difference and give good aesthetic result in general.²² In our case presentations,

postoperative photographs show good final aesthetic results, with good symmetry, shape and well-defined inframammary fold. Both patients are also very satisfied with their end result, which is the most important outcome factor.

Another issue is cost effectiveness of both types of breast reconstruction. Most studies found that direct-to-implant is more cost effective than tissue expander breast reconstruction.²² Anatomically shaped expander and implant together can be over one and a half times the cost of a single implant.²² Moreover, a large American study analysing more than 1.300 immediate implant-based breast reconstruction, over first 18 months concluded, that the overall cost – including all the return visits and complications – was lower for single-stage direct-to-implant in comparison to two-stage tissue expander breast reconstruction, but statistical insignificantly.²³ In our practice, the cost of single-stage direct-to-implant breast reconstruction is around 4.000 € and that of two-stage tissue expander around 7.000 €. We also have to take into consideration, that the

Table 2: Advantages and disadvantage of immediate two-stage tissue expander and single-stage direct-to-implant breast reconstruction.^{1,7,8,21,32}

Immediate single-stage direct-to-implant breast reconstruction	Immediate two-stage tissue expander breast reconstruction
Advantages	
<ul style="list-style-type: none"> • decreased total number of operations • less exposure to anaesthesia • reduced number of outpatient clinic visits • reduced time to complete reconstruction • improved psychological well-being • reduction in long term morbidity • optimal for small to moderate sized breast with little ptosis • lower overall cost 	<ul style="list-style-type: none"> • predictable results with minor corrections possible • improved IMF positioning • decreased probability of skin flap necrosis • optimal for large, ptotic breasts
Disadvantages	
<ul style="list-style-type: none"> • increased short-term reconstruction-related complications (implant loss, wound disruption) • higher probability of mastectomy skin flap necrosis (partial or total) • unpredictable end result • healthy and adequate skin envelope needed • difficult prediction of implant volume • pre-existing scars can compromise skin perfusion • suboptimal for large, ptotic breasts or those who want significantly larger breast 	<ul style="list-style-type: none"> • multiple operations needed • longer time to complete final reconstruction • pain after expansion • possibility of rib fracture due to expansion • significant capsular adjustment required at the time of expander replacement • higher overall cost

overall price very much depend on the type of material used (e.g. titanium mesh) and its quality. Despite current higher prices of titanium-coated meshes, single-stage operation is comparable or cheaper than two-stage breast reconstruction.

Conclusion

These two case reports showed two different types of breast reconstruction after therapeutic and prophylactic mastectomy, with latter showing a rising trend. Two-stage tissue expander breast reconstruction is still a gold standard, with the main disadvantages

of multiple operations and longer overall time to complete reconstruction; while single-stage direct-to-implant breast reconstruction is a new and rapidly emerging technique, with only single operation to complete reconstruction. Both techniques have low medium-term complication rates, which are comparable and show no statistical difference. Multidisciplinary team of breast cancer surgeons and plastic surgeons should carefully explain to the patient all the advantages and disadvantages of both types. Final decision to undergo two-stage or single-stage breast reconstruction should always be patient-centred.

References

1. Davila AA, Mioton LM, Chow G, Wang E, Merkow RP, Bilimoria KY, et al. Immediate two-stage tissue expander breast reconstruction compared with one-stage permanent implant breast reconstruction: a multi-institutional comparison of short-term complications. *J Plast Surg Hand Surg* 2013; 47: 344–9.
2. Chen Sining, Giovanni P. Meta-analysis of BRCA 1 and BRCA 2 Penetrance. *J Clin Oncol* 2007; 25: 1329–33.
3. Rebbeck TR, Friebel T, Lynch HT, Neuhausen SL, van 't Veer L, Garber JE, et al. Bilateral Prophylactic Mastectomy Reduces Breast Cancer Risk in BRCA1 and BRCA2 Mutation Carriers: The PROSE Study Group. *J Clin Oncol* 2004; 22: 1055–62.
4. Warren Peled A, Foster RD, Stover AC, Itakura K, Ewing CA, Alvarado M, et al. Outcomes after total skin-sparing mastectomy and immediate reconstruction in 657 breasts. *Ann Surg Oncol* 2012; 19: 3402–9.
5. Neuburger J, MacNeill F, Jeevan R, van der Meulen JHP, Cromwell DA. Trends in the use of bilateral mastectomy in England from 2002 to 2011: retrospective analysis of hospital episode statistics. *BMJ Open* 2013; 3: 1–7.
6. Salzberg CA. Focus on technique: one-stage implant-based breast reconstruction. *Plast Reconstr Surg* 2012; suppl 130: 95–103.
7. Colwell AS. Direct-to-implant breast reconstruction. *Gland Surgery* 2012; 1: 139–41.
8. Gdalevitch P, Ho A, Genoway K, Alvrtsyan H, Bovill E, Lennox P, et al. Direct-to-implant single-stage immediate breast reconstruction with acellular dermal matrix: predictors of failure. *Plast Reconstr Surg* 2014; 133: 738–47.
9. Dieterich M, Paepke S, Zwiefel K, Dieterich H, Blohmer J, Faridi A, et al. Implant-based breast reconstruction using a titanium-coated polypropylene mesh (TiLOOP Bra): a multicenter study of 231 cases. *Plast Reconstr Surg* 2013; 132: 8–19.
10. Salzberg CA, Ashikari AY, Koch RM, Chabner-Thompson E. An 8-year experience of direct-to-implant immediate breast reconstruction using human acellular dermal matrix (AlloDerm). *Plast Reconstr Surg* 2011; 127: 514–24.
11. Ahcan U, Zivec K. Rib fracture after breast reconstruction with tissue expander. *Zdrav Vestn* 2009; 78: 413–6.
12. ASPS Annual report. 2013. Dosegljivo 21.10.2014 s spletnih strani: <http://www.plasticsurgery.org/Documents/news-resources/statistics/2013-statistics/plastic-surgery-statistics-full-report-2013.pdf>.
13. Colwell AS, Tessler O, Lin AM, Liao E, Winoograd J, Cetrulo CL, et al. Breast reconstruction following nipple-sparing mastectomy: predictors of complications, reconstruction outcomes, and 5-year trends. *Plast Reconstr Surg* 2014; 133: 496–506.
14. Cassileth L, Kohanzadeh S, Amersi F. One-stage immediate breast reconstruction with implants: a new option for immediate reconstruction. *Ann Plast Surg* 2012; 69: 134–8.
15. Dent BL, Small K, Swistel A, Talmor M. Nipple-areolar complex ischemia after nipple-sparing mastectomy with immediate implant-based reconstruction: risk factors and the success of conservative treatment. *Aesthetic Plast Surg* 2014; 34: 560–70.
16. Roostaeian J, Sanchez I, Vardanian A, Herrera F, Galanis C, Da Lio A, et al. Comparison of immediate implant placement versus the staged tissue expander technique in breast reconstruction. *Plast reconstr surg* 2012; 129: 909–18.
17. Wink JD, Fischer JP, Nelson JA, Serletti JM, Wu LC. Direct-to-implant breast reconstruction: An analysis of 1612 cases from the ACS-NSQIP surgical outcomes database. *J Plast Surg Hand Surg* 2014; 27.
18. Tokin C, Weiss A, Wang-Rodriguez J, Blair SL. Oncologic safety of skin-sparing and nipple-sparing mastectomy: a discussion and review of the literature. *Int J Surg Oncol* 2012; 2012: 1–8.
19. Algaithy ZK, Petit JY, Lohsiriwat V, Maisonneuve P, Rey PC, Baros N, et al. Nipple sparing mastectomy: can we predict the factors predisposing to necrosis? *Eur J Surg Oncol* 2012; 38: 125–9.

20. Gurtner G, Jones G, Neligan P, Newman M, Phillips B, Sacks J, et al. Intraoperative laser angiography using the SPY system: review of the literature and recommendations for use. *Ann Surg Innov Res* 2013; 7: 1.
21. Rao R, Saint-Cyr M, Ma A, Bowling M, Hatef D, Andrews V, et al. Prediction of post-operative necrosis after mastectomy: A pilot study utilizing optical diffusion imaging spectroscopy. *World J Surg Oncol* 2009; 7: 91.
22. Bonomi SMD, Settembrini FMD. Comparison of Immediate Implant-Based versus Staged Tissue Expander Breast Reconstruction Technique. *Plast Recons Surg* 2013; 131: 438–40.
23. Singh NK, Reaven NL, Funk SE. Cost comparison of immediate one-stage and tissue-expander breast reconstructions after mastectomy in commercially insured patients. *Managed care* 2013; 22: 36–43.