

# Gastric emptying in rats with gastroduodenal disease induced by N-methyl-N-nitro-N-nitrosoguanidine and alcohol

Dražigost Pokorn<sup>1</sup> and Anton Cerar<sup>2</sup>

<sup>1</sup> Institute of Hygiene,

<sup>2</sup> Institute of Pathology, Medical Faculty, University of Ljubljana, Slovenia

*The rate of gastric emptying was measured with a dye dilution technique in rats treated with N-methyl-N-nitro-N-nitrosoguanidine and alcohol.*

*Gastric emptying was compared in rats with gastroduodenal inflammatory diseases and gastroduodenal neoplasms, and in those without gastroduodenal disease.*

*Gastric emptying was found to be significantly increased following the intragastric injection of liquid meal in rats with gastroduodenal diseases as opposed to the control group of healthy rats.*

*These findings suggest that an increased gastric emptying of liquids can be explained by abolition on the relaxation of the gastric wall in rats with gastroduodenal diseases.*

**Key words:** gastric emptying; dye dilution technique; stomach diseases-chemically induced; N-methyl-N-nitrosoguanidine

## Introduction

There is an increasing tendency to incriminate abnormalities in gastric emptying in the pathogenesis of gastroduodenal disease. Many disorders are associated with delayed gastric emptying without evidence of a structural gastric outlet obstruction.<sup>1-4</sup> Nevertheless, Nomiya<sup>5</sup> found, by use of the acetaminophen absorption method, that gastric emptying in patients with early gastric cancer was rather rapid, if compared with emptying in healthy subjects. These differences may be caused by differences in the methods of the gastric emptying measurement and in the test meal used.<sup>3,6</sup>

We supposed that liquids injected directly into the stomach by a sonde, would be emptied from a stomach with gastroduodenal disease more quickly than from a healthy stomach.<sup>7</sup>

We tested this hypothesis using the dye dilution test for gastric emptying<sup>8,9</sup> after treating Wistar rats with N-methyl-N-nitro-N-nitrosoguanidine (MNNG)<sup>10,11</sup> and alcohol.

## Materials and methods

### Animals

We used 70 male Wistar rats weighing 150–200 g. The animals were fed pelleted Knapka food, and maintained in macrolon cages at a constant temperature (22±2 °C) and relative humidity (60±5 %). All the animals were given MNNG (Fluka Chemie, Switzerland) at a concentration of 100 mg/litre<sup>10</sup> in a drinking solution. We arbitrarily divided the experimental animals into two groups. One group had MNNG diluted in tap water, while the other, in a 12 % alcohol solution. The control group of 10 animals drank tap water. The experimental animals drank MNNG solution for 29 weeks; after that they drank tap water for an additional 29 weeks, at which time the experiment concluded.

Correspondence to: Prof. Dražigost Pokorn, PhD, MD, Institute of Hygiene, Medical Faculty, University of Ljubljana, Zaloška 4, 1000 Ljubljana, Slovenia.

The experimental animals were observed daily and weighed once every 4 weeks. Autopsies were performed on all except two animals.

At the end of the 58 experimental weeks, the gastric emptying tests were performed.

### Gastric emptying studies

The technique of Mangel and Noegel<sup>8,9</sup> was used with modifications. Studies were performed on all rats with the exception of the rats which spontaneously died during the experiment.

During fasting the rats were maintained in wire-bottomed cages to avoid coprophagy. The experiments were performed in a room with the same environmental conditions (temperature, noise and humidity) as those in the breeding area. All experiments were done in the morning.

The phenol red meal was prepared as follows: methyl cellulose was dissolved in water at about 80 °C and prepared in a final concentration of 1.5 %. The solution was stirred until dissolved, and phenol red (50 mg/100 ml) was then added to the stirring solution.

Three ml of phenol red solution, maintained at 37 °C, was administered orally to the rats. The animals were then killed 10 minutes (healthy rats) or 20 minutes (healthy rats and rats with gastroduodenal diseases) after the ingestion of the phenol red meal by means of CO<sub>2</sub> inhalation.

An incision was made for a middle laparotomy. The stomach was exposed and occluded at the pylorus and cardia. The stomach was then removed, cut along the greater curvature and washed out with 3 ml of 0.9 % saline. The gastric content was placed in 100 ml of 0.1 N NaOH with 0.9 % saline.

Trichloroacetic acid (0.5 ml) (20 % t/vol) was added to 5 ml of the mixture. This sample was centrifuged at 2,500 rpm for 30 min. The supernatant was removed and 4 ml of 0.5 N NaOH added. Samples were then read on a colour spectrophotometer (MA 9502) at 560 nm.

The percentage of gastric remains was calculated as follows:

$$\% \text{ gastric remains} = \frac{\text{absorbtion value for stomach}}{\text{mean absorbtion value for test meal}} \times 100$$

Values were reported as means  $\pm$  SE.

Statistical analysis was made using the Student's t test with a significance level criteria of 0.05.

### Morphologic evaluation

The stomach and other visceral organs were examined macroscopically, fixed in a 10 % neutral formalin and routinely processed for histopathological studies. Gastroduodenal lesions were classified histopathologically into neoplastic (dysplasia, papilloma, squamous cell carcinoma, adenocarcinoma, sarcoma) and nonneoplastic (principally inflammatory) gastroduodenal diseases, following accepted histologic criteria.<sup>12</sup>

### Statistical evaluation

The significance of the percentage difference of the gastric content 20 minutes after the test-meal was evaluated by using the Student's t test.<sup>13</sup>

## Results

Body weight gains of rats in the different MNNG-treated groups are shown in Figure 1.

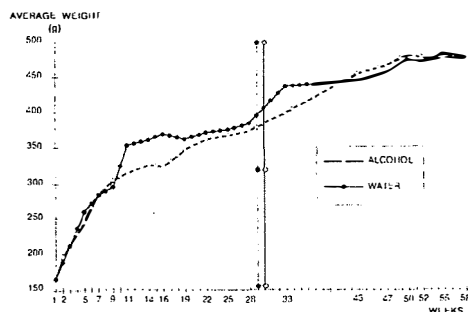


Figure 1. Weight gain in rats during different dietary periods.

One animal in the alcohol and two animals in the water group died from pneumonia and one animal in the alcohol group from an advanced gastric tumor. Autopsies were not done in two animals.

As shown in Table 1, tumors were found in 23 rats (from a total of 60 rats). The incidence of gastroduodenal carcinoma was greater in the experimental group drinking the tap water with MNNG, in contrast to the group drinking alcohol with MNNG.

The data on gastric emptying in rats with gastroduodenal diseases and those in healthy rats are summarised in Figure 2.

The gastric emptying in rats with gastroduodenal lesions with or without gastric or duodenal tumors

**Table 1.** Effect of Various Test Meals on Gastroduodenal Neoplasia Induced by MNNG in Male Wistar Rats\*

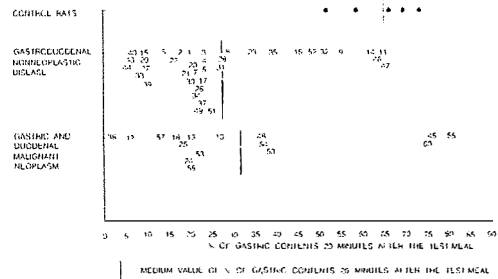
Gastroduodenal Lesions	Treatment (Test Meals)		
	Ethanol**	Water***	Total
Displasia	4	0	4
Papilloma	1	1	2
Carcinoma	5	11	16
Sarcoma	1	0	1
Total	11	12	23

\* Total No of rats were 60.

\*\* 12.0 vol % of ethanol in tap water with MNNG.

\*\*\* Tap water with MNNG.

was approximately equal. Figure 2 also shows that the gastric emptying was significantly slower in the



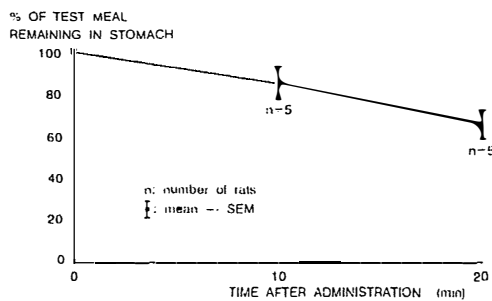
**Figure 2.** Distribution of the gastric content of the standard meal in the stomach of rats with and without gastroduodenal disease.

No	%	
1	20.2	Chronic superficial duodenitis.
2	18.2	Fibrosis of fundic mucosa. Chronic superficial duodenitis.
3	24.1	Chronic superficial duodenitis.
4	24.1	Chronic antral gastritis with focal fibrosis of mucosa and sub. mucosa.
5	22.9	Focal fibrosis of fundic and antral mucosa.
6	13.8	No pathological changes.
7	21.5	Chronic gastritis and focal fibrosis of antral mucosa.
		Focal dysplasia (grade II) of nonglandular (squamous) mucosa.
		Chronic superficial duodenitis.
8	29.6	Chronic superficial duodenitis and focal fibrosis of antral mucosa.
9	55.0	Focal regenerative atypia of duodenal mucosa (in the vicinity of fibrosis).
10	27.1	Focal chronic gastritis of antral mucosa. Early adenocarcinoma of liver.
11	64.4	Mild chronic gastritis of antral and fundic mucosa.
12	(-)	No autopsy report.
13	20.0	Focal fibrosis of fundic mucosa. Focal dysplasia and invasive squamous cell carcinoma of nonglandular mucosa.
14	61.8	Mild chronic duodenitis with focal fibrosis of propria.
15	10.3	Chronic duodenitis. Chronic gastritis and chronic erosion of antral mucosa.
16	44.9	Focal fibrosis of submucosa of antral mucosa region.
		Chronic duodenitis.
17	24.4	Chronic gastritis of antral mucosa.
18	16.9	Moderate dysplasia of squamous mucosa. Chronic antral gastritis with focal fibrosis of submucosa.
		Early adenocarcinoma of antral mucosa.
19	(-)	Advanced sarcoma.
20	21.0	Chronic gastritis of antral mucosa. Liver cystadenoma.
21	19.6	Chronic gastritis of antral mucosa.
22	16.1	Focal fibrosis of antral and duodenal mucosa.
23	34.7	Chronic gastritis of antral mucosa.
24	19.6	Chronic gastritis of antral mucosa with focal fibrosis.
		Squamous cell papilloma of nonglandular mucosa.
		Adenocarcinoma (infiltrates muscularis propria) of antral mucosa.
25	17.7	Moderate dysplasia of squamous mucosa. Early invasive cell carcinoma of nonglandular mucosa.
26	23.5	Mild dysplasia of squamous mucosa.
27	9.6	Chronic gastritis of antral mucosa with focal fibrosis.
28	27.8	Focal fibrosis of antral mucosa. Liver cystadenoma.
29	11.4	Focal fibrosis of antral mucosa.
30	20.2	Chronic gastritis of antral and fundic mucosa with focal fibrosis.
31	27.6	Chronic gastritis of antral mucosa with focal fibrosis.
		Liver hamartoma.
32	52.6	Chronic duodenitis.
33	10.2	Chronic gastritis of antral mucosa and erosion of fundic mucosa.
34	21.0	Chronic gastritis of antral mucosa with focal fibrosis of antral and duodenal mucosa.
35	38.8	Focal fibrosis of antral and fundic mucosa.
36	(-)	Advanced autolysis. No tumor.
37	22.9	Focal fibrosis of antral and fundic mucosa.
38	1.6	Chronic gastritis of antral mucosa. Moderate dysplasia of nonglandular mucosa.
		Early invasive squamous carcinoma.
39	10.9	Chronic gastritis of antral mucosa. Focal dysplasia of fundic mucosa.

No	%	
40	8.3	Chronic gastritis of antral mucosa. Chronic duodenitis.
41	(-)	Focal fibrosis of antral mucosa. Initial autolysis.
42	5.9	Chronic gastritis and focal fibrosis of antral mucosa. Chronic duodenitis. Advanced (Dukes B) adenocarcinoma of duodenum.
43	7.6	Chronic gastritis of antral mucosa. Papillary cystadenoma of liver.
44	6.5	Chronic gastritis of antral mucosa. Focal fibrosis of duodenal mucosa.
45	76.2	Adenocarcinoma of antral mucosa.
46	63.5	Focal fibrosis of antral mucosa. Gastritis cystica profunda of prepyloric region.
47	65.5	Focal fibrosis of antral and duodenal mucosa and antral submucosa.
48	36.6	Adenocarcinoma of antral mucosa (submucosal invasion).
49	22.4	Gastritis cystica profunda of antral mucosa. Cystadenoma of liver.
50	38.9	Chronic duodenitis. Adenocarcinoma of antral (prepyloric) mucosa (submucosal invasion).
51	25.0	Focal fibrosis of antral mucosa and submucosa and chronic erosion of antral mucosa.
52	48.3	Focal fibrosis of antral and fundic mucosa.
53	21.9	Focal fibrosis of antral mucosa. Adenocarcinoma of antral mucosa (submucosal invasion).
54	36.8	Chronic gastritis of antral mucosa. Advanced (Dukes B) adenocarcinoma of duodenum.
55	80.5	Chronic gastritis and focal fibrosis of antral mucosa. In nonglandular mucosa squamous papilloma and invasive squamous carcinoma (early). Advanced (Dukes B) adenocarcinoma of duodenum. Multiple papillary cystadenoma of liver.
56	(-)	No autopsy report.
57	12.7	Chronic gastritis of antral mucosa. Adenocarcinoma of antral mucosa (invasion of submucosa).
58	20.0	Adenocarcinoma of antral (prepyloric) mucosa (invasion of submucosa)
59	(-)	Chronic gastritis and focal fibrosis of antral mucosa.
60	75.0	Advanced (Dukes B) adenocarcinoma of distal duodenum.

healthy rats than in those with gastroduodenal lesions. ( $P < 0,01$ ).

The time duration for gastric emptying in the control (healthy) animals is illustrated in Figure 3.



**Figure 3.** Gastric emptying in rats without gastroduodenal disease.

**Discussion**

In the present work we found a significantly faster gastric emptying in rats with gastroduodenal diseases, in comparison with the control group of healthy rats.

We show that there is not a great difference in the rates of emptying between the rats having the gastroduodenal neoplastic and those with inflammatory disease. This finding confirms the previous work of

Nomiyama<sup>5</sup> who, using the acetaminophen absorption method, discovered that gastric emptying in patients with early gastric cancer was rather rapid, when compared with emptying in healthy subjects.

On the other hand, delayed gastric emptying has been demonstrated for a variety of infiltrative diseases.<sup>1, 4, 14-16</sup> This includes lymphomas, carcinoma, Whipple's disease, and diseases that produce granulomas in the gastric wall. In our study, all the animals with a prolonged gastric emptying with neoplasia had advanced carcinomas of the antrum and duodenum. On the other hand, the animals with shortened emptying generally had early gastric tumors.

Gastric mucosal abnormalities can affect gastric emptying. Diseases of the gastric musculature, including the inflammatory and endocrine myopathias, muscular dystrophies, and infiltrative disorders, can result in significant gastroparesis.<sup>1</sup> Most patients with gastroparesis have a delay in the emptying of solid food, but the rate of liquid emptying is preserved. This observation suggests that the factors that regulate the fundic tone are preserved longer in most patients with gastroparesis.<sup>17</sup> The proximal stomach has two remarkable motor properties that allow it to carefully regulate intragastric pressure during gastric filling, namely: receptive relaxation and accommodation.

The proximal stomach relaxes to receive the bolus of ingested food from the esophagus; hence the term receptive relaxation. Liquids entering the fun-

dus trigger vagally mediated initial receptive relaxation, so that the fundus plays a key role in the gastric emptying rate for liquids.<sup>18</sup>

The slight shortening of the time for gastric emptying could be accounted for as a result of the absence of the part of the receptive relaxation of the stomach when swallowing is eliminated.<sup>19</sup>

Accommodation to distension is a process whereby the stomach accepts increasing volumes without greatly increasing the intragastric pressure.

In the present work, an increased gastric emptying (especially the initial emptying) of liquids can also be explained by the abolition of the vagally mediated receptive relaxation, and/or of the change in the fundic tone as the intragastric injection of the liquid test meal occurs, that raises the intraluminal pressure, elevates the pressure gradient between the stomach and duodenum, and allows more liquids into the duodenum.<sup>20</sup>

This abnormally rapid gastric emptying, compared with the emptying in healthy rats, may be caused by differences in the gastric tonus.<sup>9</sup>

In healthy group, the proximal stomach accommodated easily to distension, keeping the intragastric pressure low as the stomach filled. On the contrary in the group with gastroduodenal disease, larger increases in pressure occurred during gastric distension. The gastroduodenal diseases impaired the stomachs' accommodation and led to greater increases in intragastric pressure with gastric filling. Moreover, the greater increases in pressure in those animals with gastroduodenal diseases led to the more rapid gastric emptying of liquids for most of the rats studied.

## References

- Chanduri TK, Fink S. Gastric emptying in human disease states. *Am J Gastroenterol* 1991; **86**: 533–8.
- Griffith GH, Owen GM, Inset AP, Campbell H, Smith R. Gastric emptying in health and in gastroduodenal disease. *Gastroenterology* 1968; **51**: 1–7.
- Tatsuta M, Liski H, Okuda S. Gastric emptying in patients with fundal gastritis and gastric cancer. *Gut* 1990; **31**: 767–9.
- Shih WJ, Domstated PA, Deland FH. Technetium – 99m triethelene tetramine polysterone resin gastric emptying studies in patients with various upper gastrointestinal diseases. *Clin Nucl Med* 1985; **10**: 494–7.
- Nomiyama T. Gastric emptying in gastric cancer. In: Tsuneoka K, Miwa T, Sekiguchi T, eds. *Gastroduodenal motor disorder*. Tokyo: Bunhodo, 1985: 178–81.
- Minami H, Mc Callum RW. The physiology and pathophysiology of gastric emptying in humans. *Gastroenterology* 1984; **86**: 1592–610.
- Azpiroz F, Maalagelada JR. Gastric tone measured by an electronic barostat in health and postsurgical gastroparesis. *Gastroenterology* 1987; **92**: 934–43.
- Scarpignato CT, Capovilla T, Bertaccini G. Action of caerulein on gastric emptying of the conscious rat. *Arch Int Pharmacodyn* 1980; **246**: 286–94.
- Mangel AW, Koefl A. Effect of peptides on gastric emptying. *Am J Physiol* 1984; **246**: (Gastrointest Liver Physiol 9): G342–G345.
- Takahashi M, Hasegawa R, Furukawa F, Toyoda K, Sato H, Hayashi Y. Effect of ethanol, potassium metabisulfite, formaldehyde and hydrogen peroxide on gastric carcinogenesis in rats after initiation with N-Methyl-N-Nitro-N-Nitrosoguanidine. *Jpn J Cancer Res (Gann)* 1986; **77**: 118–24.
- Watanabe H, Takahashi T, Okomoto T, Ogundigie PO, Ito A. Effect of Sodium Chloride and Ethanol on Stomach Tumorigenesis in ACl Rats Treated with N-Methyl-N-Nitro-N-Nitrosoguanidine; A Quantitative Morphometric Approach. *Jpn J Cancer Res* 1992; **83**: 588–93.
- Stinson SF, Schuller HM, Reznik G. *Atlas of tumor pathology of the Fischer rat*. Boca Raton, Florida: CRC Press, 1990.
- Petz B. *Osnove statističke metode*. Zagreb, 1970: 121–69.
- Meerof JC, Schreiber DS, Trier JS et al. Abnormal gastric motor function in viral gastroenteritis. *Ann Intern Med* 1980; **92**: 370–3.
- Meddenn JG, Horowitz M, Jamieson GG et al. Abnormalities of esophageal and gastric emptying in progressive systemic sclerosis. *Gastroenterology* 1984; **87**: 922–6.
- Reddy AB, Wright RA, Wheeler GE et al. Non-obstructive gastroparesis in amyloidosis improved with metoclopramide. *Arch Intern Med* 1983; **143**: 247–8.
- Reynolds JL. Prokinetic agents: A key in the future of gastroenterology. *Gastroenterol Clin North Am* 1989; **18**: 437–57.
- Mistiaen W, Van Hee R, Block P et al. Gastric emptying for solids in patients with duodenal ulcer before and after highly selective vagotomy. *Dig Dis Sci* 1990; **35**: 310–6.
- Hunt JN, Mac Donald I. The effect of intra-gastric instillation of meal on gastric function in man. *J Physiol* 1951; **113**: 185–8.
- Kelly KA. Gastric emptying of liquid and solids: roles of proximal and distal stomach. *Am J Physiol* 1989; **239**: (Gastrointest Liver Physiol 2): G71–G76.