

Epidemiology of Darier's Disease in Slovenia

A. Godic, J. Miljkovic, A. Kansky and G. Vidmar

ABSTRACT

Aim: To present a retrospective and prospective epidemiological and clinical study on Darier disease in Slovenia.

Results: Data on 77 DD patients was collected in the period 1973 to 2003 from the major dermatological departments and outpatient units in Slovenia. The prevalence of Darier disease in Slovenia is calculated at 3.8/100000 inhabitants. The ratio of affected/unaffected family members is 0.355. The comparison of two groups of DD patients (younger and older than 19 years) for the onset of the disease did not differ significantly although in two thirds of patients DD appeared for the first time before the age of 19 years.

Conclusion: The epidemiological and clinical data on Darier's disease in Slovenia conform to similar reports with the exception of the higher prevalence of the disease in Slovenia. UV radiation seems to be an important triggering factor and therefore it is reasonable to advise DD patients to avoid sun exposure.

KEY WORDS

Darier's disease, follicular dyskeratosis, epidemiology, Slovenia

Introduction

Darier's disease (dyskeratosis follicularis, DD) is an autosomal dominant skin disorder, caused by mutations of the *ATP2A2* gene which encodes the sarco/endoplasmic reticulum Ca^{2+} ATPase isoform 2 (SERCA2) (1). It is characterized by hyperkeratotic papules and plaques primarily in seborrheic areas, palmo-plantar pits, papules on the dorsum of the feet and hands, and broken papillary lines (Figure 1) (2). Hypopigmented macules may be seen in black-colored patients (3). Associated findings include whitish coats or papules of the oral mucous membrane, nail abnormalities with dis-

tal v-shaped notches, and various neuropsychiatric abnormalities, from learning difficulties to affective psychosis and schizophrenia (4,5). Salivatory stones and cysts of the long bones have been described infrequently in DD patients (6). Eight cases of subungual and scrotal squamous carcinomas, basal cell carcinomas, melanomas, esophageal carcinoma, and lung carcinoma have also been reported (7-12). Rare clinical variants of DD include vesicobullous (13), cornifying (14), comedo-like (15), acral (16,17), hemorrhagic (18), and lesions in segmental configuration of the disease (19). Histo-

Table 1. Onset of the disease. Two groups of patients (younger and older than 19 years) were compared with exact binomial test against the presumption that patients are equally distributed.

study	pat. aged up to	number (%)	sample	p
Godic et al.	19 years	18 (67)	28	0.122

logically, DD is characterized by suprabasal acantholysis in the epidermis and with dyskeratotic cells: corps ronds and grains (Figure 2). The onset of DD occurs in about 70 % of cases during the first two decades of life. The severity and course of the disease are unpredictable. The prevalence of the disease has been estimated between 1 per 100000 and 3.3 per 100000 inhabitants.

Patients and methods

DD occurs in both familial and isolated cases throughout Slovenia. Diagnosis is established through clinical examination and in the majority of patients confirmed by histopathology. On invitation we examined and interviewed 28 patients, 11 males and 17 females. The majority belonged to one of the 9 families, while 13 were isolated cases. Clinical manifestations were mild, moderate or severe, according to the criteria established by Sakuntabhai et al (23). We also recorded age at onset of the disease, educational level, exacerbating factors and concomitant diseases.

For statistical analyses, the StatXact-3 (Cytel Corp., 1997) software package was used. We compared two groups of patients (younger and older than 19 years) for the onset of the disease, calculated the ratio of affected patients/unaffected family members, and tested for the autosomal dominant mode of inheritance.

Results

Statistical calculations

The prevalence of DD in Slovenia is calculated at 3.8/100000 inhabitants. The ratio of affected patients/unaffected family members is 0.355. This ratio differs significantly from the expected 50 % (exact binomial test; $p < 0.00001$). The segregation ratio supported an autosomal dominant mode of inheritance ($p = 0.355$). The comparison of two groups of patients (younger and older than 19 years) for the onset of the disease did not differ significantly against the presumption that patients are equally distributed in the each of the compared groups (exact binomial test; $p = 0.122$) (Table 1).

Clinical assessment of DD patients

Altogether 77 DD patients were registered in Slovenia in the period from 1973 to 2003; 48 belonged to families with two or more affected family members, while 29 were isolated cases.

All examined 28 patients displayed typical keratotic papules, half of them also had hypertrophic plaques. There were no hemorrhagic symptoms nor a segmental distribution of lesions. Involvement of the skin was relatively mild in 12 patients (43 %), moderate in 9 (32 %), and severe in 7 (25 %). Nail abnormalities (white or red longitudinal bands in the nail plate and v-shaped notches at the free edge) were present in the majority of our patients (in 77 %), while only a minority of them (6 of 28) had white «cobblestone» papules of the oral mucosa. Heat, sweating and poor personal hygiene contributed to the exacerbation of the disease in the majority of them, whereas stress, occasional infections, surgical procedures or pregnancy had only a minor influence on the exacerbation of the disease; in 65 % of patients skin symptoms were exacerbated after exposure to UV.

Three patients were mentally retarded, two were reported to have periodic epileptic seizures, one had a history of affective psychosis in addition to an intracranial hemangioma and to an obstructive hydrocephalus, one had paresthesia of the upper extremities, and one had suffered a cerebrovascular accident. Impairment of memory and of the capacity to concentrate was noted in the majority of patients. An evaluation of educational level showed that 17 (61 %) had finished a primary or a vocational school (one of them finished an adapted primary school for the mentally retarded), five (18 %) had graduated from secondary school, and only two (7 %) had finished college or reached higher educational level. Four are still attending a school, one a primary school, one a secondary school, and two a college.

Three patients were reported to have primary hypertension (one with ocular damage), two patients had a history of perceptive deafness, one was affected by bilateral ocular cataract, one by intracranial hemangioma and an obstructive hydrocephalus, while one female patient had a history of infertility and of chronic renal failure.

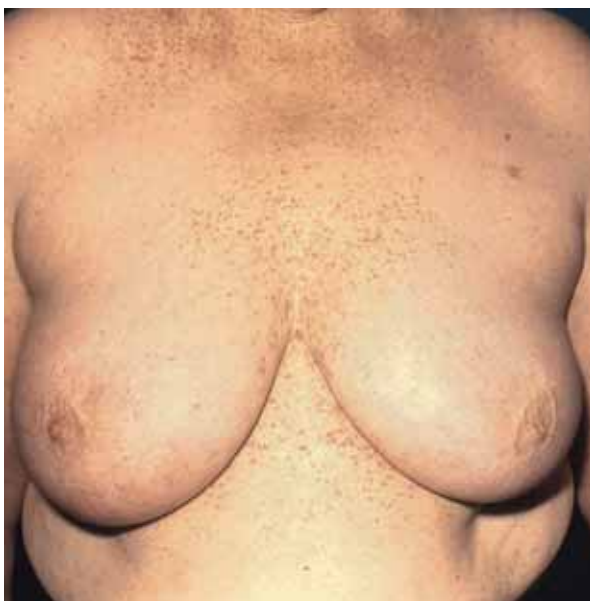

Figure 1. Darier's disease: hyperkeratotic papules in seborrheic area.

Discussion

It has been established that *ATP2A2* mutations cause Darier's disease by reducing calcium pump activity. To date, many attempts have been made to describe a phenotype-genotype correlation. The problem is not simple and can not be deduced from the clinical description of the disease and the accompanying *ATP2A2* mutation. One can only speculate on the potential impact of specific mutations on the function of SERCA2

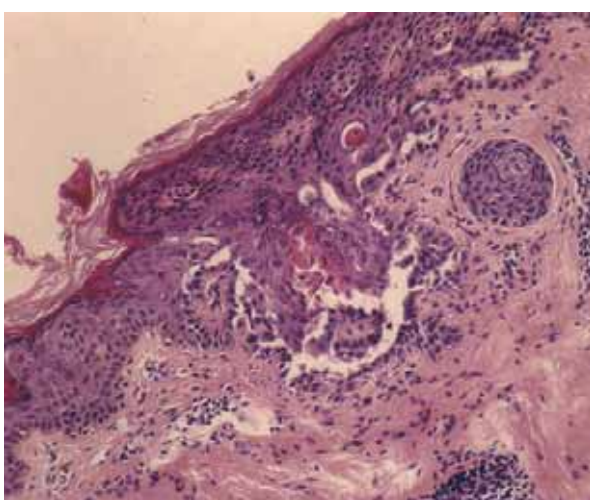


Figure 2. Darier's disease: suprabasal acantholysis of the epidermis with dyskeratotic cells, corps ronds and grains.

because the exact site-specific data on the mutation has, to date, remained obscure. An alteration in SERCA2 pump function by overexpression in Chinese hamster ovary cells (24) or by a partial deletion in mice (25) lead to adaptation of the Ca^{2+} signaling pathways and Ca^{2+} regulated cell functions. This is consistent with the nearly normal physiological response of platelet and heart function in DD-patients where SERCA is the major pump in the endo/sarcoplasmic reticulum (26). On the other hand, epidermal and neural cells are much more susceptible to reduction in SERCA2 activity, leading to moderate or severe skin and neuropsychiatric manifestations. From the high number of different *ATP2A2* mutations and the many isolated cases of DD patients we can deduce that mutations arise *de novo* and are family specific.

Sakuntabhai et al. previously suggested that mutations in *ATP2A2* produce a dominant DD phenotype through haploinsufficiency (1). This by itself does not explain the considerable interfamilial and intrafamilial phenotypic variability of the disease as observed in our investigation. The interaction of the wild type (WT) and mutant SERCA2 in vivo provides a mechanism to explain reduced Ca^{2+} pumping activity below the expected 50 % (27). Ahn et al. analyzed 12 DD-associated mutations of the *ATP2A2b* which encodes SERCA2b and is expressed predominantly in the skin, to study the underlying pathologic mechanism (27). Mutations were selected from all domains of the Ca^{2+} pump. Some of the mutants markedly affected pump activity because of reduced protein expression and/or enhanced proteasome-mediated degradation. However, no obvious correlation between phenotype-genotype was apparent. Ahn and his co-workers found that some mutants which reduced the activity of the native pump similarly inhibited the activity of the expressed WT SERCA2b, indicating that the inhibition is linked to these mutants (27). Co-immunoprecipitation experiments showed that SERCA2b exists as a dimer and the mutants, including those that are expressed at low levels, interact with the WT pump to reduce its activity (27). All potential mechanisms probably contribute to the variability of the clinical phenotype, but are not sufficient to account for all of the variability. It is also possible that some *ATP2A2* mutations could act through mechanisms distinct from haploinsufficiency (23). In particular, some missense or in-frame *ATP2A2* mutations may have residual or abnormal function (23). SERCA can interact with potential regulatory proteins while some mutations of *ATP2A2* might impair regulation of the SERCA2 function because of these molecules (22). Cytosolic Ca^{2+} oscillations may also influence the regulation of gene transcription (1,28,29).

Clinical experience also suggests an association between various neuropsychiatric disorders and DD (2,4,5). SERCA2b is highly expressed in the brain, especially in the Purkinje neurons of the cerebellum and

Table 2. Onset of the disease. Two groups of patients (younger and older than 19/20 years) were compared with exact binomial test against the presumption that patients are equally distributed.

reference	pat. aged up to	number (%)	sample	p
present study	19	18 (67)	28	0.122
32	19	15 (55)	28	0.851
20	19	34 (92)	37	< 0.001
2	20	119 (74)	161	< 0.001

the pyramidal cells of the hippocampus, while SERCA2a shows co-expression in the Purkinje cells, but is weakly expressed in other brain regions (30). Intracellular calcium signaling in neurons is involved in neuronal excitability, neurotransmission and synaptic plasticity (4). Cadherins, a family of calcium-dependent adhesion proteins, also play a central role in the formation of neuronal connections and may contribute to neurite outgrowth and pathfinding, and to synaptic specificity in the central nervous system (CNS) (31).

Jacobsen et al. reported that missense mutations in the 3' half of *ATP2A2* correlate with the presence of neuropsychiatric phenotypes, and more specifically that the ATP-binding domain may have relevance in mood disorders (5). In contrast, Ruiz-Perez et al. did not find any association between neuropsychiatric features and a specific class of mutation (4). These findings imply that any predisposition to neuropsychiatric disorder in DD is an inconsistent consequence of defective *ATP2A2* expression which is not mutation specific. Neurological deficiencies in DD patients could also be explained by the aberrant function of cadherins in cells of CNS, given that neuronal cells and keratinocytes are particularly sensitive to endoplasmatic reticulum Ca^{2+} content (27). The cause of cosegregation might also be genetic linkage between the DD gene and a susceptibility gene for bipolar disorder (5).

We calculated the prevalence of the disease in Slovenia to be 3.8/100000 inhabitants assuming that the Slovenian population amounts to roughly 2 million inhabitants. This incidence of DD is much higher than it is reported elsewhere. This is probably due to the well organized primary health system and dermatological service in Slovenia and also to a careful follow up of Slovenian DD families and patients.

There are still some questions which should be addressed concerning the role of UV irradiation in the late onset of the disease. It is interesting that the condition appears rarely in childhood and usually later, which contrasts with the observation in photodermatoses. The

comparison of two groups of patients in our study (younger and older than 19 years) for the onset of the disease did not differ significantly although in two thirds of patients DD appeared for the first time before 19 years of age (Tables 1 and 2). This may be explained by the relatively small sample of patients included in our study. Other similar studies showed a significant difference between the two groups, and some showed no difference whatsoever (Table 2).

It seems that UV radiation promotes the apoptosis of keratinocytes which is a longer-lasting process. It appears that it is at first well controlled by pro- and antiapoptotic molecules and is responsible for the relatively late onset in patients. Depletion of the endoplasmic reticulum (ER) Ca^{2+} stores generate the proapoptotic molecules caspase (33), and/or cause decrease in antiapoptotic proteins (Bcl-2 and Bcl-x) and imbalance of the protein Bax (34). Such imbalance results in inadequate protein processing and in an accumulation of unfolded proteins within the ER, leading to two highly conserved stress responses: the "unfolded protein response" (UPR) and/or the ER overload response (EOR) (35).

Conclusion

In conclusion, our epidemiological and clinical data on DD in Slovenia are in accordance with similar reports on DD, except for a higher prevalence in comparison with other countries. In addition to inheritance, UV radiation seems to be an important triggering factor and therefore it is reasonable to advise DD patients to avoid exposure to the sun in a similar way to other skin diseases where UV radiation plays an important role as a triggering factor. We believe that further epidemiological studies linked to the investigation of molecular-genetics would contribute to a better understanding of the mechanism responsible for the development of skin lesions in Darier disease.

REFERENCES

1. Sakuntabhai A, Ruiz-Perez V, Carter S, Jacobsen N, Burge S, et al. Mutations in *ATP2A2*, encoding a Ca^{2+} pump, cause Darier disease. *Nat Genet* 1999; 21: 271-7.

2. Burge S, Wilkinson DJ. Darier-White disease: a review of the clinical features in 163 patients. *J Am Acad Dermatol* 1992; 27: 40-50.
3. Berth-Jones J, Hutchinson PE. Darier's disease with perifollicular depigmentation. *Br J Dermatol* 1989; 120: 827-30.
4. Ruiz-Perez VL, Carter SA, Healy E, Todd C, Rees JL, et al. *ATP2A2* mutations in Darier's disease: variant cutaneous phenotypes are associated with missense mutations, but neuropsychiatric features are independent of mutation class. *Hum Mol Genet* 1999; 8: 1621-30.
5. Jacobsen NJO, Lynos I, Hoogendoorn B, Burge S, Kwok PY, et al. *ATP2A2* mutations in Darier's disease and their relationship to neuropsychiatric phenotypes. *Hum Mol Genet* 1999; 8: 1631-6.
6. Bale SJ, Toro JR. Genetic Basis of Darier-White Disease: Bad Pumps Cause Bumps. *J Cut Med Surg* 2000; 4: 103-6.
7. Downs AM, Ward KA, Peachey RD. Subungual squamous cell carcinoma in Darier's disease. *Clin Exp Dermatol* 1997; 22: 277-9.
8. Orihuela E, Tying SK, Pow-Sang M, Dozier S, Cirelli R, et al. Development of human papillomavirus type 16 associated squamous cell carcinoma of the scrotum in a patient with Darier's disease treated with systemic isotretinoin. *J Urol* 1995; 153: 1940-3.
9. Russo F, Perez-Bernal A, Camacho F. Darier's disease associated with basal cell carcinomas. *Dermatol Surg* 1995; 21: 167-9.
10. Narurkar VA, Liranzo MO, Bergfeld WF, Camisa C. Amelanotic malignant melanoma disguised by Darier's disease. *Dermatol Surg* 1996; 22: 479-80.
11. Mac Manus MP, Cavalleri G, Ball DL, Beasley M, Rotstein H, et al. Exacerbation, then clearance, of mutation-proven darier's disease of the skin after radiotherapy for bronchial carcinoma: a case of radiation-induced epidermal differentiation? *Radiat Res* 2001; 156: 724-30.
12. Shimizu H, Tan Kinoshita MT, Suzuki H. Darier's disease with esophageal carcinoma. *Eur J Dermatol* 2000; 10: 470-2.
13. Telfer NR, Burge SM, Ryan TJ. Vesico-bullous Darier's disease. *Br J Dermatol* 1990; 122: 831-4.
14. Katta R, Reed J, Wolf JE. Cornifying Darier's disease. *Int J Dermatol* 2000; 39: 844-5.
15. Hallermann C, Bertsch HP. Two sisters with familial dyskeratotic comedons. *Eur J Dermatol* 2004; 14: 214-5.
16. Romano C, Massai L, Alessandrini C, Miracco C, Fimiani M. A case of acral Darier's disease. *Dermatology* 1999; 199: 365-8.
17. Cianchini G, Colonna L, Camaioni D, Annessi G, Puddu P. Acral Darier's disease successfully treated with adapalene. *Acta Derm Venereol* 2001; 81: 57-8.
18. Foresman PL, Goldsmith LA, Ginn L, Beck AL. Hemorrhagic Darier's disease. *Arch Dermatol* 1993; 129: 511-2.
19. Happle R, Itin PH, Brun AM. Type 2 segmental Darier disease. *Eur J Dermatol* 1999; 9: 449-51.
20. Svendsen IB, Albrectsen B. The prevalence of dyskeratosis follicularis (Darier's disease) in Denmark: an investigation of the heredity in 22 families. *Acta Derm Venereol* 1959; 39: 256-69.
21. Miljković J, Kecelj N, Balkovec M, Penko M, Kansky A. Darier's Disease in Slovenia. *Acta Dermatoven APA* 2000; 9: 10-7.
22. Tavadia S, Mortimer E, Munro CS. Genetic epidemiology of Darier's disease: a population study in the west of Scotland. *Br J Dermatol* 2002; 146: 107-9.
23. Sakuntabhai A, Burge SM, Monk S, Hovnanian A. Spectrum of novel *ATP2A2* mutations in patients with Darier's disease. *Hum Mol Genet* 1999; 8: 1611-9.
24. Brini M, Bano D, Manni S, Rizzuto R, Carafoli E. Effects of PMCA and SERCA pump over expression on the kinetics of cell Ca^{2+} signaling. *EMBO J* 2000; 19: 4926-35.
25. Zhao XS, Shin DM, Liu LH, Shull GE, Muallem S. Plasticity and adaptation of Ca^{2+} signaling and Ca^{2+} -dependent exocytosis in *SERCA2 +/-* mice. *EMBO J* 2001; 20: 2680-9.

26. Tavadia S, Tait RC, McDonagh TA, Munro CS. Platelet and cardiac function in Darier disease. *Clin Exp Dermatol* 2001; 26: 696-9.
27. Ahn W, Lee MG, Kim KH, Muallem S. Multiple effects of SERCA2b mutations associated with Darier's disease. *J Biol Chem* 2003; 278: 20795-801.
28. Berridge MJ, Bootman MD, Lipp P. Calcium-a life and death signal. *Nature* 1998; 395: 645-8.
29. Dolmetsch RE, Xu K, Lewis RS. Calcium oscillations increase the efficiency and specificity of gene expression. *Nature* 1998; 392: 933-6.
30. Baba-Aissa F, Van den Bosch L, Wuytack F, Raeymaekers L, Casteels R. Regulation of the sarco/endoplasmic reticulum Ca^{2+} -ATPase (SERCA) 2 gene transcript in neuronal cells. *Brain Res Mol Brain Res* 1998; 55: 92-100.
31. Tepass U, Truong K, Godt D, Ikura M, Peifer M. Cadherins in embryonic and neuronal morphogenesis. *Nat Rev Mol Cell Biol* 2000; 1: 91-110.
32. Sokol J, Kansky A. Follicular dyskeratosis (Mb Darier) in Croatia. *Acta derm Iug* 1991; 18: 57-66.
33. Nakagawa T, Zhu H, Morishima N, et al. Caspase-12 mediates endoplasmic reticulum-specific apoptosis and cytotoxicity by amyloid-beta. *Nature* 2000; 403: 98-103.
34. Bongiorno MN, Arico M. The behaviour of Bcl-2, Bax and Bcl-x in Darier's disease. *Br J Dermatol* 2002; 147: 696-700.
35. Paschen W. Dependence of vital cell function on endoplasmic reticulum calcium levels: implications for the mechanisms underlying neuronal cell injury in different pathological states. *Cell Calcium* 2001; 29: 1-11.

**A U T H O R S '
A D D R E S S E S**

Jovan Miljkovic, MD, PhD, Department of Skin and Venereal Diseases, Maribor Teaching Hospital, Ljubljanska 5, SI-2000 Maribor, Slovenia, e-mail: miljkovic.j. @sb-mb.si

Aleksandar Godic, MD, PhD, Department of Dermatovenereology, University Medical Centre, Zaloška 2, SI-1525 Ljubljana, Slovenia, e-mail: aleksandar.godic @mf.uni-lj.si

Aleksej Kansky, MD, PhD, professor of dermatology, e-mail: aleksej.kansky@mf.uni-lj.si, same address

Gaj Vidmar, MSc, BA, Institute of Biomedical Informatics, Vrazov trg 2, SI-1104 Ljubljana, Slovenia, e-mail: gaj.vidmar @mf.uni-lj.si