

Secondary Small Intestinal Obstruction Associated With an Omental Adhesion After End-To-End Jejunio-Ileal Anastomosis in a Thoroughbred Horse: A Case Report

Key words

colic,
horse;
jejuno-ileal anastomosis;
omental adhesion;
small intestinal obstruction

Jungho Yoon^{1,2}, Ahram Kim¹, Jongyoung Park¹, Young Beom Kwak¹, In-Soo Choi², Taemook Park^{1*}

¹Equine Clinic, Jeju Stud Farm, Korea Racing Authority, Namjo-ro 1660, Jeju-si, Jeju, 63346, ²College of Veterinary Medicine, Konkuk University, Neungdong-ro 120, Gwangjin-gu, Seoul 05029, Korea

*Corresponding author: taemook@kra.co.kr

Abstract: A 19-month-old female thoroughbred horse presented with a history of acute abdominal pain. When the horse was four months of age, she underwent abdominal surgery and most of the strangulated jejunum and ileum were resected and anastomosed using an end-to-end technique. Subsequently, the horse was diagnosed with an ileal obstruction secondary to an adhesion of the greater omentum, which caused a mechanical obstruction of the lumen of the distal ileum. The ileum was released by transecting the adhesion and performing an omentectomy. After surgical intervention, the horse recovered quickly and was discharged fifteen days after surgery. This case report describes an ileal obstruction caused by an omental adhesion that formed after a jejunoileal anastomosis in a thoroughbred horse. The clinical, imaging, and surgical findings are described.

Received: 7 August 2023
Accepted: 7 February 2024

Introduction

Postoperative intra-abdominal adhesions (PIAs) are complications of abdominal surgery that challenge equine surgeons (1). Fibrinous and omental adhesions are consequences of peritoneal inflammation that may remain clinically silent or cause complications depending on the location and organization (1). Pathological adhesions causing postoperative abdominal pain and intestinal obstruction have been reported in 9% to 27% of horses, identified at postmortem examinations or during repeat laparotomy after abdominal surgery (2). Furthermore, strangulating lesions of the small intestine associated with the omental adhesions (OA) occur in 1% of horses undergoing exploratory laparotomy for abdominal pain (3). This report describes the clinical signs, diagnosis, surgical findings, treatment, and follow-up of small intestinal obstruction (SIO) caused by an OA after an end-to-end jejuno-ileal anastomosis in a horse.

Case Presentation

A 19-month-old female thoroughbred horse, weighing 430 kg presented with anorexia, signs of abdominal pain, and gastric reflux. The horse had undergone abdominal surgery at four months of age for a small intestinal volvulus involving most of the jejunum, and an end-to-end jejuno-ileal anastomosis was performed (Figure 1). The signs of abdominal pain developed the morning of presentation and had not responded to symptomatic treatment, including nonsteroidal anti-inflammatory medication (NSAID; flunixin meglumine, 1.1 mg/kg IV), fluid therapy (15 litres of Hartmann's solution IV), and gastric decompression through a nasogastric tube.

On a physical examination, the horse was quiet with a heart rate of 48 beats/min, respiratory rate of 15 breaths/min, and body temperature of 38.5 °C. The abdominal borborygmi was decreased at both sides and capillary refill time was delayed (>3 sec) along with congested mucous

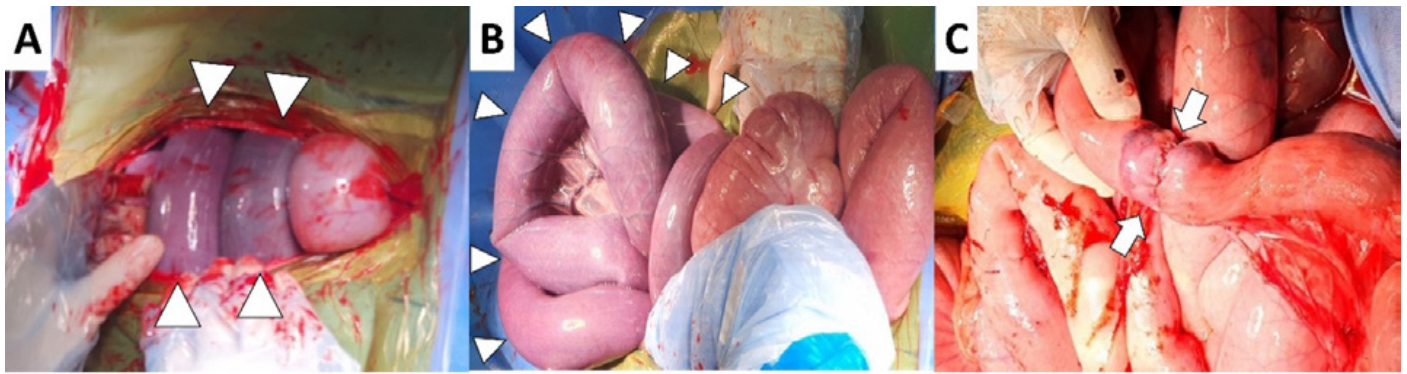

Figure 1: Detailed small intestine found on the first surgery at four-month of age. The strangulated small intestine was identified (A, B; arrowheads) and end-to-end jejunio-ileal anastomosis was performed (C; arrows)

membranes. A rectal examination was unremarkable. The hematology was within normal ranges. Serum biochemical analysis revealed elevated lactate (3.6 mmol/l, reference range, 1–1.5 mmol/l), hyperglycemia (156 mg/dl; reference range, 65–110 mg/dl), elevated creatinine kinase (2,003 U/l; reference range 120–470 U/l), decreased calcium (10.8 mg/dl, reference range; 11.5–14.2 mg/dl) and globulin (2.7 g/dl; reference range, 2.7–5.0 g/dl) levels. Abdominal ultrasonography revealed duodenal dilation (oval-shaped, 3.78 cm × 7.55 cm) with intraluminal fluid accumulation in almost the entire duodenal segment on the right side (Figure 2A).

An exploratory laparotomy was performed under general anesthesia. Antibiotic treatment included procaine penicillin G plus dihydrostreptomycin suspension (0.06 ml/kg IM, PPS injection, Daesung microbiological labs, Euiwang, Korea), gentamicin sulfate (6.6 mg/kg IV, Eagle gentamicin injection, Eaglevet, Seoul, Korea). NSAID was not given due to the administration prior to referral. The horse was premedicated with detomidine (0.02 mg/kg IV, Provet

Detomidine®, Provet, Istanbul, Turkey). General anesthesia was induced with diazepam (0.1 mg/kg IV, Samjin pharm, Seoul, Korea) and ketamine (2.2 mg/kg IV, Yuhan Ketamine, Yuhan, Seoul, Korea) and maintained with isoflurane (Ifran, Hana pharm, Hwaseong, Korea) in oxygen through a closed circle ventilation system after endotracheal intubation. After clipping and aseptic preparation, a ventral midline incision was made. The abdominal exploration revealed the small intestine to be fluid-distended, which was related to the ileal obstruction (Figure 2B). The lumen of a segment of distal ileum was narrowed by a circumferential adhesion of the greater omentum, which caused a mechanical obstruction (Figure 3A). The cecum and large colon distal to the ileum collapsed with few palpable contents (Figure 2B). The ileum was released through a transection of the adhesion and omentectomy using a blunt dissection and an ultrasonic surgical instrument (Medisonic DU-137, Daiwha, Wonju, Korea) (Figure 3B, 3C). After the adhesionolysis, the remaining small intestine was inspected grossly. The color of the small intestine improved, and good motility was

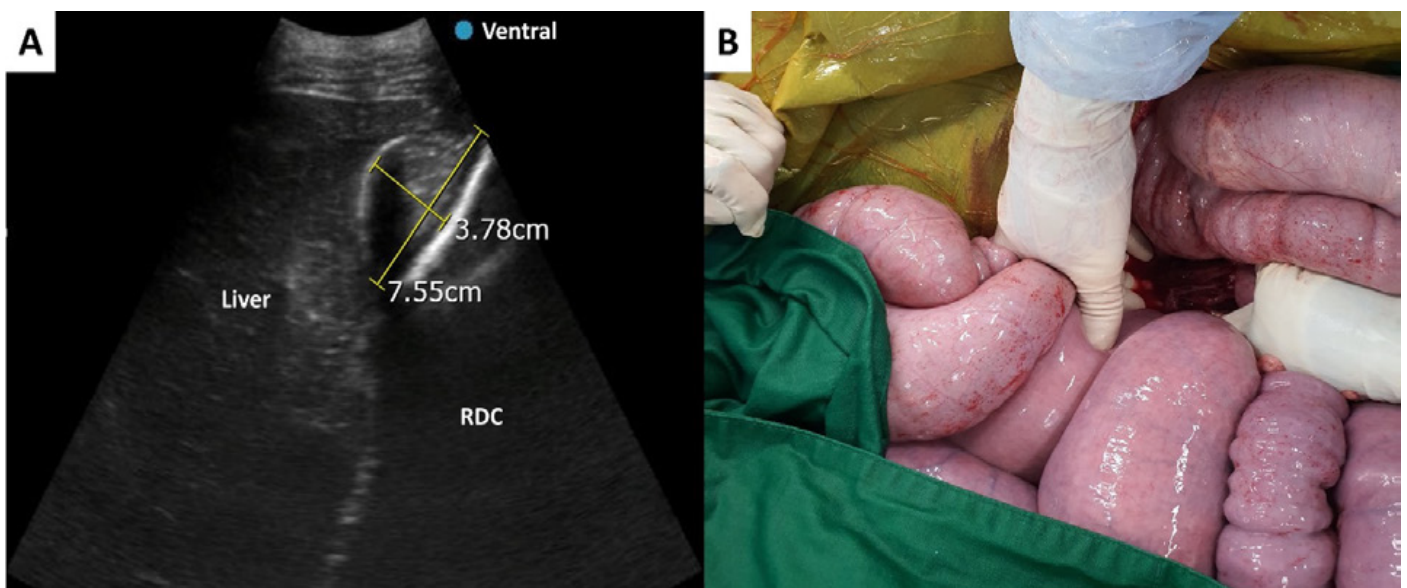


Figure 2: Ultrasonographic image (A) and gross appearance (B) of the distended small intestine in this study. (A) The duodenum was markedly dilated (oval-shaped, 3.78 cm × 7.55 cm) with an intraluminal fluid accumulation. The image was obtained from the right abdomen; RDC, and right dorsal colon. (B) The whole of the small intestine was grossly fluid distended which was related to the ileal obstruction

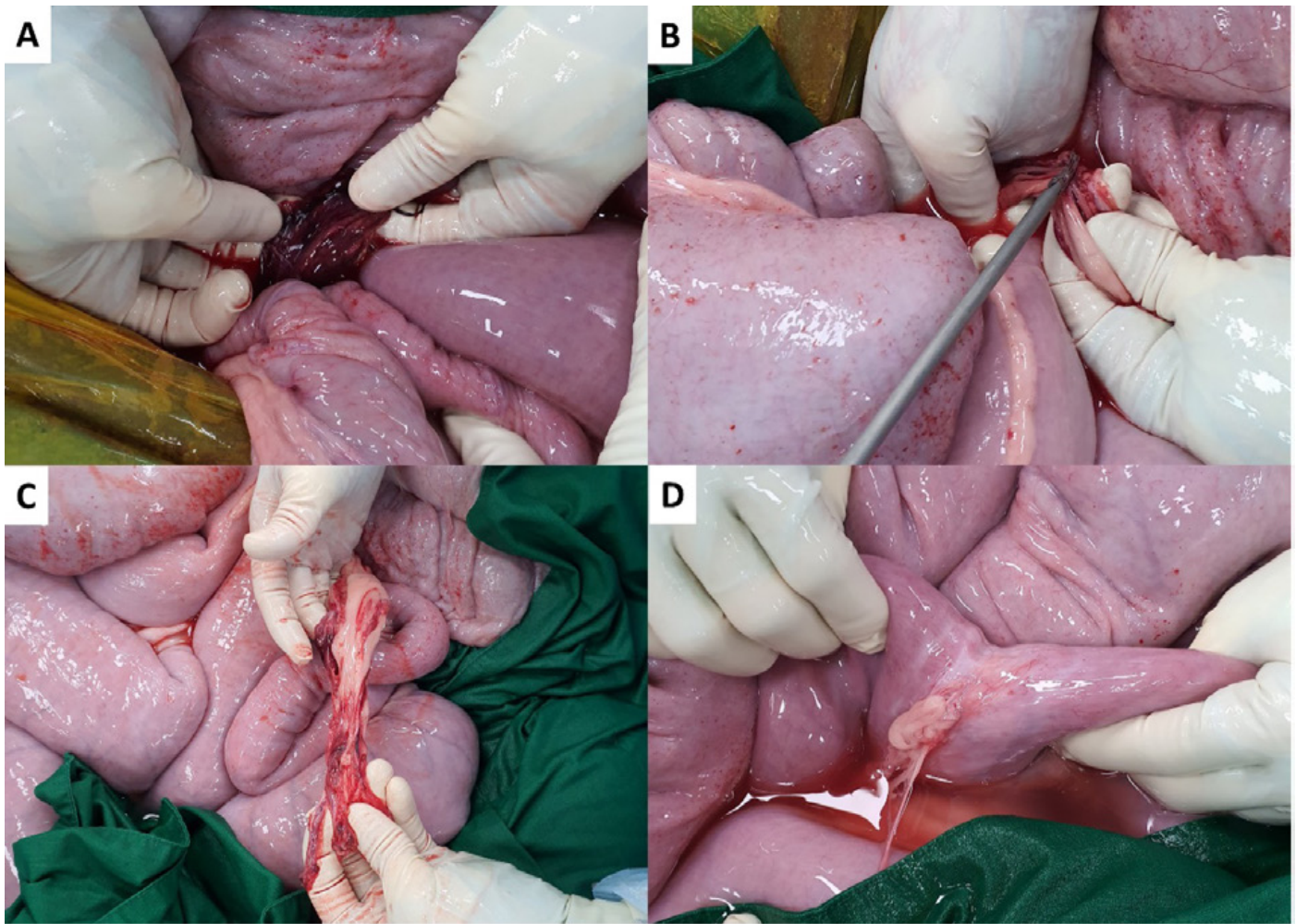


Figure 3: Identification of omental adhesion (A), adhesionolysis (B, C), and remnant secondary adhesion (D) in this study. (A) The distal ileum is encircled by the adhesion of the greater omentum. Both the mechanical obstruction and partial strangulation were caused by adhesion. (B) Omentectomy was performed using blunt dissection and an ultrasonic surgical instrument. (C) Resected omentum and relieved small intestines. The color and movement of the intestines gradually returned to normal. (D) Remnant adhesion at the anastomotic site of the previous surgery

observed throughout the intestine. The fluid distension was relieved by stripping the small intestinal contents into the cecum. Serosal scarring and adhesions were noted at the anastomotic site of the previous surgery (Figure 3D). Prior to closure, the abdominal cavity was lavaged with 15 L of heparinized saline (5,000IU/L). The linea alba, subcutaneous tissues, and skin were closed routinely.

Postoperatively, the horse recovered uneventfully from anesthesia. Postoperative medications included a continuous infusion of lidocaine (1.3 mg/kg IV as a bolus followed by a 0.05 mg/kg/min infusion) for the first 12 hours, flunixin meglumine (1.1 mg/kg IV once daily, Finadyne, MSD, France), procaine penicillin G (22,000 IU/kg IM once daily, PPS injection, Daesung microbiological labs, Euiwang, Korea), gentamicin sulfate (6.6 mg/kg IV once daily, Eagle gentamycin injection, Eaglevet, Seoul, Korea), famotidine (0.3 mg/kg IV twice daily, Gaster, Dong-A ST, Seoul, Korea), and omeprazole (4 mg/kg PO once daily, Abgard, Abler Pharmaceuticals, Houston, TX, USA) were administered for five days. Maintenance intravenous fluid of lactated Ringer's solution (60ml/kg/day) was infused for five

days. After confirming the absence of complications such as postoperative ileus, gastric reflux, dehydration, and diarrhea, the infusion was discontinued. The horse showed hypocalcemia and hyperkalemia pre- and postoperatively (Table 1). Calcium gluconate (0.1 ml/kg of the 45% solution) and 50% dextrose were added to the fluid to improve the electrolyte imbalances. Food was re-introduced 24 hours postoperatively. Initially, the horse was provided with 0.5 kg of fresh grass four times daily, with a steady increase in the volume of feedings. Grass hay (0.5 kg, four times daily) was added to the fresh grass 48 hours after surgery and increased gradually to the full ration over the next five day. An abdominal bandage was maintained for two weeks. Probiotics (*Lactobacillus* spp., *Enterococcus* spp., and *Saccharomyces boulardii*) were added to the feeding during hospitalization. Short periods of hand-walking and grazing were allowed two or three times daily.

Serial ultrasonography revealed no small intestinal dilation and normal intestinal motility. Serial hematology showed elevated serum amyloid A (SAA; 2,063 mg/l; reference range < 20 mg/l), creatinine kinase (CK, 4,892 U/l; reference range

Table 1: Postoperative blood examination results obtained while hospitalized. The factors important for a prognosis evaluation and out of the normal range were specified. Blood biochemical analyses were performed using the VS2 (Abaxis, USA) for CK, AST, TBIL, BUN, Creatinine, Calcium, and Potassium; the Accutrend Plus (Roche, Germany) for Lactate; and the Solo (EuroLyser, Austria) for SAA

	Reference range	Preoperation	Day 1	Day 2	Day 3	Day 4	Day 5	Day 7	Day 11
SAA (mg/l)	< 20	NA	2,063	1,912	1,502	1,112	NA	116.7	< 10
CK (U/l)	120–470	2,003	4,892	4,106	2,186	1,283	956	524	317
AST (U/l)	175–340	399	1,458	1,750	1,531	1,486	1,258	960	655
TBIL (mg/dl)	0.5–2.3	1.8	3.4	3.0	1.7	1.7	1.4	1.0	0.8
Lactate (mmol/l)	1–1.5	3.6	2.8	2.1	2.1	1.5	1.1	NA	NA
BUN (mg/dl)	7–25	23	15	11	12	13	14	12	14
Creatinine (mg/dl)	0.6–2.2	1.5	1.1	1.1	1.0	1.2	1.2	0.7	1.0
Calcium (mg/dl)	11.5–14.2	10.8	10.6	12.3	12.5	12.7	12.4	12.0	11.8
Potassium (mEq/L)	2.5–5.2	3.8	4.5	5.8	6.0	5.7	4.7	4.3	3.3

SAA, serum amyloid A; CK, creatinine kinase; AST, aspartate aminotransferase; TBIL, total bilirubin; BUN, blood urea nitrogen NA, not available

120–470 U/l), aspartate aminotransferase (AST, 1,750 U/l; reference range 175–340 U/l), and mild electrolyte imbalances (hypocalcemia and hyperkalemia) but the levels returned to the normal ranges with postoperative treatment within two weeks (Table 1). There was mild edema around the abdominal incision, but this resolved. During hospitalization, the horse showed no signs of abdominal pain and a good appetite. The staples were removed from the abdominal incision on day 15 after surgery and the horse was discharged. Follow-up at 1 year after surgery the horse remained healthy without any clinical signs of gastrointestinal disease.

Discussion

Postoperative intraabdominal adhesions are not an uncommon complication consequence of abdominal surgery (4, 5). Normally, the fibrinolytic capacity in the peritoneum exceeds the coagulation response so, abdominal adhesions do not occur under normal conditions (4). An imbalanced fibrinolytic system induced by specific causes, such as surgery and inflammation, damage to the mesothelial layer of the intestine, and reduced fibrinolytic activity, increases the risk of PIA (6). The earlier development of clinical adhesions is related to a poorer prognosis for survival (5). In equine medicine, adhesions are more often associated with surgical trauma rather than the site of the primary lesion, resection, or endotoxemia (7). Pathological adhesions causing postoperative abdominal pain and intestinal obstruction have been reported in 9% to 27% of horses (2), and small intestinal strangulating lesions associated with a greater omentum were present in 2.3% (32/1413) of horses

undergoing exploratory laparotomy for abdominal pain (3). The potential causes of SIO in horses include pedunculated lipoma, herniation, epiploic foramen entrapment, incarceration within a mesenteric or omental rent, gastrosplenic ligament entrapment, volvulus, and adhesions (5). In the present case, based on the physical examination and blood analysis, differential diagnoses were listed as small intestinal enteritis, impaction, obstruction, and strangulating intestinal lesions. The horse showed a sudden onset of gastric reflux and hyperlactatemia, associated with small intestinal ileus and poor tissue perfusion, respectively. Furthermore, ultrasonographic duodenal dilation, delayed CRT, color change of the mucous membranes, and hypocalcemia supported the differential diagnosis. Given the clinical findings, small intestinal strangulation and obstruction were considered as the likely cause, and OA-associated SIO was confirmed during surgery.

Statistically, significant associations between the PIA rate and the following factors were identified in previous studies: surgical techniques, perioperative medications, and protective tissue coating solutions (1). Among the surgical techniques available, omentectomy has been advocated to reduce PIA (1, 3). In the present case, an omentectomy was not performed at the first abdominal surgery. As shown in this study, the omentum may lead to OA-related SIO, and omentectomy may be effective in preventing OA lesions. Broad-spectrum antimicrobials, NSAID, prokinetic agent, and intraperitoneal heparin were administered peri- and postoperatively in this study to minimize peritoneal and serosal inflammation. In addition, protective tissue coating solutions, such as hyaluronic acid (HA) and carboxymethylcellulose (CMC), resorbable membranes, and postoperative

abdominal lavage could have been used to prevent postoperative adhesions (1).

Lidocaine was administered postoperatively (1.3 mg/kg IV as a bolus followed by a 0.05 mg/kg/min infusion) and was discontinued after confirming that the horse showed no signs of postoperative ileus, including gastric reflux on nasogastric intubation and abnormalities on abdominal ultrasonography. The horse showed no abdominal pain with normal intestinal borborygmi and good appetite toward to the hang hay nets outside the stall. Lidocaine is often used clinically as a constant rate infusion (CRI) for its potential analgesic, anti-inflammatory, and prokinetics properties (2). Although the prokinetic efficacy of lidocaine is still controversial (2, 8), there are evidence that lidocaine improves postoperative reflux, hospitalization duration, time to the first fecal passage, and survival rate (9-12). In a meta-analysis of the recent literature, the use of lidocaine in horses undergoing gastrointestinal surgery for the small intestinal disease was associated with an increased survival rate (8). In addition, surveys showed that most (79%) ECVS/ECEIM and 68% of ACVS/ACVIM, and ACVECC diplomates use lidocaine to treat postoperative ileus (13, 14).

On admission, the horse showed elevated serum CK and AST concentrations pre- and postoperatively (Table 1). Elevated CK and AST activities in horses with colic are frequently associated with muscle trauma caused by lying down, thrashing, rolling, and trailering to hospitals (15). Evidence of hepatic and metabolic changes associated with CK and AST in surgical colic patients has also been reported (16). The horse in this study showed a significantly higher CK value postoperatively (Table 1). This was possibly attributed to the decreased renal and intestinal blood flows, which were less than 50% of the awake value during deep anesthesia, causing significant CK and AST elevations on the day after anesthesia (17, 18).

In addition to the anti-inflammatory and prokinetic drug use, supportive care was conducted to enhance the postoperative prognosis. Maintenance intravenous fluid of lactated Ringer's solution was infused for five days. The horse showed hypocalcemia and hyperkalemia pre- and postoperatively (Table 1). Calcium gluconate and 50% dextrose were added to the fluid to improve electrolyte imbalances. The horse received probiotics (*Lactobacillus* spp., *Enterococcus* spp., and *Saccharomyces boulardii*) for normal microbial flora restoring and protective benefits of intestinal pathogenic bacteria. Gastric protectants, such as omeprazole and famotidine, were administered after surgery to prevent gastric ulcers. Hospitalized colic patients are frequently at increased risk of developing gastric ulcers associated with the administration of NSAID and treatment, stress, and feed deprivation (19). The highly effective treatment of gastric ulcers using omeprazole is well described (2, 19). The anti-ulcer medication was discontinued after restoring normal feeding and appetite with no gastric reflux. Although gastric protectants were used to prevent

postoperative gastric ulcers in this study, the potential risks associated with omeprazole administration, such as rebound gastric hyperacidity at the time of discontinuation, decreased calcium absorption during administration, and gastrointestinal toxicity related to the concurrent administration with NSAIDs, have been suggested (20).

Conclusions

This case report describes a secondary SIO associated with an OA after end-to-end jejuno-ileal anastomosis in a thoroughbred horse. The obstruction was surgically resolved by transecting the adhesion and performing an omentectomy. These findings highlight the importance of recognizing and addressing OA as a potential cause of SIO after intestinal surgery in horses, underscoring the importance of preventing postoperative adhesions and application of appropriate surgical techniques.

Acknowledgements

The authors thank all KRA staffs who participated in this study.

Conflict of Interest. The authors declare no conflicts of interest.

Author contributions. Conceptualization: J Yoon, and T Park; Data curation: J Yoon, A Kim, YB Kwak, and J Park; Formal analysis: J Yoon; Resources: A Kim, and J Park; Supervision: I-S Choi, and T Park; Validation: J Yoon, I-S Choi, and T Park; Visualization: J Yoon; Writing-original draft: J Yoon; Writing-review & editing: J Yoon, YB Kwak, and T Park.

References

1. Mueller PE. Advances in prevention and treatment of intra-abdominal adhesions in horses. *Clin Tech Equine Pract* 2002; 1: 163-73.
2. Fogle C. Postoperative care, complications, and reoperation of the colic patient. In: Aeur JA, eds. *Equine surgery*. 5th ed. Amsterdam: Elsevier, 2019: 660-77.
3. Storms N, Saliccia A, Grulke S, Barbazanges P, Detilleux J, de la Rebière G. Strangulating lesions of the small intestine associated with the greater omentum in horses: 32 cases. *Equine Vet Educ* 2021; 34: e451-60. doi: 10.1111/eve.13536
4. Vipond M, Whawell S, Dudley H, Thompson J. Peritoneal fibrinolytic activity and intra-abdominal adhesions. *Lancet* 1990; 335: 1120-2. doi: 10.1016/0140-6736(90)91125-T
5. Baxter GM, Broome TE, Moore JN. Abdominal adhesions after small intestinal surgery in the horse. *Vet Surg* 1989; 18: 409-14. doi: org/10.1111/j.1532-950X.1990.tb01115.x
6. Holmdahl L, Eriksson E, Al-Jabreen M, Risberg B. Fibrinolysis in human peritoneum during operation. *Surgery* 1996; 119: 701-5. doi: 10.1016/S0039-6060(96)80196-6

7. Gorvy DA, Edwards GB, Proudman CJ. Intra-abdominal adhesions in horses: a retrospective evaluation of repeat laparotomy in 99 horses with acute gastrointestinal disease. *Vet J* 2008; 175: 194–201. doi: 10.1016/j.tvjl.2007.02.016
8. Durke E, Gillen A, Kottwitz J, Munsterman A. Meta-analysis of the effects of lidocaine on postoperative reflux in the horse. *Vet Surg* 2020; 49: 44–52. doi: 10.1111/vsu.13286
9. Salem SE, Proudman CJ, Archer DC. Has intravenous lidocaine improved the outcome in horses following surgical management of small intestinal lesions in a UK hospital population? *BMC Vet Res* 2016; 12: 157. doi: 10.1186/s12917-016-0784-7
10. Torfs S, Delesalle C, Dewulf J, Devisscher L, Deprez P. Risk factors for equine postoperative ileus and effectiveness of prophylactic lidocaine. *J Vet Intern Med* 2009; 23: 606–11. doi: 10.1111/j.1939-1676.2009.0311.x
11. Milligan M, Beard W, Kukanich B, Sobering T, Waxman S. The effect of lidocaine on postoperative jejunal motility in normal horses. *Vet Surg* 2007; 36: 214–20. doi: 10.1111/j.1532-950X.2007.00255.x
12. Malone E, Ensink J, Turner T, et al. Intravenous continuous infusion of lidocaine for treatment of equine ileus. *Vet Surg* 2006; 35: 60–6. doi: 10.1111/j.1532-950X.2005.00113.x
13. Lefebvre D, Pirie R, Handel I, Tremaine W, Hudson N. Clinical features and management of equine post operative ileus: survey of diplomates of the European Colleges of Equine Internal Medicine (ECEIM) and Veterinary Surgeons (ECVS). *Equine Vet J* 2016; 48: 182–7. doi: 10.1111/evj.12355
14. Lefebvre D, Hudson N, Elce Y, et al. Clinical features and management of equine post operative ileus (POI): survey of diplomates of the American Colleges of Veterinary Internal Medicine (ACVIM), Veterinary Surgeons (ACVS) and Veterinary Emergency and Critical Care (ACVECC). *Equine Vet J* 2016; 48: 714–19. doi: 10.1111/evj.12520
15. Krueger CR, Ruple-Czerniak A, Hackett ES. Evaluation of plasma muscle enzyme activity as an indicator of lesion characteristics and prognosis in horses undergoing celiotomy for acute gastrointestinal pain. *BMC Vet Res* 2014; 10: suppl. 1: S7. doi: 10.1186/1746-6148-10-S1-S7
16. Underwood C, Southwood LL, Walton RM, Johnson AL. Hepatic and metabolic changes in surgical colic patients: a pilot study. *J Vet Emerg Crit Care* 2010; 20: 578–86. doi: 10.1111/j.1476-4431.2010.00597.x
17. Steffey EP, Mama KR, Galey FD, Puschner B, Woliner MJ. Effects of sevoflurane dose and mode of ventilation on cardiopulmonary function and blood biochemical variables in horses. *Am J Vet Res* 2005; 66: 606–14. doi: 10.2460/ajvr.2005.66.606
18. Manohar M, Gustafson R, Goetz T, Nganwa D. Systemic distribution of blood flow in ponies during 1.45%, 1.96%, and 2.39% end-tidal isoflurane-O₂ anesthesia. *Am J Vet Res* 1987; 48: 1504–10.
19. Rabuffo TS, Hackett ES, Grenager N, Boston R, Orsini JA. Prevalence of gastric ulcerations in horses with colic. *J Equine Vet Sci* 2009; 29: 540–6. doi: 10.1016/j.jevs.2009.05.005
20. Sykes B. A free ride: is long-term omeprazole therapy safe and effective? *Equine Vet Educ* 2021; 33: 556–60. doi: 10.1111/evj.13458

Primer sekundarna obstrukcije tankega črevesa, povezane z adhezijo omentuma po jejuno-ilealni anastomozi pri čistokrvnem konju

J. Yoon, A. Kim, J. Park, Y. B. Kwak, I.S. Choi, T. Park

Izvleček: 19 mesečna čistokrvna kobila je imela akutno abdominalno bolečino. Pri starosti 4 mesecev so ji med abdominalno operacijo odstranili večino zadržanega jejunuma in ileuma, ki so ju anastomozirali s tehniko konec s koncem. Pri kobili so nato diagnosticirali obstrukcijo ileuma kot posledico adhezije velikega omentuma, ki je vodila v mehansko zaporo lumna distalnega ileuma. Ileum je bil sproščen s prerezom adhezije in izvedbo omentektomije. Po kirurškem posegu je kobila hitro okrevala in bila po petnajstih dneh odpuščena iz veterinarske oskrbe. Ta klinični primer opisuje obstrukcijo ileuma zaradi adhezije omentuma po jejuno-ilealni anastomozi pri čistokrvni kobili. Opisani so klinični, slikovni in kirurški izvidi.

Ključne besede: kolika; konj; jejuno-ilealna anastomoza; adhezija omentuma; obstrukcija tankega črevesa