# CLASSIC AND AIDS-RELATED KAPOSI'S SARCOMA AN ULTRASTRUCTURAL INVESTIGATION

L. Celleno, A. Mastroianni, M. G. Borgia, F. Cottoni and D. Cerimele

## ABSTRACT

Electron microscopy was used to study lesional biopsy specimens from 25 patients with Kaposi's sarcoma (20 with the classical form and 5 associated with AIDS). The study revealed that the AIDS-associated lesions were characterized by more rapidly developing damage to the capillary endothelium with respect to the classical lesions; tubuloreticular structures were also found more often within the cells of the former lesions.

Our ultrastructural findings suggest that the endothelial cells of the affected blood vessels may be responsible for the histogenesis of the disease. In this study we were not able to demonstrate the presence of viral particles within the cells of the classical lesions. Virus-like particles were observed within the AIDS-associated lesions, but there was no sign of viral replication.

KEY WORDS

Kaposi's sarcoma, AIDS, ultrastructural findings

## INTRODUCTION

Kaposi's sarcoma is a multilesional, vascular neoplasm which generally evolves slowly. Three main types have been distinguished on the basis of clinical, epidemiological and evolutionary features: the classical or sporadic form, the endemic, and the epidemic form that is associated with the Acquired Immunodeficiency Sindrome (AIDS) (1, 2, 3, 4).

Histologically Kaposi's sarcoma is characterized by newly formed, angular or irregularly shaped vessels that often appear around the venules. In some cases the nuclei of the cells that make up these vessels are thin and spindle-shaped.

As the disease progresses these irregular vessels increase in number, and scattered spindle-shaped cells become visible (41). Extravasated erythrocytes can be observed among collagen bundles. In advanced Kaposi's sarcoma these spindle-shaped cells are organized into bundles. Extravasated erythrocytes can still be seen occasionally, while perivascular infiltrates containing lymphocytes and plasmacells are common (5).

The etiology and pathogenesis of Kaposi's sarcoma are still being debated in spite of numerous studies that have been carried out on the ultrastructure of this neoplasm (6-12, 14, 17, 18, 20).

Recent interest in this disease has stemmed from its association with AIDS, and the majority of ultrastructural studies conducted thus far have concentrated on this form (10-12), although some groups have attempted to compare the ultrastructural features of the epidemic and sporadic forms (13, 18, 19).

Ultrastructural findings indicate that this singular neoplasm is composed of two cell populations (7, 13, 14). Electron microscopy reveals, first, marked proliferation of capillaries with swollen endothelial linings that often occlude the lumens. These newly formed vessels do not seem to be associated with a continuous basal lamina or with pericytes (7, 15, 16).

A second population of spindle-shaped cells, still poorly defined from an ultrastructural point of view, then infiltrates the area surrounding these vessels.

Another typical finding, especially in the early phases of the disease, is that of an inflammatory infiltrate composed of lymphocytes and plasma cells. This aspect of the disease becomes less evident with time, according to some investigators (15, 19, 21), although others have found that the infiltrates persist especially in those cases that are associated with AIDS (23).

Electron microscopy has demonstrated other features that are specific to Kaposi's sarcoma. Extravasated red blood cells, either single or in clumps, can be seen in the dermis.

Hyaline bodies, probably composed of erythrocytes, platelets and other substances derived from either blood (19, 24) or tissue (fibrinogen, factor VIII, A1At, CEA, AFP) are also found.

The above features have been observed in both sporadic and epidemic forms of Kaposi's sarcoma. Most authors (14, 18, 22) agree, in fact, that the two forms are identical from an ultrastructural point of view. Virus particles that morphologically resemble HTLV-III virus have been observed in the neoplastic cells of AIDS-related Kaposi's sarcoma and are considered by some (13) to be pathognomonic for this form of the disease. However, the importance of this finding is still open to debate.

Normal endothelial cells (25) are characterized by micropinocytotic vesicles, multivesicular bodies, Weibel-Palade corpuscles, gap and tight intercellular junctions and a continuous basal lamina (26, 27). These latter organelles, studied for the first time in 1964, are considered to be ultrastructural markers for endothelials cells. Certain investigators who have studied the functions of the Weibel-Palade corpuscles believe that they are involved in coagulation as storage areas for platelet factor III (28) or, as suggested more recently, for von Willebrand's factor VIII (29).

These characteristics are absent or modified in the endothelial cells of the newly formed vessels of Kaposi's sarcoma. The intercellular junctions are altered and in some cases broken, and there are few organelles within the cytoplasm.

The basal lamina appears fragmented and in some cases is absent (18).

In addition to these alterations, the endothelial cells of AIDS-related Kaposi's sarcoma contain tuboloreticular structures identical to those that were first described in the 1960's in human lymphoid cells (30). These structures have also been found in peripheral blood mononuclear cells from patients with various pathological conditions, including

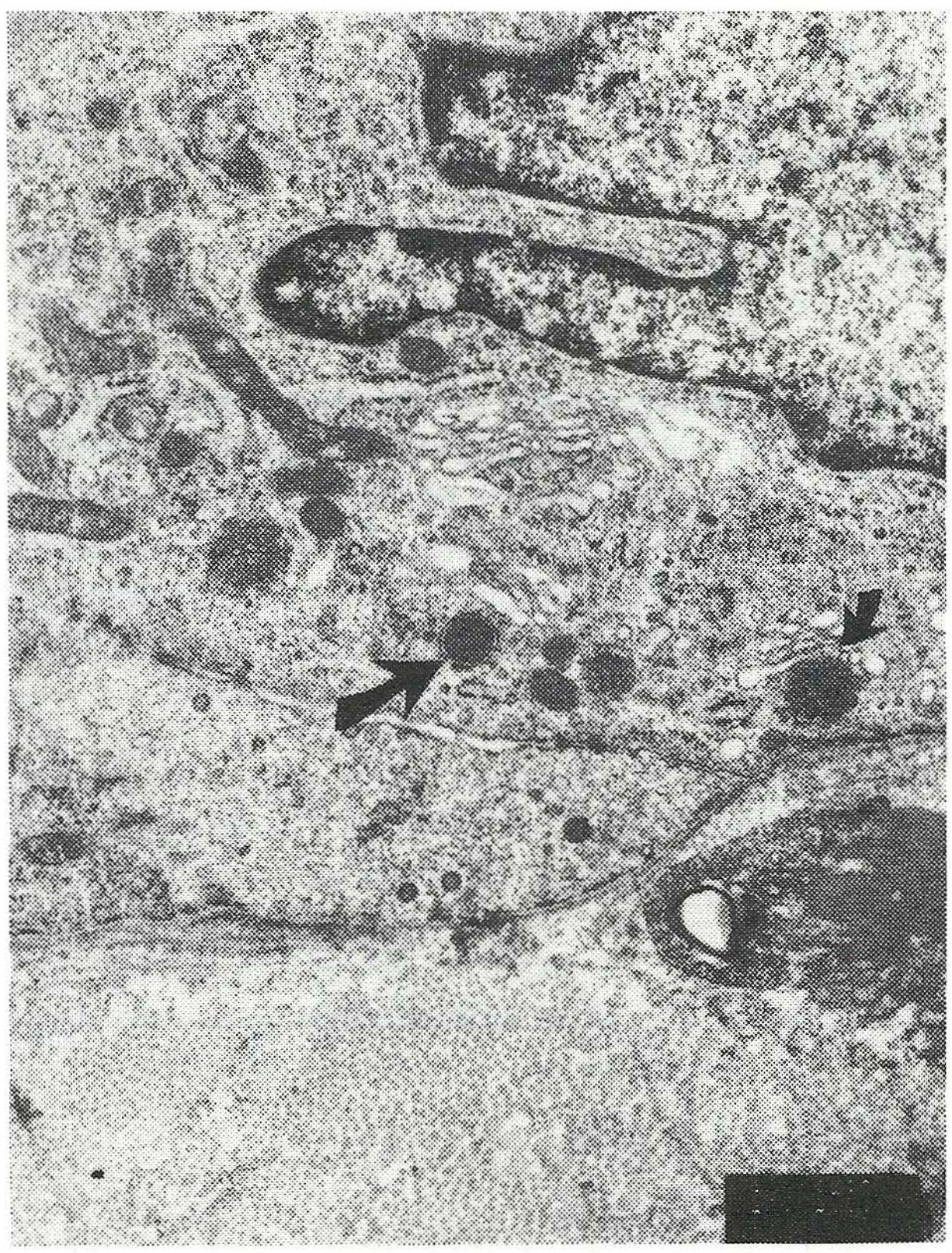

*Figure 1: Early lesion from classical Kaposi's sarcoma: Weibel-Palade bodies and MVB are well evident in the cytoplasm. The basal lamina membrane around the cells appears almost normal (Original magnification 4600x).*

autoimmune diseases, viral infections and neoplasms (31).

There is an important correlation between the abnormal serum levels of alpha-interferon and the presence of tuboloreticular structures in patients with lupus erythematosus (31). Abnormally high serum levels of alpha interferon, and according to some authors (32), beta interferon, as well, are found in almost all AIDS patients in which tubuloreticular structures appear in either lymphoid or endothelial cells.

There is thus basic agreement over the ultrastructural identity of the two forms of Kaposi's sarcoma, although some investigators place more value than others on the finding of HTLV-III like-virus particles in cells from the AIDS-related form of the disease (35).

## MATERIALS AND METHODS

We have recently used electron microscopy to examine the ultrastructural features of lesions from patients with the classical form of Kaposi's sarcoma and from others with AIDS-related disease.

The study was undertaken in an attempt to identify ultrastructural parameters of differentiation between the two forms as well as to learn more about the histogenesis of this singular neoplasm.

On the basis of clinical data as well as that of histological parameters described recently by Bisceglia et al. (41), we divided all available specimens into the the following three categories: early growth-phase, mature growth-phase and aggressive growth-phase.

A total of 25 biopsies of Kaposi's sarcoma were examined: twenty-three of these specimens came from male patients and the other two were from females.

Twenty of the cases were classical forms of the neoplasm; five were from patients with AIDS.

All samples were fixed in Karnovsky solution buffered to a pH of 7.2 with cacodyl sodium. They were then fixed in osmium tetraoxide, dehydrated and embedded in an acrylic resin according to the method of Spurr.

Ultrafine sections (thickness 45-65 nanometers) were then cut with an Ultracut E ultramicrotome (Reichert Jung), stained with uranyl acetate and lead citrate and examined with a Philips electron microscope.

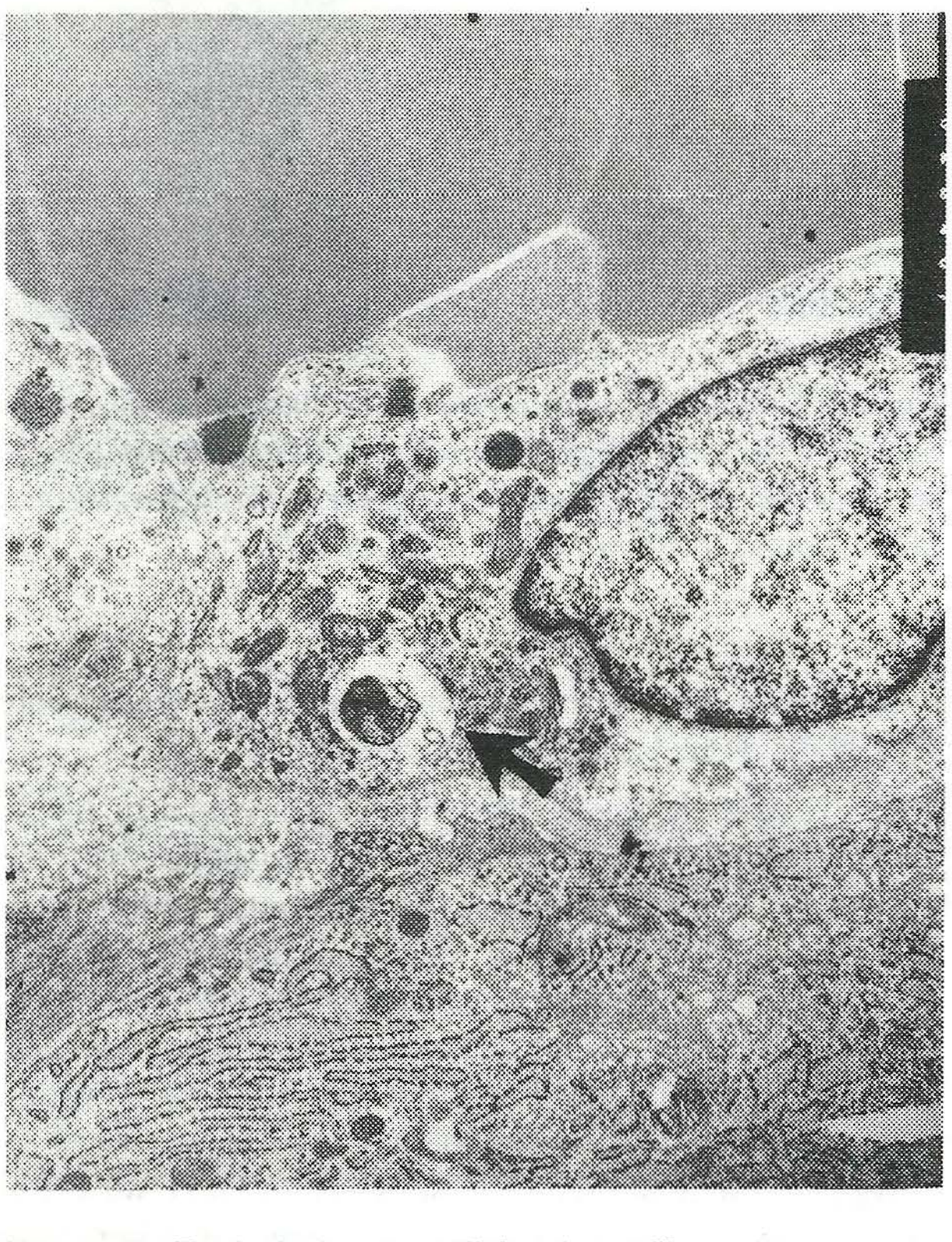

*Figure 2: Early lesion in AIDS-related Kaposi's sarcoma: involvement of endothelial cells is manifested by cytoplasmic necrotic phenomena. Around the vessel the pericyte shows an enlarged cytoplasm and well developed RER (Original magnification 6200x).*

## RESULTS

### EARLY GROWTH-PHASE LESIONS

**Classic Kaposi's sarcoma**: the principal alteration noted in the early lesions was that of the endothelial cells of the smaller capillaries. The volume of these cells was markedly increased. The cytoplasm protruded into the lumen of the vessels, and in many cases totally occluded them. Nuclear volume was also increased, and the nuclei themselves had a dentate appearance.

Weibel-Palade corpuscles were present near the few mitochondria.

The basal lamina of the involved capillary was normally present.

The pericytes normally found around capillaries were sometimes absent (Fig. 1).

Within the early lesions of sporadic Kaposi's sarcoma, normal capillaries which had not yet become involved in the sarcomatous process could also be observed.

**AIDS-related Kaposi's sarcoma**: the ultrastructural features of these specimens were, for the most part, similar to those of classic Kaposi's sarcoma. However, necrosis of the endothelium was more common in these specimens. Tubuloreticular structures appearing as a continuation of the rough endoplasmic reticulum were also consistently seen. Necrosis of the endothelium was occasionally accompanied by leakage of erythrocytes into the surrounding dermis.

The pericytes, were often absent or modified. The latter were enlarged and contained well-developed rough endoplasmic reticulum in their cytoplasm. Numerous reduplications of the basal lamina were noted (Fig. 2).

additional reduction in the number of pericytes, and their cytoplasmic processes were in contact with the basal membrane in only a few points around the capillaries.

*Figure 3: The microphotography shows the reduction of the intercellular junction and of the intracytoplasmic organelles (Original magnification 6200x).*

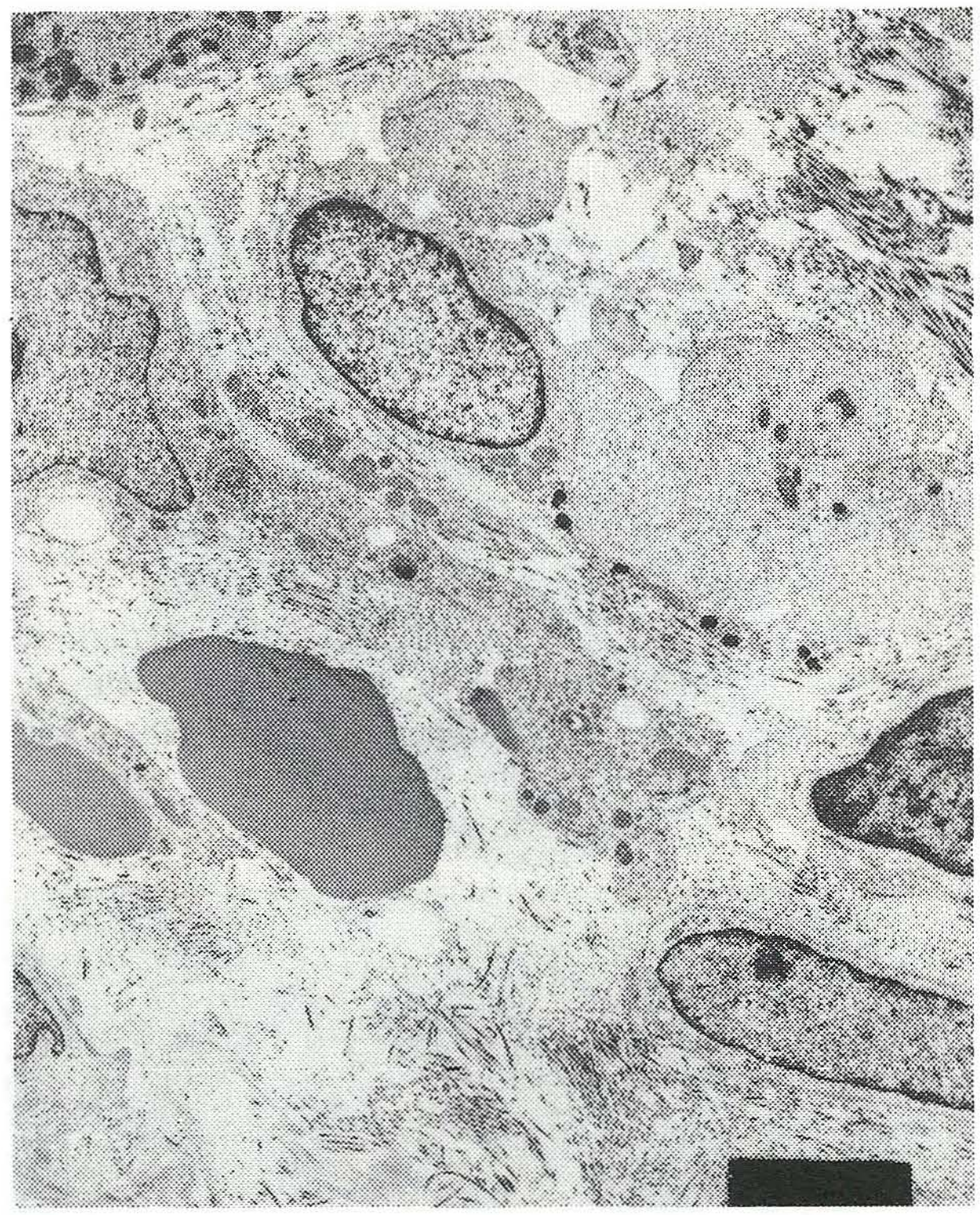

*Figure 4: Extravasated erythrocites and spindle-shaped cells with few intracytoplasmic organelles are shown in these pictures. The spindle-shaped cells present only a fragmented basal lamina (Original magnification 4600x).*

MATURE GROWTH-PHASE LESIONS

**Classical Kaposi's sarcoma:** Ultrastructural examination of the lesion at this stage revealed definitive breakdown of the vascular structure. The endothelial cells had a totally abnormal appearance. The cytoplasm contained very few organelles and was often involved in necrotic processes.

The Weibel-Palade corpuscles were still present. The nucleus had become oval in shape with finely dispersed chromatin. There were far fewer intercellular junctions, and erythrocyte diapedesis had increased. The flattened red cells could be seen among the swollen endothelial cells surrounding the almost virtual lumen of the capillary. Tubuloreticular inclusions could be found in only a few of these specimens (Fig. 3).

The basal membrane was clearly recognizable but appeared fragmented and in some cases doubled. There was an

Numerous erythrocytes undergoing phagocytosis were seen in the dermis around blood vessels.

**AIDS-related Kaposi's sarcoma:** The cytoplasm of the endothelial cells contained almost no organelles with the exception of a few cisternae of the rough endoplasmic reticulum and an occasional saccule in the vicinity of the Golgi complexes. Around the blood vessels, the basal lamina could be seen only occasionally, and there were very few pericytes. Numerous erythrocytes could be observed within the surrounding dermis (Fig. 4).

Aggregated tubuloreticular structures (TRS) were frequently found within the rough endoplasmic reticulum or as direct extensions of it. In other cases we observed "vermicellar bodies" in cytoplasm of the endothelial cells (Fig. 5). The latter structure is made up of intertwining filaments or rod-like elements.

Spindle-shaped cells were present around the altered vessels. The oval nuclei of these cells were in central or polar positions, and there were very few organelles in the cytoplasm.

*Figure 5: In the cytoplasm of the endothelial cells intertwining filaments are found in the AIDS-related Kaposi's sarcoma (Original magnification 13000x).*
*The insert shows as these structures are made by interconnecting filaments or rod-like elements (Original magnification 36000x).*

Weibel-Palade corpuscles were absent. In some cases, the spindle-shaped cells were loosely attached to one another forming one or two layer strips. The strips sometimes seemed to enclose small, vascularlike spaces that were optically empty (Fig. 6).

## AGGRESSIVE GROWTH-PHASE LESIONS

**Classic Kaposi's sarcoma:** The predominant feature of the specimens from older lesions was the presence of numerous spindle-shaped cells that were difficult to characterize from an ultrastructural point of view (Fig. 7). These cells had oval nuclei with chromatin dispersed in fine strands or, in some cases, clumped in the nuclear periphery. The cytoplasm contained few organelles and mitochondria. There were no multivesicular bodies or Weibel-Palade corpuscles.

In some specimens (Fig. 8), individual cells were scattered

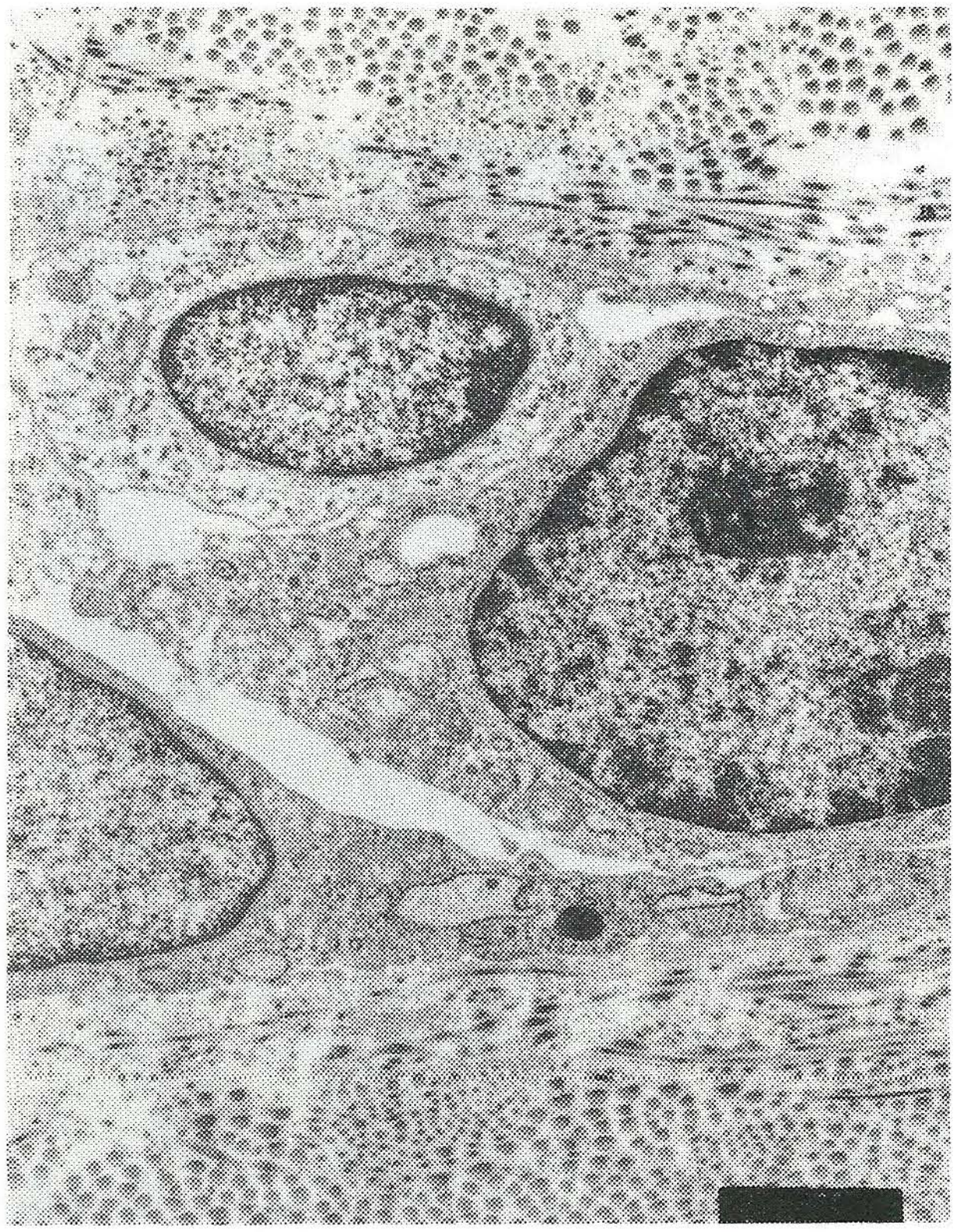

*Figure 6: Endothelial cells are joined to form a vascular-like structure with almost no lumen bounded by a basal membrane (Original magnification 8000x).*

throughout the dermis, whereas in others, they were arranged in rows. In other areas two such rows seemed to surround optically empty, vascular-like spaces. Throughout the field extravasated red cells being digested by phagocytes could be observed. Intact capillaries were present in the midst of those that presented the alterations previously described in more recent lesions.

**AIDS-related Kaposi's sarcoma:** In these lesions the great majority of the capillaries examined showed profound alterations. In some cases, spindle-shaped cells were seen loosely joined together and scattered throughout the tissue. Numerous extravasated erythrocytes could be seen among these cells (Fig. 9).

Histiocytes and fibroblast-like cells showed phagocytosis of the red blood cells (Fig. 10). The spindle-shaped cells did not appear to contain viral particles but, in some cells, it was possible to observe ultrastructural features of "vermicellar bodies" and tubuloreticular structures, as we have already described in mature growth-phase lesions.

## DISCUSSION

The ultrastructural study described here has allowed us to clarify some features of Kaposi's sarcoma.

One of the major purposes of this study was to determine whether electron-microscopy could reveal differences between the two forms of this neoplastic process.

*Figure 7: Spindle-shaped cells with elongated nuclei and poorly characterized cytoplasm can be seen within the dermis (Original magnification 7200x).*

Our findings do not indicate any qualitative difference between the classic lesion and those associated with AIDS.

However, the fact that certain features seemed to be more or less common in one form or another may be significant. The AIDS-related lesions seemed, in fact, to be associated with a more rapid and extensive destruction of endothelial structures of the capillaries. Capillary changes in lesions from patients with classical Kaposi's sarcoma evolved more gradually, and the degree of damage seen in the early AIDS-associated lesions was reached only in the more advanced lesions of this type (13, 14).

Another finding that seemed to differentiate the two types of lesions was the increased frequency with which tubuloreticular inclusions were observed in the lesions associated with AIDS, a feature that has already been noted by others (13, 36).

Various studies, in any case, consider the tubuloreticular structures just an indirect evidence of viral infection; in fact, it was possible to find this feature in cells affected by autoimmune diseases or after interferon-therapy (31, 32).

All of the AIDS specimens we examined contained these

*Figure 8: Spindle-shaped cells and erythrocytes within the dermis. Some of the cells appear whole while others are being phagocytized (Original magnification 7200x).*

structures as opposed to only two of those from the classic group, and in these latter cases, they were difficult to find.

We did not observe viral-like particles within the cells from AIDS-associated lesions, but we found "vermicellar bodies" in the cytoplasm of these cells. The morphology of these plexiform inclusions is better appreciated in relatively thick sections; in extremely thin sections, it appears as dense granules that may be confused with clumps of disintegrating nuclear and nucleolar material. The diameters of the vermicular rods are similar to those of viral cores.

These inclusions are described, by some authors, in nucleus or even in the cytoplasm of cells infected by respectevely DNA or RNA-virus and probably represent deranged or frustrated core-viral production (43, 44).

We did not find "vermicellar bodies" or viral particles in the classical form of Kaposi's sarcoma, whereas others (42) found viral particles in this form of Kaposi's sarcoma in Greece.

Another important objective of our study was that of clarifying the histogenetic origin of Kaposi's sarcoma. Our findings, together with those of the literature (33, 34, 37), suggest that the process originates in endothelial cells.

Whereas only a few of the spindle-shaped cells present in these lesions could be identified as endothelial cells on the basis of electron-microscopy findings, the results of recent immunohistochemical studies (38) revealed that the cells presented at least one of the characteristics of normal endothelial cells.

This study (38) demonstrated the presence of the CD34-antigens on several cell types, including dendritic cells of the dermis, perifollicular cells, and, more significantly, endothelial cells; in Kaposi's sarcoma both the proliferating endothelial cells and those that are spindle-shaped present the CD34-antigen.

This finding, together with those of Fink (39) and Nickoloff (40), argue for an endothelial rather than fibroblast derivation of these spindle-shaped cells. Certain properties, such as the capacity to form regular and well-defined vessels, are lost during the neoplastic evolution and cells acquire other features that are more characteristic of fibroblast. This interpretation, together with the study conducted by Nickoloff et al. (40), is further supported by the fact that the ultrastructural similarities between the endothelial and spindle-shaped cells were greater in cells lying close or adjacent to one another than in those separated by greater distances.

*Figure 9: Spindle-shaped cells and extravasated erythrocytes characterize an advanced AIDS-related lesion (Original magnification 4500x).*

*Figure 10: Fibroblast-like cells engaged in phagocytosis of extravasated erythrocytes (Original magnification 4500x).*

# REFERENCES

1) Cerimele D, Massarelli G. In: Rondanelli E G: "AIDS la sindrome da immunodeficienza acquisita". Piccin Nuova libreria 1987, 1979-201.

2) Smitch EC, Helmes B.G.T. Malignant disease in the natives of Nigeria. An analysis of 500 tumors. Ann Trop Med Parasitol 1934 2, 28:641.

3) Thijs A. L'angiosarcomatose de Kaposi au Congo Belga et Ruanda Burundi. Ann Soc Belg MedTrop 1957; 37: 295-307.

4) Centers for disease control. Update on acquired immune deficiency syndrome (AIDS) in United States. MMWR 1982; 31:507.

5) Ackerman B.A. 1985 Hystologic features of Kaposi's sarcoma and simulators of it. Kaposi's sarcoma D. Cerimele. Spectrum publication, inc.

6) Otto H.F. et al. Kaposi's sarcoma and AIDS. Light features including cytoskeleton. Laryng Rhin Otol 1985; 181: 88 (ABSTR.).

7) Murray J.L, Lothe F. The histopathology of KS. Acta Un. Int Cancer 1962; 18: 413-28.

8) Hashimoto K, Lever W.F. K. Sarcoma; histochemical and electron microscopic studies. J invest Dermatol 1964; 43: 539-49

9) Pepler W.J, Theron J.J. An electron microscope study of KS hemangiosarcoma. J pathol bacteriol 1962; 83: 521-5.
10) Dorfman R.F. the ultrastructure of KS. Lab. Invest 1964; 13: 939.

11) Waldo Ed, E Coll. The ultrastructure of vascular tumor; additional observations and a review of the literature. Pathol. Annu 1979; 12 (2): 279-305.

12) Tucker J.A. Malignancies in the AIDS. J. Electron. Microscop. Tech 1988; 8 (1): 137-58.

13) Konrad K, Schenk P. et al. Tubuloreticular structures in Kaposi's sarcoma; a comparison of the classical and AIDS-associated forms. Acta Derm. Vener. 1986; 66: 207-12.

14) Newland JR et al. Intraoral Kaposi's sarcoma a correlated light microscopic, ultrastructural, and immunohistochemical study. Oral. Surg. Oral. Med. Oral. Pathol. 1988;6 6: 48-58.

15) Schenk L, e Konrad K. ultrastructure of Kaposi's sarcoma in AIDS. Arch. Otorhin. 1985; 242: 305-13.

16) Schenk P. Ultrastructural morphology of KS in the head and neck region of patient with AIDS. Laryng. Rhin. Otol 1986; 65: 604-11.

17) Kostianowsky M, Kangy H, Grimley PM. Disseminated tuboreticular inclusions in acquired immunodeficiency sindrome (AIDS). Ultrastruct Pathol. 1983; 4: 331-6.

18) Leu HJ, Odermatt EB. Multicentric angiosarcoma. Virchows Arch. (Pathol. Anat.) 1985; 408: 29-41.

19) McNutt N. S, Van Fletcher, Conant M. A. Early lesions of Kaposi's sarcoma in homosexual men. An ultrastructural comparison with other vascular proliferations in skin". Am. J. Pathol. 1983; 111: 62-77.

20) Bendelac A, Kanitakis J. et al. Basement membrane in KS.; an immunohistochemical and ultrastructural study. Path. Res. Pract. 1985; 180: 626-32.

21) Kuntz AA, Gelderbrom HR et al. Ultrastructural findings in oral Kaposi's sarcoma (AIDS). J. Oral Pathol. 1987; 16: 372-9.

22) Ackerman AB. Subtle clues to diagnosis by electron microscopy; the patch stage of Kaposi's sarcoma". Am. J. Dermatopathol. 1979; 1: 165-72.

23) Schulze H.J. et al. Initial lesions of HIV related Kaposi's sarcoma - a histological, Immunohistochemical, and ultrastructural study". Arch. Dermatol. Res. 1987; 279: 499-503.

24) Massarelli G et al. Hyaline bodies in Kaposi's sarcoma: an immunocytochemical and ultrastructural study". Appl. Pathol 1989; 7: 26-33.

25) Pathobiology of cell membranes, II, 1980, edited by BF Trump / A.U. Arstilia. Pag. N. 429.

26) Weibel E.R. Neue cytoplasmatische Komponenten von Endotelzellen". Acta Anat. 1964; 59: 390.

27) Weibel ER, Palade GE. "New cytoplasmic components in arterial endothelia" J. Cell. Biol. 1964; 23:101-12.

28) Siegel A and Lüscher EF. Non identity of the α granules of human blood platelets with typical lysosomes". Nature 1967; 215:745-47.

29) Warhol M. J. The ultrastructural localization of Willebrand factor in endothelial cell". Am. J. Pathol. 1984 117: 310-15.

30) Schaff Z., Barry D.W. et al. Cytochemistry of tuboloreticular structures in lymphocites from patients with sistemic lupus erythematosus and in human lymphoid cells" Lab. Invest 1973; 29: 577-86.

31) Grimley P.M., Schaff Z. Significance of tubuloreticular structures in the pathobiology of human disease. Pathobiol. Annu 1976; 6: 221-57.

32) Grimley P.M. et al. TRS in patients with AIDS interferon-related effects in circulating t cells monocytes" in: Friedman-Kien AE, Laubenstein L. J.: "AIDS: The epidemic of Kaposi's sarcoma and opportunistic infections" New York, Masson publishers U.S.A. inc. 1984; 181-92.

33) Safai B. Kaposi's sarcoma; an overview of classical and epidemic forms. In: Broder S. Ed.: AIDS, modern concept and therapeutical challenges. Basel, Dekker 1987: 205.

34) Russel Jones R, Spaull J et al. Histogenesis of Kaposi's sarcoma in patients with and without acquired immunodeficiency syndrome (AIDS). J. Clin. Pathol. 1986: 39: 742-9.

35) Gyorkey F, Sinkovics H. G, Melnick J. C, Gyorkey P. Retroviruses in KS in AIDS. (Letter). N. Engl. Journal of Med 1984; 311: 1183-4.

36) Marquart K. H. Tubureticular structures in Kaposi's sarcoma cells are not an ultrastructural marker for AIDS. (Letter) Acta Derm Venereol 1987; 67: 367.

37) Nadji M. et al. KS immunohistologic evidence for an endothelial origin. Arch. Pathol. Lab. Med. 1981; 105: 274-5.

38) Nickoloff BJ. The human progenitor cell antigen (CD34) is localized on endothelial cells, dermal dendritic cells and perifollicular cells in formalin-fixed normal skin and on proliferating endothelial cells and stromal spindle-shaped cells in Kaposi's sarcoma. Arch Derm 1991; 127: 523-529.

39) Fink L. et al. Expression of the CD-34 gene in vascular endothelial cells. Blood 1990; 75: 2417-26.

AUTHORS' ADDRESSES

Dr. Leonardo Celleno, Dept. of Dermatology Catholic University of Sacred Heart
Largo A. Gemelli, 8 - 00168 Rome, Italy
A. Mastroianni M.D. same address
M. G. Borgia M.D. same address
D. Cerimele M.D. same address
F. Cottoni M.D. Dept. of Dermatology, University of Sassari, Sassari, Italy